STUDIES ON THE PATHOLOGICAL CHANGES IN EXPERIMENTAL COCCIDIOSIS IN SHEEP

Thesis

Submitted to the Faculty of Veterinary Science,

RAJENDRA AGRICULTURAL UNIVERSITY, BIHAR

in partial fulfilment of the requirements

for the degree of

MASTER OF SCIENCE (VETERINARY)

IN

PATHOLOGY

By

Sudhir Prasad Rama

B. V. Sc & A. H.

JUNIOR RESEARCH FELLOW (R.A.U.)

BIHAR VETERINARY COLLEGE

PATNA

1975

STUDIES ON THE PATHOLOGICAL CHANGES IN EXPERIMENTAL COCCIDIOSIS IN SHEEP

Thesis

Submitted to the Faculty of Veterinary Science,

RAJENDRA AGRICULTURAL UNIVERSITY, BIHAR

in partial fulfilment of the requirements

for the degree of

MASTER OF SCIENCE (VETERINARY)

IN

PATHOLOGY

By

Sudhir Prasad Rama

B. V. Sc. & A. H.

JUNIOR RESEARCH FELLOW (R.A.U.)

BIHAR VETERINARY COLLEGE

PATNA

1975

Dr. C.D.N.Singh,
M.Sc. Vet.(Gold medalist),
F.R.V.C.S.(Sweden),
Professor and Chairman,

Department of Pathology,
Bihar Veterinary College,
P A T N A

Dated the 6th June,1975.

This is to certify that the work embodied in this Thesis entitled "STUDIES ON THE PATHOLOGICAL CHANGES IN EXPERIMENTAL COCCIDIOSIS IN SHEEP" is the bonafide work of Sri S.P.Rama and was carried out under my guidance and supervision.

(C.D.N.SINGH)

CERTIFICATE

Certified that the research works incorporated in this Thesis have not been published in part or in full in any other journal.

S. P. Rama.

(S.P.Rama)

The author is extremely grateful to the Vice-Chancellor, Rajendra Agricultural University, Bihar, for the award of Junior Fellowship in the shape of financial aid during the course of the present study.

S.P. Rama.

(S.P.Rama)

ACKNOWLEDGMENT

The author wishes to express a sincere gratitude to Dr. C.D.N.Singh, B.V.Sc.& A.H.,M.Sc.Vet.(Gold medalist), F.R.V.C.S.(Sweden), Professor and Chairman, Department of Pathology, for his guidance, valuable suggestion,untiring help, active interest and losty inspiration during the present study and preparation of the Thesis.

The author is thankful to his minor advisor Dr.L.P. Singh,M.Sc.,Ph.D.,Professor and Head,Department of Anatomy, and Dr.Gaya Prasad,M.Sc.(Vet.),F.R.V.A.U.(Copenhagen,Denmark), Senior Research Officer,Anatomy(I.C.A.R.Project) for their valuable advices, unfailing help and encouragement.

The author is highly grateful to Dr.R.L.Kaushal, Advisor to Vice-Chancellor,Rajendra Agricultural University, Bihar for his valuable advice to carry out the present research project.

Author is deeply grateful to late Dr.R.C.P.Yadava, Ph.D.(Mich.,U.S.A.),ex-Principal, Dr. K.N.Tiwary, ex-Principal, and Dr. R.N.Singh,M.Sc.(A.H.),Dip.Anim.Sci.(Copenhagen,Denmark), Principal,Bihar Veterinary College,Patna for providing necessary facilities.

Sincere thanks are extended to Dr.Md.Murtuza,M.V.Sc.,

Lecturer in Biochemistry and Dr.T.Prasad,M.V.Sc.,P.G.,Dip.in-Biochem. & Physiol.(Copenhagen),Assistant Professor of Biochemistry for their help in biochemical estimation and laboratory facilities.

Author is extremely grateful to Dr.G.J.Jha,M.V.Sc., Ph.D.,Dr. P.N.Singh, M.Sc.(Vet.),Dr.B.K.Sinha,M.V.Sc., Dr.Lala Naresh Prasad, M.Sc.(Vet.), Dr.A.Ganguli,M.Sc.(Vet.),Dr.Ram Babu Singh,M.Sc.(A.H.) and Dr.M.N.Sahay,M.Sc.(Vet.),for their valuable help and cooperation.

Sincere thanks are also extended to Dr.R.J.Prasad, M.Sc.(A.H.),S.C.C.(Agri.and A.H. Stat.,I.C.A.R.,New Delhi), Assistant Professor of Genetics,Disease Investigation Control and Livestock Production Centre,Bihar,Patna,and Dr.Sant Kumar singh, M.V.Sc., for their help in statistical analysis.

My deep gratitude is due to my revered parents, loving brothers and wife for their blessing, goodwill and sacrifice for the success of the present project.

S.P. Rama.

(S.P.Rama)

DEDICATED

TO

MY

PARENTS

C O N T E N T S

		PAGE
INTRODUCTION	...	1
REVIEW OF LITERATURE	...	3
MATERIALS AND METHODS	...	14
R E S U L T S	...	25
DISCUSSION	...	37
S U M M A R Y	...	43
BIBLIOGRAPHY	...	45
		PLATE
PHOTOGRAPH	...	I - VII

INTRODUCTION

I N T R O D U C T I O N

India is an agricultural country with nearly 80 per cent of this population engaged in agricultural work for their livelihood. It has a very huge sheep population of 40.22 million (Livestock census,1959-60) but the production of wool and mutton from the local breed of sheep is very low. Production of wool and mutton from sheep rearing is the main source of income for the people in villages. Blanket and carpet making (a cottage industry) is carried on since early times in the Bhagalpur, Rohtash and Gaya. The present drive for "grow more food" is very much dependent on sound husbandry practices. These husbandry practices envisages maintenance of sheep free from bacterial, viral and many protozoal diseases. Amongst many sheep diseases prevalent in sheep, ovine coccidiosis is an important malady. Detailed studies of coccidiosis are available in different species of animals such as poultry and cattle but interest in study of pathological changes of coccidiosis in sheep has not heither to gathered and attension of some pathologists has been attracked towards study of pathology in sheep. There are 13 species of coccidia in sheep but <u>Eimeria arloingi</u> and <u>Eimeria parva</u> devoted

too much concern. Sheep usually 1-4 months are affected by coccidiosis but clinical signs are less prominent than in bovines.

The object of undertaking this research problem is to study in greater details the clinical, hematological, histopathological and histochemical changes in sheep affected with experimental coccidiosis in young sheep. Literature available on hematological and histochemical is very meagre. It was also felt essential to undertake this problem to find out the exact position as to symptoms and pathology of this disease in local breeds of sheep in two different age groups to facilitate correct diagnosis of disease for effective control.

To achieve this, experimental study have been taken with local isolate of coccidia obtained from carriers in sheep. Local strain of coccidia was selected to get a true pathological picture of disease as it occurs in Bihar and probably in India, so that the results obtained will be valuable in the diagnosis of this disease by pathologic procedure.

In this context I am being tempted to quote Smith and Jones (1970). According to these authors,even some of first of diseases recognised, Anthrax for example, could be restudied with profit in the light of modern knowledge and modern technique.

REVIEW OF LITERATURE

REVIEW OF LITERATURE

In sheep coccidiosis has been recognised from a very long time. Different species of coccidia vary in the extent of pathogenicity.

Machul'skii (1938) reported the incidence of Eimeria ninakohlyakimovae (86%), Eimeria arloingi (58.8%), Eimeria galouzoi (54.7%), Eimeria parva (41.9%), Eimeria faurei (27.9%) and Eimeria intricata (13.9%) in 86 sheep examined in different farms in South Ukraine. He also observed that six above mentioned species might be found in a single animal.

Hammond and Hamilton (1941) recorded the presence of coccidia in faeces of 67 sheep by the examination of sporulated oocysts.

Honess (1942) recorded two new species of coccidia viz. Eimeria ahsata and Eimeria crandallis in rocky mountain big horn sheep in Wyoming.

Rao and Hiregandar (1953-54) recorded the occurrence of Eimeria faurei, Eimeria arloingi, Eimeria ninakohlyakimovae, Eimeria intricata and Eimeria parva in sheep and goat in Bombay state from where Eimeria pallida, Eimeria granulosa and Eimeria crandallis has been reported earlier.

Shumard (1957) revealed a much higher incidence of the disease in lambs. He also observed much of morbidity attributed to ovine coccidiosis is caused by toxin which is a product of coccidia. He reported that lambs infected with Eimeria ninakohlyakimovae and Eimeria faurei exhibited lowered feed consumption, lassitude generalised incordination and slight scouring with some bleeding. He also studied the biochemical changes in lambs infected with Eimeria ninakohlyakimovae and Eimeria faurei and observed that the inorganic serum phosphorus level in lambs dropped moderately. He argued that this physiological changes in the host could be correlated with the growth and development of the endogenous phase in the life cycle of coccidia.

Shumard (1957) reported that 80 lambs were experimentally infected with a mixture of Eimeria ninakohlyakimovae and Eimeria arloingi and noticed loss in amount of feed consumed over 24 days period and compared with control lambs. With Eimeria parva inection necrotic areas may be found in the mucosa of caeca and colon. With Eimeria ninakohlyakimovae infection the intestinal mucosa was covered with petechial haemorrhages.

Becklund (1957) reported 10 per cent mortality in

lambs of 2 flocks infected with Eimeria arloingi and Eimeria ninakohlyakimovae. He also observed the sexual stages of Eimeria arloingi in the villi of two lambs.

Walker (1958) reported the outbreak of coccidiosis in lambs. He suggested that white globular structures in the intestinal mucosa of sheep infected with coccidia represent infection with Eimeria species. Its diagnosis was based on diarrhoea with tenesmus and exaggerated movements in the flanks and presence of white cyst like structures in the intestinal mucosa postmortem.

Levine et al.(1962) reported that most outbreaks of ovine coccidiosis were due to Eimeria ahsata.

Paichuk et al.(1962) reported the prepatent period for Eimeria faurei in goats was 16-23 days and the patent period 4-13 days. If re-infection was prevented, goats become free from coccidia after 21-31 days.

According to Rao et al.(1962) the erythrocyte count, haemoglobin content, hematocrit value, mean corpuscular volume and mean corpuscular haemoglobin content were estimated in the blood of 26 healthy sheep of Rajasthani breed.

Levine (1962) recorded three species of Eimeria found in the faeces of a kid with intestinal lesions of

coccidiosis. These were Eimeria arloingi, Eimeria crandallis and Eimeria christenseni. He also studied endogenous stages in the small intestines.

Davis et al.(1963) infected 14 lambs with sporulated oocysts which were killed between second and twenty three days later. Some sporozoites in host tissue were still in the spindle shaped forms at two and five days. Others were beginning to round up in the cytoplasm and nuclear division upto six nuclei were seen at four to six days. The parasites were numerous at ten days with the largest schizonts measuring fifty microns. At eleven and twelve days the largest schizonts measured without a coverslip, 95 x 155 microns, while fifty averaged 93.5 x 104.7 microns. At fifteen days largest one was 162.2 x 265 microns, fifty averaged 165.4 x 183.5 microns. Some schizonts were in the lacteals of villi but most of them were in the middle of mucosae, and two were found in the muscularis mucosae. Gametogenesis was first seen at twelve days. Macrogametocytes ranged between 35.1 and 45 microns while microgametocytes were about 26 x 36.5 microns. Gametes and oocysts were found mostly in columnar epithelial cells lining the intestinal gland instead of being in epithelial cells covering the villi. Endogenous stages were found

throughout the small intestine with the greatest numbers in the jejunum.

Shah (1963) recorded the occurrence of Eimeria ahsata (24%), Eimeria arloingi (53%), Eimeria crandallis(24%), Eimeria faurei (6%), Eimeria granulosa (4%), Eimeria intricata (7%), Eimeria ninakohlyakimovae (1%), Eimeria pallida (6%), Eimeria parva (5%), Eimeria punctata (2%) and Isospora species (2%) in sheep of united state.

Smith & Davis (1963) reported light infection with Eimeria ahsata in a lamb which was in four hour contact for 19 days with two experimentally infected lambs. One of these was excreting oocysts. It was considered that the lamb became infected by licking sporulated oocyst from the wool of the infected lamb and not by ingesting oocysts voided during contact as there was not sufficient time for sporulation.

Shah et al.(1963) recorded the occurrence of Eimeria arloingi (31.3%), Eimeria ninakohlyakimovae (12%), Eimeria crandallis (10.3%), Eimeria christenseni (4.7%), Eimeria faurei (1.3%), Eimeria parva (1.3%), Eimeria granulosa (1%), and Eimeria pallida (0.3%) in the faeces of 300 goat in Madhya Pradesh.

Lotze et al.(1964) observed coccidial schizonts in

the large mesenteric lymph nodes in sheep and goat which had been fed sporulated oocyst of Eimeria arloingi, Eimeria faurei, and Eimeria ninakohlyakimovae 13 to 18 days earlier. The coccidial schizonts measured 30 to 360 microns in lymph node of sheep. Accordingly the merozoites appearing to be approaching maturity were found in the larger schizonts in the lymph nodes.

Sivadas et al.(1965) opined that both sheep and goats were affected by the same species of coccidia and same type of pathologic alterations in tissue were exhibited. In their investigation of an outbreak of coccidiosis in kids they also reported that kids of 1-4 months age group of both Jamnapari and cross bred were affected. Except a few, all the affected kid showed dullness, loss of appetite, slight diarrhoea and unthriftiness. Twenty three per cent mortality was recorded, out of which cross bred animals (25.25%) suffered more than Jamnapari (14.44%). Death rate was higher (28.10%) in the second month of life. The macro and microscopic changes were hydropericardium, hydroperitoneum, diffuse oedema of abomasal wall, hyperaemia duodenum, greyish white elevated or poorly pedunculated growths or patches in the distal part of duodenum jejunum, and ileum. The intestinal tubular glands

showed hyperplastic and hypertrophic changes simulating papillary adenoma and necrosis of mucous membrane associated with leukocytic infiltration and slight fibroblastic reaction.

Sayim (1965) observed a kid discharging watery faeces and oocysts of Eimeria arloingi. It was killed and portion of its intestines were examined histologically. He found schizonts, macrogametes, microgametes and oocysts in epithelial cells of jejunum and ileum. Eimeria arloingi oocysts were found in the faeces of 77 per cent of 900 Angora goats.

Patyk (1965) reported out of 222 lambs aged 1-8 months coccidia were found in 190 lambs. He also found no lambs had diarrhoea, though these were 236-1000 oocysts per gramme of faeces.

Jha and Subramanian (1966) revealed the eleven species i.e. Eimeria ahsata, Eimeria arloingi, Eimeria christenseni, Eimeria crandallis, Eimeria faurei, Eimeria granulosa, Eimeria hawkinsi, Eimeria intricata, Eimeria ninakohlyakimovae, Eimeria pallida, and Eimeria parva in the goat of Uttar Pradesh.

Deorani (1966) revealed that sexual stages of Eimeria arloingi would be considerably pathogenic in young kid and will cause death of the host in heavy infection on account of severe

enteritis, superficial ulceration and haemorrhage. The papilla form elevation of the mucosa due to result of the focal hypertrophy due to large number of parasiting gametocytic stages and oocysts, highly prolifereted epithelial cells and connective tissue and large amount of infiltrated cells.

Singh et al.(1967) identified the developmental stage of Eimeria arloingi, Eimeria ninakohlyakimovae, and Eimeria parva. Possibly of Eimeria faurei also in the serial section of the small and large intestines of sheep naturally infected with coccidiosis.

Pandey et al.(1967) recorded Eimeria christenseni, Eimeria arloingi and Eimeria crandallis from two kids having the symptoms of paralysis. Histological examination revealed three distinct types of giant schizonts at different depth of the intestinal mucosa and globidial schizonts in the abomasum.

Gorbelik and Getmanets (1967) examined the faeces from 2205 sheep of five farms and observed coccidia in 1422; 88% of the young stock and 55% of the adult sheep were infected. They found Eimeria faurei, Eimeria ninakohlyakimovae and Eimeria intricata in sheep.

Bhatia and Pandey (1968) reported mature and developing Eimerian schizonts in the mesenteric lymph node of a four

month old kid. It was also concluded that involvement of the lymph nodes might be a common sequel of coccidial infection in the sheep and goat.

Svanbaev and Gorbunova (1968) infected the four lambs aged 2-4 months with 2.8 million oocysts of Eimeria ninakohlyakimovae each and another four were given 6 million oocysts. They observed coccidiosis was accompanied by a fall in alkaline reserve, chlorine content, glucose content, erythrocyte count and haemoglobin content of the blood.

Mugera (1968) observed circumscribed greyish white plaque throughout the small intestines but plaques were more numerous in duodenum in kenya goats. Microscopically a diffuse enteritis was seen in the small intestine. The epithelium of the tubular glands was hyperplastic and the epithelial cells were filled with mature and immature macrogametes,microgametes, merozoites, schizonts and developing oocysts.

Soltys (1970) recorded the incidence of Eimeria faurei, Eimeria arloingi, Eimeria parva, Eimeria intricata, Eimeria ninakohlyakimovae in the faeces of 41500 sheep examined from the various age groups in Poland. Coccidia were found in 591 (14%) animals.

Uhazy (1971) surveyed incidence of coccidiosis in Rocky Mountain big horn sheep in western Canada from the

winter of 1967 to the spring of 1969 and examined 510 fecal samples and found 90 % were positive for coccidiosis. Eimeria arloingi (56%), Eimeria parva (35%), Eimeria crandallis (34%), Eimeria ahsata (33%) and Eimeria granulosa (1%) were recorded.

Wacha et al. (1971) studied in deails experimentally infected lambs. Mature first generation schizonts were seen nine days after inoculation. They have an average diameter of 290 microns and were numerous 1.5-4.5 meter anterior to ileo-caecal valve.

Bali (1973) reported the occurrence of five species of coccidium Eimeria arloingi, Eimeria pallida, Eimeria parva, Eimeria faurei, Eimeria granulosa in sheep in the state of Bihar. The percentage of infection with coccidial parasites was 11.2 % at Takuna, 35 % at Gauriakarma and 77.71 % at Patliputra colony.

Pout (1974) infected lambs with pure culture of Eimeria arloingi "B" and Eimeria crandallis. The infection give rise to a tissue reaction in the upper and lower ileum respectively. A lesion similar to that of "Flat mucosa" was seen in areas of intestine which had a high density of parasites. A similar reaction, without any overt mucosal surface changes,

was produced in area of low parasite density. These two species of coccidia successfully colonized together the whole length of small intestine.

.....

MATERIALS AND METHODS

M A T E R I A L S AND M E T H O D S

Collection of infected materials:

An attempt was made to collect the oocysts from the natural source by the regular stool examination of sheep and lambs in neighbouring villages of Bihar Veterinary College, Patna. The faecal specimens of the lambs found on the outskirts of Patna High Court were examined and many of them were found to be positive for coccidia. *Eimeria parva* was isolated from one of the infected carriers whereas mixed sample of coccidia (*Eimeria parva* and *Eimeria ninakohlyakimovae*) could be obtained in others. The faeces was thoroughly mascerated in the normal saline in a sterile and clean mortar and pestle. The suspension was then filtered through sieves. The technique employed at Weybridge laboratory was adopted with slight modification. Saturated sugar solution was substituted for levitation of oocysts. The suspension containing the oocysts was centrifuged at 1500 rotation per minute, for one minute. The supernatent fluid was decanted and the sediment was examined for the presence of oocysts under the low power magnification. Saturated sugar solution was added to the sediment in the centrifuge

tube and shaken well. The tubes were again centrifuged for one minute at 1500 rotation per minute. The oocysts were thus freed from debris. A drop from the top of the centrifuge tube was examined under microscope and large number of oocysts present were counted and collected.

Sporulation of oocysts.-

About 1.5 cc from the top of the tubes, where oocysts were in maximum concentration was pipetted out. Sugar was freed by repeated washing with the distilled water and centrifugation. The oocysts were allowed to settle overnight in normal saline solution and centrifuged next morning. The supernatent fluid was decanted and the sediments were mixed with freshly prepared 2.5 % potassium dichromate solution. The oocysts were allowed to sporulate in wide petridishes at room temperature (varying between 25°C to 32°C with an average to 28.5°C). The culture media were aerated twice daily with the help of glass pipette. Few petridishes were left without stirring for comparing with the effect of the aforesaid oxygenation on sporulation. Distilled water was frequently added to compensate the loss through evaporation. The percentage of complete sporulation was determined after counting a minimum of 300 oocysts.

Sporulation time.

At room temperature the oocyst kept in 2.5% potassium dichromate solution sporulated in 3 to 4 days. For confirmation of coccidial species the fecal samples were sent to Indian Veterinary Research Institute, Izatnagar, U.P. and mixed infection with *Eimeria parva* and *Eimeria ninakohlyakimovae* was reported by that institute.

Counting of oocysts.

For counting of oocysts "Stoll egg counting technique" was adopted.

(i) 3 gm. of sample was taken.

(ii) A stoppered bottle was filled with water upto the mark 42 ml.

(iii) 3 gm. fecal sample was added in 42 ml. water contained in a stoppered bottle.

(iv) Then the stopper was fitted into the bottle and was shaken thoroughly.

(v) In order to separate the large particles of debris, the solution was filtered through a strainer.

(vi) After shaking the filtered fluid, 0.15 ml. was taken with the help of pipette and was put on a glass slide which was covered with cover slip.

(vii) 0.15 ml. of suspension was examined under microscope and all the oocysts were counted.

(viii) Total number of oocysts present in per gm.of samples was calculated.

Total number of oocysts present in 0.15 ml. of diluted sample was multiplied by 100 to obtain oocysts in one gm. of faeces.

Experimental group:

For the present study 20 sheep of non-descript type were selected randomly. Only clinically healthy sheep and lambs were used for the experimental work. These animals divided in two groups aged three months and six months respectively were kept in clean, dry, airy places. All sheep were given standard ration and water adlib. Four sheep of the same age, apparently healthy were kept as control for each of the group against the animal of infected group.

Grazing was not allowed throughout the course of experiment. Utensils for feeding and water supply were separate for healthy and diseased groups. The sheds were daily cleaned in morning with disinfectants. The attendants washed their hands and legs with disinfectant before entering and after leaving the sheds. The attendants were introduced to clean sheds occupied

by healthy sheep first and then they used to clean infected shed and feed the animals.

Stool examination for helminth and protozoal parasites and blood examination for the presence of any blood parasites were carried out. Deworming of all the experimental and control sheep were done. Temperature of all the animals was recorded in morning and evening. Those animals found free from any disease showing normal temperature were divided into two groups of 10 each and were kept under observation for about 10 days before infection.

In the present study, 20 male and female sheep were subjected to different hematological examination and biochemical tests for estimation of calcium, magnesium, inorganic phosphorus and different blood values during preinfection and postinfection period prior to slaughtering the animals. Temperature of infected and control sheep were also recorded daily in the morning and evening.

Establishment of infection:

The oocysts kept in potassium dichromate solution for experimental infection were washed by repeated centrifugation with distilled water for final concentration and resuspended

in a small quantity of distilled water about 10-12 ml. Oocysts were counted by Stoll egg counting technique. 4500 sporulated oocysts of Eimeria parva were fed per day for 3 days to sheep in group I. Sheep in group II were fed 4500 oocysts of Eimeria parva and Eimeria ninakohlyakimovae per os with help of a micro-pipette for 7 days. This was followed by plain water to make sure that all the oocysts were fed. Eight sheep were maintained as control.

Discharge of oocysts:

For determining the elimination of oocysts in both the groups I & II and control group, fecal samples were collected atrandom between 6 A.M. to 10 A.M. on the 12th day of infection for counting of oocysts. Stoll's egg counting method was adopted for making the count of oocysts of the filtrate. Oocysts per ml. were counted at first to determine the number of oocysts present in 0.15 ml. The total number of oocysts counted in 0.15 ml. of filtrate was multiplied by 100 to give the oocyst count per gm. of faeces.

Blood collection and examination:

The blood collection was done aseptically in the morning from the jugular vein directly. Two ml. of blood were

collected with a 19 gauge needle by 5 ml. all glass sterilized syringe. The blood was immediately transferred to a small vial containing 0.1 ml. of anticoagulant. Anticoagulant consisting of 0.8 gm. of Potassium oxalate and 1.2 gm. of Amonium oxalate per 100 ml. of distilled water was used (Heller and Paul,1934). 0.1 ml. of this mixture collected in small vial for 1 ml. of blood was evaporated to dryness in an oven at 60°C. The vials were shaken gently to mix the anticoagulant with that of blood in order to avoid clotting.

A few drops left in the syringe were put on two clean slides and an uniform smears were prepared for differential count. The blood collected in the anticoagulant vial was used for total Red blood corpuscle, White blood corpuscle, haemoglobin percentage, sedimentation rate and packed cell volume.

Total R.B.C. and W.B.C. count:

Physiologic saline was used as diluent for the red cell count. Blood was taken into clean R.B.C. diluting pipette upto 0.5 mark and the diluting fluid was sucked up to 101 mark. The dilution was thus 200 times. The count was made from the central and four corner big squares of the ruled area for R.B.C. count. The number was multiplied by 10,000 to give the number of cells per cu.m.m. of blood.

For leucocyte count Turk's fluid was used. Blood was taken upto 0.5 mark in the W.B.C. diluting pipette and the diluting fluid upto 11 mark, thus making the dilution 20 times. The cells in four big corner square (1 m.m. square) were counted and was multiplied by 50 which gave the number of cells per cu.m.m.

Haemoglobin estimation:

Haemoglobin percentage was obtained by Sahli Haden Haemoglobinometer following the direction enclosed for its use.

Erythrocyte sedimentation rate and packed cell volume:

Oxalated blood was loaded in the clean dry Wintrobe's tube with a uniform bore of 3 m.m. and a double 10 cm. scale caliberation with milimeter division. Blood was filled upto '0' mark of the tube and were allowed to stand vertically. Two readings were taken at the interval of one hour. The Wintrobe's tubes were then centrifuged at the speed of 3000 r.p.m. for 45 minutes and then for 15 minutes for adequate packing to determine the corpuscular volume. This was recorded as the number of ml. of cells per 100 ml. of blood.

Blood films for differential count:

Clean, dry and grease free polished slides were used. Uniform blood smears were prepared and stained by Leishman's stain. The "battlement system" were adopted.

Estimation of biochemical values:

The blood samples for analysis were drawn directly from jugular vein. The blood samples were collected in sterile test tube and were allowed to clott and left for a day for the separation of serum. The serum thus separated was kept in refrigerator till further analysis was done. The inorganic phosphorus was estimated in whole blood whereas rest of electrolytes were estimated in serum.

Determination of serum calcium.

Serum calcium was estimated by the method of Clark and Collip (1925) after the original method of Kramer and Tisdall (1921) as described by Oser (1965).

Determination of serum magnesium.

The method followed was Denis's modified method as described by Oser (1965).

Determination of inorganic phosphorus in blood.

Serum inorganic phosphorus was estimated by the method of Fiske and Subba Row (1925) as described by Oser (1965).

Incidence of coccidiosis:

To find out the incidence of coccidia in sheep in the state of Bihar, faeces of sheep of the Sheep Breeding Farm, Chatra and also reared by shepherds under field conditions were collected and examined for detecting oocysts of coccidia. For this purpose survey of incidence was carried out in the districts of Nalanda, Patna and Hazaribagh.

Histopathology and histochemistry:

Infected sheep were slaughtered 12th day after infection. Gross changes were noted in different organs of the sheep. Tissue pieces of 1 cu.cm. from representative lesions were collected and transferred in 10 % buffered neutral formaline solution for histopathological and histochemical studies. At the end of the experiment, the control sheep were slaughtered and gross changes were observed, if any. Pieces of tissue from different organs were collected for histopathology and different methods for staining were adopted (Culling,1969).

Sections of 5 to 7 microns thickness were cut with a rotary microtome and stained by the following methods.

(i) Haematoxylin and Eosin method for general study.

(ii) Weigert hematoxylin and Van Giesons stain for collagen fibers and smooth muscles.

(iii) Von Kossa's stain for calcium deposits.

(iv) Mucihaematein for the presence of mucin.

(v) Periodic acid schiff technique (PAS) for the presence of glycogen.

.....

R E S U L T S

R E S U L T S

The artificial coccidial infection was produced in two different age groups of sheep. The sheep in the first group were of three months of age. Ten sheep 4 to 6 months of age constituted the 2nd group. All the sheep in first group developed acute diarrhoea and died within a week. The sheep in 2nd group passed loose blood stained faecal material after 7th day of infection. All the sheep in 2nd group were destroyed in between 12 and 14 days after infection when symptoms were more severe. Naked eye lesions were those of enteritis in the affected sheep. Haematological studies of the sheep were carried out before and after infection and these findings are presented in table I. Three cases of naturally occurring coccidiosis were also sacrified and histopathology of all the different organs were carried out.

Autopsy of the sheep in the control group does not reveal any lesion in their body.

EXPERIMENTAL GROUP NO.I(ACUTE COCCIDIOSIS):

The lambs aged three months were fed 4500 oocysts of <u>Eimeria parva</u> (Fig.1) per day mixed with milk by milk bottle.

Symptoms

They became dull and depressed on second day after infection. The conjunctivae of eyes were pale. All of them passed loose and pasty faecal matter. The hairs around the anal region were soiled with pasty materials. The eyes were pale and some what shrunken. Twitching of the muscles were noticed in the lambs about two hours before death. The temperature in the infected lambs were subnormal (100°F). Coccidial oocysts were present in the faeces of the lambs dying on 4th to 6th day after infection (Table II). Most of the lambs died between 4th and 5th day after infection. Only one of them died on 7th day post infection.

Pathologic changes

Gross changes.- In general, intestinal mucosae of the infected lambs were moderately hyperaemic from pylorus to colon. Redness was severely present in the later part of ileum and caecum. In two lambs dying on 6th day after infection, serosal blood vessels of intestine were hyperaemic. There was presence of excessive mucoid material in caecum and colon. Few pin point petechiae were found in the small intestine. Blood tinged material was present in the caeca of the infected lambs.

Liver was slightly swollen and congested. Gall bladder was distended with bile. Spleen and kidneys were slightly hyperaemic. Muscles were dry and sticky to touch. Right ventricle of the heart was moderately dilated. In one lamb the ventricles were empty. Cardiac muscles were pale.

Microscopic changes.- Epithelial cells lining the crypts of Lieberkuhn were swollen and have narrowed the lumens of the crypts. The vessels in the lamina propria were hyperaemic (fig.2). Submucosal vessels were also engorged. The lamina epithelialis of intestinal mucosa was completely desquamated and villous architecture was distorted. There was cellular debris and detritus in the lumens of crypts. Few coccidia were noticed in the crypt cells of only one lamb died on 7th day after infection (fig.3).

Bacteriological examination.- No organism could be seen in the different organs of affected sheep.

EXPERIMENTAL GROUP NO.II (ACUTE COCCIDIAL INFECTION):

The sheep in the 2nd group were fed a mixture of *Eimeria parva* and *Eimeria ninakohlyakimovae* 4500 oocysts per day for a week.

Symptoms

Sheep were dull, depressed and had rough coat(fig.4).

Their temperatures varied from 101°F to 102°F. Anal region and hairs surrounding it were soiled with dry pasty mucous coated excreta mingled with a few drops of blood. Slight anorexia was marked in them from the 7th day after infection and it lasted for 4 to 5 days. All the sheep were destroyed on 12th day post infection. The maximum number of oocysts counted in the infected sheep was 43,600 oocysts/gm. of faeces (Table III).

Pathologic changes

Gross changes.- The intestinal mucosae of the infected sheep were moderately red and covered with very slightly blood tinged mucoid material. Redness was pronounced in the last one third of the ileum and caecum of the large intestine. Caeca contained pasty ingesta with excess of blood tinged mucoid material. Colon was also more hyperaemic. Mucosa of fore-stomach did not reveal any changes. There were several greyish white areas (half an inch diameter) scattered throughout the mucosa of jejunum and ileum. Oedematous changes, swelling and hyperaemia were more marked in the mucosa of colon. There were several petechiae and folds in mucosa of colon just next to the caeco-colic orifice. Mucosa of colon

was also thrown into folds. There were several areas of ecchymosis (half to one inch in diameter) irregularly distributed in the intestinal mucosa from pylorus to ileo-caecal orifice (fig.5). Liver was swollen and reddened. Blood was oozing on the cut surfaces of liver. Its edges were rounded. The gall bladder was severely distended with bile (fig.6). Spleen was slightly hyperaemic. Kidneys were swollen and moderately enlarged. The cortical surfaces were reddened. Meninges of brain were slightly hyperaemic in few cases. Apical lobes of the lungs presented greyish white raised areas above the level of surrounding tissues. Redness was more marked in the dependent parts of diaphragmatic lobes in one sheep. There was clotted blood in the ventricles of heart. Right ventricle was more dilated in the affected sheep. A small groove was found between right and left ventricles.

Microscopic changes.- There were several macrogametes in the crypts of Lieberkuhn (fig.7). There was moderate infiltration of inflammatory cells (mostly lymphocytes) in between the crypts. The crypts were widely separated by the infiltrating lymphoid aggregates. Lymphoid follicles were very much prominent and severely enlarged at places. Macrogametes were not found uniformly distributed throughout the crypt cells but they were

found to be localised at places more and more distal to pylorus. Macrogametes were frequently observed in the last one third of caeca and colic mucosa. In colon the epithelial cells lining the crypts were severely desquamated at places forming clump into the lumen. The epithelial cells lining the glands were swollen and presented slightly vacuolated appearance and have almost filled lumens. There were several goblet cells in the crypts and Brunner's gland. Lamina propria was severely infiltrated with lymphocytes. There was pink stained material in the submucosa between Brunner's gland and circular muscle layer. At places crypt contained pink stained material alongwith desquamated cells. Macrogametes were found in pink stained material mixed with cellular detritus in the intestinal lumen, (fig.8). There was macrogamete in submucosa just between the muscularis mucosae in only one sheep (fig.9). Macrogametes were also found between the fragmented end of muscularis mucosae. Most of the macrogametes were located in the crypts of lamina propria of caecal mucosae (fig.10). Gametocytes were seen at the margin of the necrotic areas (fig.11). Nuclei of epithelial cells of crypts were pyknosed at places. Excessive hyperplasia of goblet cell was more prominent in the lamina propria of caeca. There was excessive hyperplasia of epithelial cell of the caecal

mucosa to form papillary growths (fig.12). The blood vessels of submucosa of caecum were hyperaemic. In mucihaematein sections of sheep killed on 12th day post infection, there was very little mucin and also a few goblet cells in the crypts of the small intestine (fig.13). There was excessive infiltration of calcium salts in the crypt cell of infected sheep (fig.14). The sections of intestine were also stained by PAS method. There was mucin and goblet cells less than usual in the affected sheep destroyed on 12th day after post infection. In kidneys, the vessels in the interstitial were engorged with blood. There was pink stained material in the tubules. The vessels in the alveolar wall of the lungs were hyperaemic in few cases. Subepicardial vessels of heart were severely hyperaemic.

NATURALLY OCCURRING CASES OF COCCIDIOSIS:

Symptoms

Out of all the lambs procured in different lots for experimental work, 3 lambs developed acute coccidiosis and died latter on. The lambs developed subnormal temperature (99°F) before death. Anal region and the hair around the anus were soiled with dirty blood fecal matter. Lambs were lying on the ground with the

stretching limb. There were convulsions of the muscles of limbs and they finally died. There were several coccidia in fecal matter.

Pathologic changes

Gross changes.- The mucosa of small intestine was slightly reddened and covered with mucoid material. Caecal mucosa was also reddened. The intestine and abomasum were almost empty. The kidney and liver were swollen and slightly reddened. There was flow of blood on cut surfaces of liver. Ventricles of heart contained clotted blood (chicken fat clott). There were few greyish white raised areas above adjacent tissue in the apical lobes of the lungs. Lymph nodes were swollen and pale.

Microscopic changes.- In H & E sections of the last part of caeca, there were several macrogametes in the crypts. There was proliferation of lamina epithelialis to form papillary folds. Inflammatory cells were seen in the caecal mucosa.

HAEMATOLOGY:

Different blood values and estimation of serum calcium, serum magnesium and blood inorganic phosphorus were estimated in sheep of experimental group no.II before and after infection. Blood values were also obtained in 4 control sheep.

The estimated blood values are given in table I.

There was decrease in red cell count and haemoglobin percentage and increase of white cell count of infected sheep. In the infected group, there was no marked change in differential count and other values.

Estimation of serum calcium, serum magnesium and blood inorganic phosphorus were carried out. No significant alteration could be found in serum calcium, serum magnesium and blood inorganic phosphorus (Table I).

Incidence

Incidence of coccidiosis were found in 40 out of 120 sheep examined in Nalanda (28.56%). The results of the faecal examination of the sheep at different places to detect the presence of coccidial oocyst were given in table IV. The highest percentage of coccidial infection are found in sheep of Patna district.

Most of the sheep were carriers of mixed infection of *Eimeria parva* and *Eimeria ninakohlyakimovae*. But pure infection of *Eimeria parva* was found in only two cases.

The faecal samples obtained from the sheep from different sources were not of loose consistency and no clinical symptoms of coccidiosis were noticed in them.

.....

Table showing the results of hematological studies in the experimental group II.

	Experimental group (6)				Control group (4)
	Preinfection Mean ± S.E.	Postinfection Mean ± S.E.	Mean differences	Calculated 't' value	Mean ± S.E.
R.B.C. (Million c.mm.)	10.37 ± 0.31	4.08 ± 0.42	6.29	11.23**	9.39 ± 0.84
Hb. gm. %	11.35 ± 0.41	9.88 ± 0.19	1.47	3.26**	10.00 ± 0.35
E.S.R. mm./hr.	0.16 ± 0.02	1.08 ± 0.24	0.92	3.83**	0.15 ± 0.03
P.C.V. c.mm./ 100 cc.	26.58 ± 0.71	30.16 ± 0.47	3.58	4.21**	25.50 ± 0.64
W.B.C. (1000 c.mm.)	8.21 ± 0.34	10.89 ± 0.47	2.68	5.25**	10.11 ± 0.23
Neutrophil %	21.66 ± 0.67	25.16 ± 1.17	3.50	4.79**	30.5 ± 4.01
Lymphocyte %	72.66 ± 0.88	66.83 ± 1.30	5.83	3.69**	60.5 ± 3.79
Monocyte %	2.83 ± 0.54	2.33 ± 0.33	0.50	0.79NS	3.25 ± 25
Eosinophil %	2.83 ± 0.30	5.66 ± 1.33	2.83	1.88NS	5.75 ± 0.48
Basophil %	0	0	0	0	0
Calcium(mg.% of serum)*	12.26 ± 0.33	12.66 ± 0.65	0.40	0.57NS	-
Magnesium(mg.% of serum)*	2.31 ± 0.51	2.12 ± 0.56	0.19	0.12NS	
Phosphorus(mg.% of blood)*	4.41 ± 0.34	6.46 ± 0.33	2.05	1.02NS	

Figures in parenthesis indicate the number of animals used.
S.E. = Standard error., NS = Not significant.,
** = Highly significant.($P \leq 0.01$); * = only three animals used for these estimations.

Table II

Table showing the number of oocyst/gm. of faeces in the Ist experimental group between 4 to 7 days of observations.

Sheep no.	No.of oocyst fed daily for three days.	Production of oocyst/gm. faeces.	Day of observation in infected sheep.
1	4500	20,000	7th day
2	4500	19,800	6th day
3	4500	19,100	6th day
4	4500	Nil	5th day
5	4500	Nil	4th day
6	4500	Nil	4th day

Table III

Table showing the number of oocyst/gm. of faeces on 12th day postinfection in the experimental group II.

Sheep no.	No.of oocyst fed daily for seven days.	When first detected.	Oocyst/gm.of faeces on 12th day post-infection.
1	4500	7th day	43,600
2	4500	7th day	42,800
3	4500	7th day	43,525
4	4500	7th day	43,100
5	4500	7th day	42,625
6	4500	7th day	41,500

Table IV

Table showing the incidence of coccidial infection in the sheep.

Place	No. of sheep examined.	No. positive	Percentage positive.
Nalanda	120	40	28.56
Patna	185	90	48.64
Sheep breeding farm Chatra, Hazaribagh.	225	81	36.00

D I S C U S S I O N

D I S C U S S I O N

Coccidiosis does not occur in different species of animals to the same degree of severity or extent in production of lesions. Sheep and goat are known to be infected approximately by ten species of coccidia. All of the coccidia do not have similar pathogenicity. Eimeria arloingi and Eimeria faurei are are both infective in sheep and certain informations are available on the life cycle of these parasites. Pathogenesis of disease greatly depends on the animal affected and kind of parasites involved. In the present studies, a pure (Eimeria parva) as well as a mixed sample of coccidia(Eimeria parva and Eimeria ninakohlyakimovae)were obtained and used to produce infection in sheep in two different age groups for studying the pattern of development of pathologic changes in sheep.

The symptoms observed in infected sheep were dullness and depression. The animals had rough coat. Most of the animals were running subnormal temperature. Anorexia was present in sheep from 7th day after infection. Their anus and hairs around it were soiled with dry blood tinged fecal matter. Twitching of the muscle was noticed in latter part of infection. Infected animals excreted

soft slightly blood tinged faeces. Looseness of fecal matter was present in all infected sheep of both groups. Acute enteritis was present in the lambs of first experimental group. Thus coccidiosis appear in acute form in experimental animals. Rao and Hiregaudar (1954) considered coccidiosis to be very severe disease among sheep and goat in India. Shumard (1957) produced experimental coccidiosis in sheep by feeding the Eimeria ninakohlyakimovae and Eimeria arloingi and observed lost amount of feed consumed over 24 days period in affected group. This was also noticed in the infected sheep of both groups.

According to Jubb and Kennedy (1963), affected sheep are usually four months of age and loose yellowish blood stained faeces is noticed in them and anaemia can cause death in such cases. As described by the authors, the symptoms of diarrhoea or softening of faecal matter and anaemic changes in blood was noticed in the affected sheep on the 12th day post-infection. However, these observations were almost similar to those of Christensen and Foster (1943). Symptoms of acute enteritis were very much severe in the lambs of first group (3 months of age). Some of them died without showing oocysts in fecal matter. However, coccidia could be seen in the faeces of three sheep. Bacteriological examination of different organs of the lambs of the first infected group did not reveal

any significant result. However, it could not be possible to increminate any other factor attributable to death.

The main hematological changes in infected sheep were decrease in red blood cell count, increase in E.S.R. and reduction in haemoglobin percentage. There was rise in total white blood cell count but there was no remarkable change in differential count of white blood cell. The minimum count of red blood cell was noticed in the sheep number 3 (2.42 million/c.mm.). These findings are in agreement with those of Svanbaer and Gorbunova (1968).

There was no significant changes in the level of serum calcium, serum magnesium and blood inorganic phosphorus. However, a moderate fall in inorganic phosphorus has been reported in sheep by Shumard (1957).

Nocard (1893) noticed lesions in intestines of one group of six lambs which had shown symptoms of anorexia, weakness and diarrhoea. Polypi with slender pedicles were also noticed by him. Such growths were not noticed in present experimental group of infected animals. White spots were noticed in small intestinal mucosa and these observations are similar to those of Becklund (1957) and Davies et al.(1963). These white patches in intestinal wall were agglomerates of lymphoid cell which have heavily infiltrated in between crypt causing them to widely separated from each other. Coccidia could be noticed in the crypt cells. Irvine(1962)

described grey exudate in thickened intestinal wall and mucosa having corrugation and ridging in proximal intestine. In the present studies such lesions were more common in the last one third of ileum. Several macrogametes were observed in crypt cells. One of the important features of experimental coccidiosis utilising Eimeria parva and, Eimeria parva and Eimeria ninakohlyakimovae as source material was that the coccidia were not uniformally distributed throughout the whole intestine but were found to have definite localised growth pattern. Lesions had more severely developed in the caecum. Pout (1974) described tissue reaction in upper and lower ileum and the predilection site of Eimeria arloingi "B" might extended to 80 % of proximal intestine. He found the parasites to be more densely distributed in jejunum and the case of Eimeria crandallis predilection site was found in the lower ileum. In the present studies Eimeria parva and Eimeria ninakohlyakimovae were noticed to colonise the lower ileum and caecum as their predilection sites. Coccidia could not be found in sections of duodenum or proximal small intestine. The epithelial cells of the intestinal mucosa were found to be lost in the most cases, and distorted villus artitecture was seen. The parasitic stages observed in section of tissues were mostly macrogametes. Desquamation of crypt cells

and presence of cellular debris were noticed in the lumen of crypts. The observation as to presence of inflammatory cells in the lamina propria was in accord with those of Pout (1974). White spots or haemorrhagic areas were very irregularly distributed in gut and was similar to that of Pout (1974). However, in present studies, the lesions were most developed in the lower part of small intestine, caecum and colon.

Papilliomatous nodules were not noticed in intestinal mucosa in the infected animals in either of two groups. Such nodules were described by Hadleigh Marsh (1958). Slight to severe infiltration of lymphocytes was noticed in the lamina propria of the last part of ileum and caecum. It was remarkable to point out that wide separation of the crypts from each other due to heavy infiltration of lymphocytes in the intestinal mucosa has been described by Hadleigh Marsh (loc.cit.).

In the connection it is worth noting that predilection site of Eimeria parva and Eimeria ninakohlyakimovae of coccidiosis was observed to be last part of small intestine and caecum.

Sections of intestine in second experimental group were stained by PAS, von kossa's and Mucihaematein. There was moderate increase in deposition of calcium salts in the intestine of sheep of second group. Although there was no significant rise

in the level of blood calcium, deposition of calcium salt could be seen in the intestinal mucosa. Such deposition seems to be influenced by the degenerating and necrotic changes undergoing in the intestinal wall of the infected sheep. There was decrease in number of goblet cell in the section of intestine of sheep of second group. These changes were indicative of poor secretion of mucous in the small intestine and caecum in the latter part of infection.

Incidence of coccidiosis varied from 28.56 % to 48.64% in the different groups of sheep examined at various places. Although coccidial occysts were noticed in high percentage of cases, no clinical case of coccidiosis was noticed in them. It appears from the aforesaid observations that sheep get subjected to infection with more than one type of coccidia in nature. And even mixed or multiple infection fails to induce overt picture of the disease in the greater percentage of sheep population. This is also evident from detection of two kinds of coccidia in fecal samples of most of sheep examined in Patna, Nalanda and Hazaribagh (Bihar).

.....

S U M M A R Y

S U M M A R Y

Blood of ten sheep of local nondescript breed was examined during the pre- and post-infection periods. The sheep were artificially infected with a local strain of Eimeria parva and a mixture of Eimeria parva and Eimeria ninakohlyakimovae. Sheep were fed orally 4500 oocysts per day for three days in the first group and seven days in the second group with the help of micropipette. During the course of disease, the animals became dull and dipressed since 3rd day of infection and there was a fall in total red cell count and haemoglobin value in all of the affected sheep. There were no significant changes in other blood values. There was no rise in blood calcium, magnesium and inorganic phosphorus.

Symptoms, lesions, duration of disease, gross and histopathologic changes in the tissues noticed in acute cases of coccidiosis have been fully described and discussed.

In the abdominal viscera, Eimeria parva and Eimeria ninakohlyakimovae showed clear affinity for the last part of the small intestine and caecum. Areas of haemorrhages were noticed irregularly distributed in small intestine. Eimeria parva colonised only last part of ileum. The predilection

site of coccidia was the last part of ileum and caecum in the second experimental group of sheep infected with a mixture of Eimeria parva and Eimeria ninakohlyakimovae. There was moderate deposition of calcium salts in the intestinal wall of the sheep infected with coccidiosis. The number of goblet cells had considerably decreased on 12th day post infection.

.....

B I B L I O G R A P H Y

B I B L I O G R A P H Y

Bali, H.S. (1973) J.Res.Punjab Agric. Univ., 9 (1 suppl.) 206-213.

Becklund,W.W. (1957) N.Amer.Vet., 38: 262-264.

Bhatia,B.B. and Pandey,B.P. (1968) Indian J.Microbiol.,7 (1967):161-164.

Christensen,J.F. and Foster,A.O. (1943) Vet.Med., 38: 144.

Culling C.F.A. (1969) Hand book of histopathological techniques. 2nd.ed. London Butter Work.

Davies,S.F.M., Joyner,L.P.and Kendall,S.B. (1963) Coccidiosis. Edinburgh,Oliver & Boyd.

Davis, L.R., Bowman,G.W.and Smith,W.N. (1963) J. Prot., 10: (3 suppl.), 18.

Deorani,Sharma, V.P. (1966) I.V.J., 43: 122-127.

Gorbelik,R.V. and Getmanets,O.D. (1967) Veterinariya Kiev.,11: 113-116.

Hammond,D.M. and Hamilton,G.A. (1941) Proc.Utah. Acad.Sci.,18: 69-71.

Heller,V.G. and Paul,H. (1934) J.Lab.& Clin.Med.,19: 177.

Honess, R.F. (1942) Bull.Wyo.agric.Exp.Sta., 249, 28.

Irvine,J.H. (1962) Vet.Insp. N.S.W.,26: 61.

Jha, D. and Subramanian,G. (1966) I.V.J., 43: 588-591.

Jubb, K.V.F. and Kennedy,P.C. (1970) Pathology of domestic animals,3rd.ed. Iowa State University Press Ame,Iowa, 1970.

Levine,N.D.,Ivens,V., Smith,W.N. and Davis,L.R. (1962) Proc.helm.Soc.Wash.,29:87-90.

Machul'sksii,S.N. (1938) Rev.Microbiol.,Saratov.,17: 183-200.

Marsh,Hadleigh (1958) Newsom's sheep diseases,2nd.ed. The Williams & Wilkins Company.

Mugera,G.M. (1968) Bull.Epizoot.Dis.Afr.,16:101-106.

Nocard,E. (1893) J.Path.Bact.,1: 404.

Oser, B.L. (1965) Hawk's Physiological Chemistry, 14th ed.,Tata McGraw-Hill Publishing Co. Ltd.,Bombay.

Paichuk,N.G., Tsygankov, A.A. and Zavadskaya,L.G. (1942) Trudy Inst.Zool.Akad.Nauk. Kazakh. SSR., 16: 208-210.

Pandey,B.P., Bhatia,B.B., Chauhan,P.P.S. and Kala,P. (1967) I.J.V. Sci., 37: 58-65.

Patyk (1965) Zootechnika, Wroclaw, 13: 17-36.

Pout,D.D. (1974) Br.Vet.J., 130: 45.

Rao,G.R.,Narasimhalu, P.R., Reddy,V.K. and Hussain,M.A. (1962) I.V.J., 39: 429-433.

Rao,S.R. and Hiregaudar, L.S. (1954) Bombay Vet.College Magazine, 4: 29-33.

Richardson,U.F. and Kendall,S.B. (1963) Veterinary Protozoology, 3rd.ed., Oliver and Boyd Ltd.,Edinburgh.

Sayim,F. (1965) Vet.Fak.Derg.Ankara.Univ.,12: 208-218.

Schalm,O.W. (1971) Veterinary Hematology,2nd.ed., Lea & Febiger. Philadelphia.

Shah,H.L. (1963) J.Parasit.,49: 799-807.

Shah,H.L. and Joshi,S.C. (1963) J.Vet.Rec.,Mhow., 7: 9-20.

Shumard,R.F. (1957) J.Parasit.,43: 548-554.

Singh,N. and Pandey,B.P. (1967) Anuls.Parasit.hum.Comp., 42: 291-301.

Sivadas,C.G., Rajan,A.and Nair,M.K. (1965) I.V.J.,42: 474-479.

Smith,H.A. and Jones,T.C. (1970) Veterinary Pathology,3rd.ed., Lea & Febiger,Philadelphia.

Smith,W.N.and Davis,L.R. (1963) J.Parasit.,49: 59.

Soltys,A. (1970) Wiad.Parazyt.,16: 183-186.

Svanbaev, S.K. and Gorbunova,Z.I. (1968) Izv.Akad. Naukkazakh.SSR.Ser. biol., 6: 51-57.

Uhazy, Leslies.,Jeromel Mahrt and Johnc,Holmes (1971) CAN J.Zool.,49(11): 1461-1464.

Wacha,R.S.,Hammond,D.M., Miner,M.L. (1971) Proceeding of Helminthological Society of Washington.,38 : 167-180.

Walker, D.J. (1958) Vet.Insp., N.S.W., 27-31.
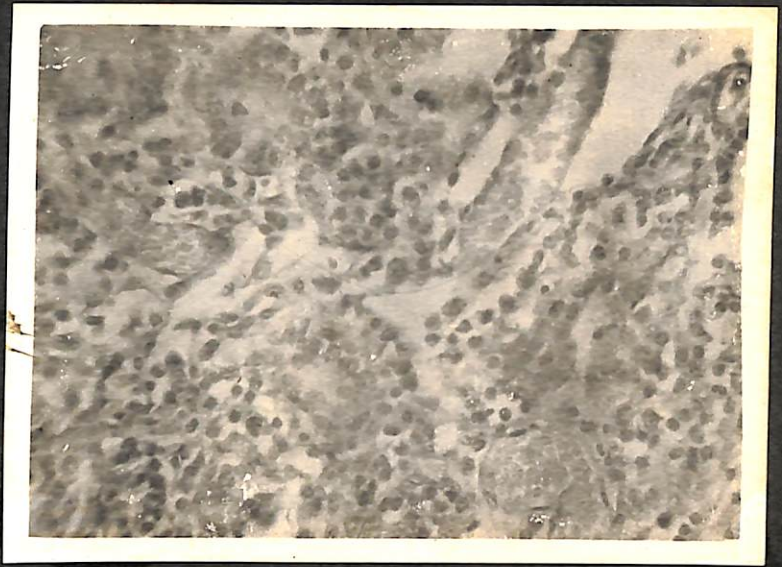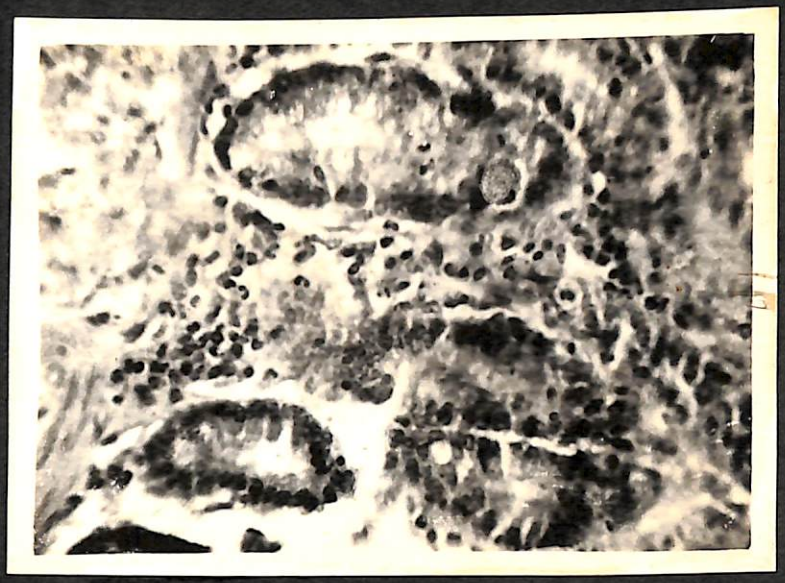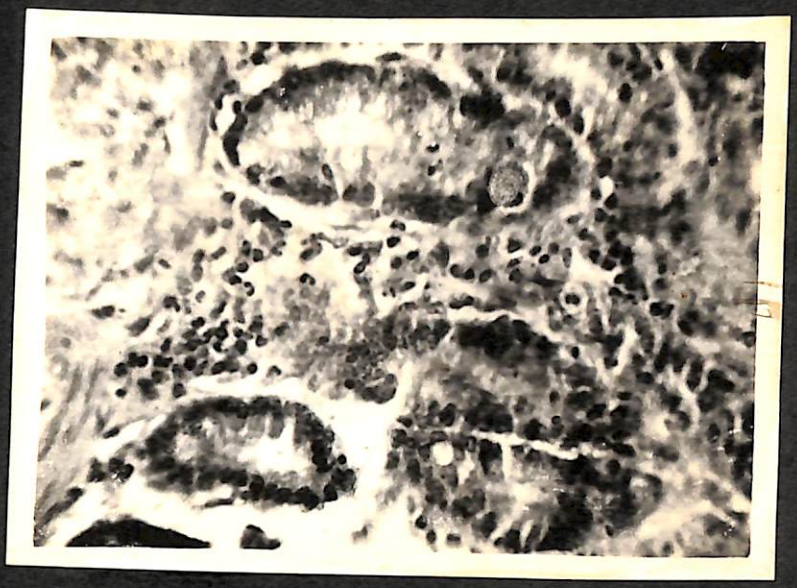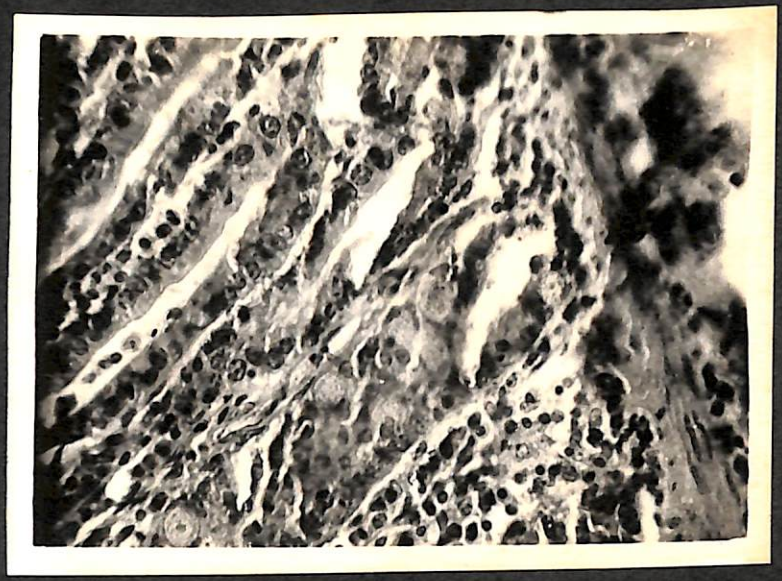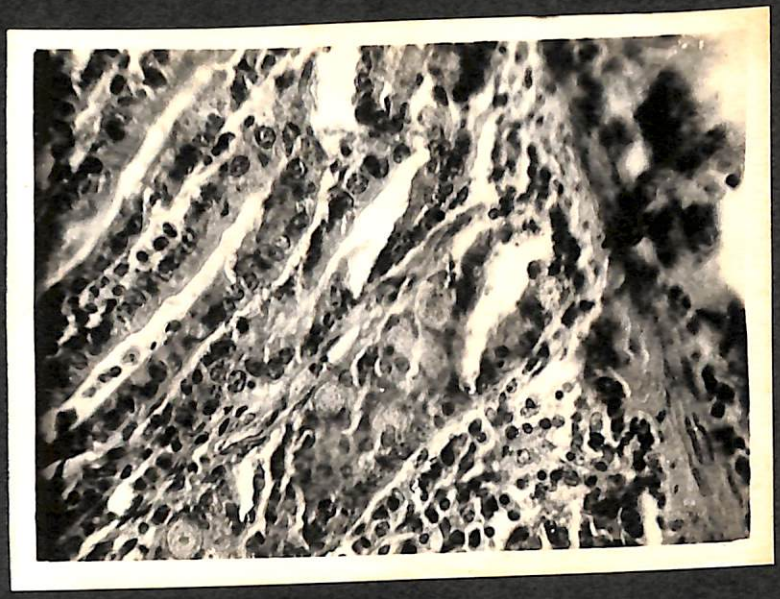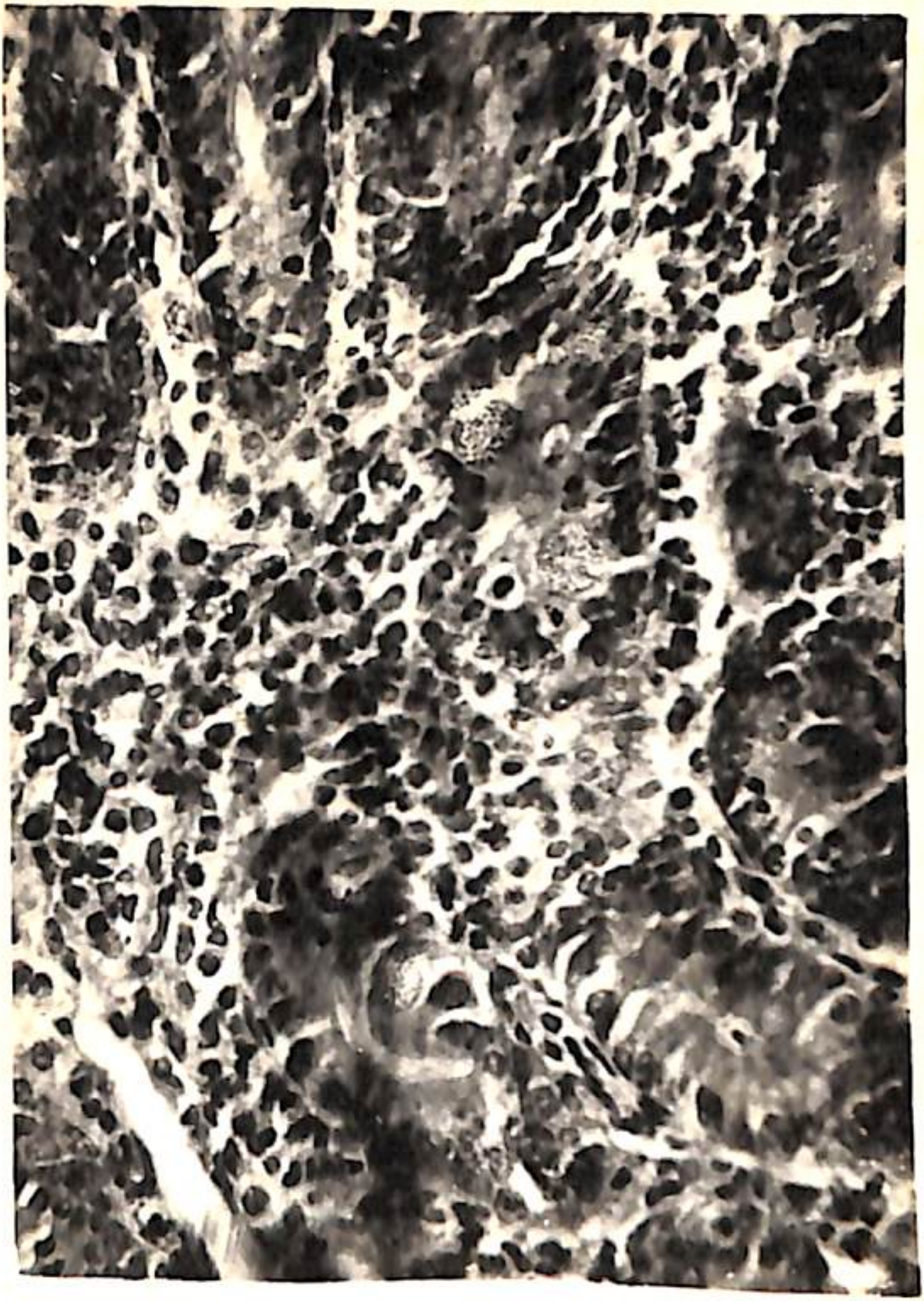
****
*****
***
*