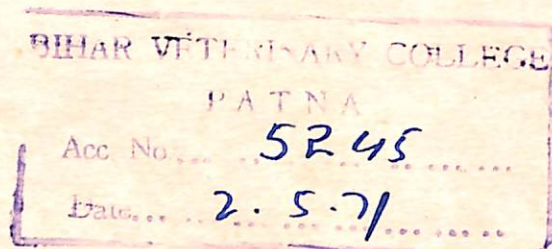


AN EXPERIMENTAL STUDY OF
TENDON REPAIR EMPLOYING DIFFERENT SUTURING
TECHNIQUES IN BUFFALO-CALVES AND ITS
APPLICATION UNDER FIELD CONDITION

O. P. GUPTA,
B. V. Sc. & A. H.



THESIS
SUBMITTED TO THE
MAGADH UNIVERSITY
IN PARTIAL FULFILMENT OF THE REQUIREMENTS
FOR THE DEGREE OF
MASTER OF SCIENCE (VETERINARY)
1970
POST-GRADUATE DEPTT. OF SURGERY
BIHAR VETERINARY COLLEGE, PATNA

FOREWORD

This is to certify that this Thesis entitled
" AN EXPERIMENTAL STUDY OF TENDON REPAIR EMPLOYING
DIFFERENT SUTURING TECHNIQUES IN BUFFALO- CALVES AND
ITS APPLICATION UNDER FIELD CONDITION " has been
Prepared under my guidance by Sri O.P.Gupta, a
Conditate for the Degree of M.Sc. (Vet.) in Surgery ,
and that it incorporates the results of his independent
study.

S.A. Ahmed 23/1/71
(S.A. Ahmed) ,

Postgraduate Professor of Surgery,

Bihar Veterinary College ,

And

Joint Director,

Animal Husbandry Department, Bihar,

PATNA

A C K N O W L E D G M E N T S

I express deepest gratitude to my revered teacher Dr. S.A.Ahmed , B.Sc. (Ag), M.R.C.V.S.,P.G. (Denmark), Postgraduate Professor of Surgery, Bihar Veterinary College, and Joint Director , Department of Animal Husbandry, Bihar, Patna , for invaluable suggestions and guidance, throughout the course of study.

I sincerely thank Col. S.M.Ishaque , Principal Bihar Veterinary College, Patna ,for providing the facilities for the study.

Warmest thanks are due to Dr. A.A.Khan , Assistant Professor of Surgery for invaluable help.

Thanks are also due to the members of the staff of the Surgery Department for their Co-Operation.w

Special gratitudes go to my parents under whose kind shelter I could carry out my study smoothly.

(O.P. GUPTA)

C O N T E N T S

<u>Chapter</u>	<u>Page</u>
I Introduction	1 - 8 .
II Anatomy of Superficial flexor tendon9 -12 .
III Review of Literature13 -32 .
IV Materials and Methods	33 - 44 .
V Observations and Results45 - 62 .
VI Discussion63 - 69.
VII Summary	70 -74 .
VIII References	(1) - (ix)

Number of Tables 8 .

Number of Graphs 2 .

Number of Figures 5 .

Number of Photographs . . . 21 .

.....

INTRODUCTION

I N T R O D U C T I O N

The problem " Tendon repair by Suturing " though taken on the experimental study in the buffalo - calves,; it does cover the whole of the bovines by virtue of its similarity in anatomical position . Such an study is of considerable importance and has direct bearing on the economy of the farmers. Practically the entire agriculture operation rests on the motive power produced by the bullocks and consequently in its draught capacity . One of the common injuries the bullocks sustain during ploughing is direct injury of the tendon . The injury may be from simple laceration to even rupture of the tendon which may completely disable the bullocks thus resulting in disruption of the agricultural operation.

According to Pulvertaft (1965) , Mayer in the year 1938 said ; Reconstruction of severed tendons constitutes one of the most delicate problems in Surgery, a challenge to ingenuity and dexterity of the operator ."

These remarks one must keep in view when ever tendon repair is to be performed . It is not at all difficult to suture a tendon and obtain sound union but it is not so easy to ensure repaired tendon to glide freely. The adhesion which bind an injured tendon to the surrounding tissue arise

from the sheath and paratenon and from the epitenon. Lindsay and Thomson in 1960 showed that the mere passage and withdrawal of a needle through a tendon is sufficient to cause local adhesions .

According to Padgett and stephenson, Pare in the 16th century was first to speak of tendon suture but it was not until Haller, in the middle of the 18th Century , demonstrated that tendons were insensible in contradistinction to nerves, that operative procedures began to be accepted. This process of tendon repair is said to have been studied first by John-Hunter in 1767. The studies of Enderlen (1893) on the tendo-achilles of the guinea -pig emphasized the importance of the tendon cells themselves in the repair of tendon.

Repair of Superficial digital flexor poses a major surgical problem . According to Hickman(1964) , the superficial digital flexor ruptures, either just below the knee or just above the fetlock. The immediate cause of rupture is some sudden and violent hyper extension of the fetlock joint exceeding the limit and resistance of the digital flexor tendons and suspensory ligament. Other condition involving these tendons which are amenable to surgical repair, include abnormally long tendons and contracted tendons..

Butler (1965) described that general anaesthesia is indicated in canine during tendon surgery as it eliminates

movement by the animal and thereby prevents excessive trauma to the tissues during the surgical procedures. Experience has shown that adequate hemostasis can be achieved only by application of tourniquet. Sponging must be minimal as this traumatizes and irritates the tendons and surrounding tissues. Before placing the tourniquet on the leg, the leg should be wrapped from the toes proximally with an elastic bandage. This will reduce the venous blood in the lower (distal) portion of the limb. The tourniquet may then be placed to block the arterial blood supply, the elastic bandage removed and then leg swabbed with an antiseptic solution. This will render a relatively bloodless field in which to work.

Incision should be longitudinal as this reduces the occurrence of binding scars. The incision should be made in the side of the tendon as far as possible, rather than directly.

Similarly Sealy (1946), in case of hand surgery emphasized observance of following precautions :- Never increase the incision along the course of the tendon, and never cross a flexion crease. Disregarding of the above precautions may result in the spread of infection along a tendon-sheath, or formation of a painful scar over the pressure bearing area, or loss of function due to adhesion of the tendon to the scar.

The gliding mechanism is an essential part of

the tendon complex and every precaution must be taken to avoid damage to it . To accomplish this, there should be minimal trauma to the tendon and adjacent structures . The surgical procedure should so planned as to ensure that the tendon is exposed to air for the minimum possible time. During exposure it should be moistened frequently with warm saline solution. Rigid asepsis must be maintained at all times, as infection and suppuration will invariably result in fibrosis and adhesions.

According to sealy (1946) , intelligent management of injuries to tendons require sound knowledge of the anatomy, Physiology and healing properties of these structures. The surgical management of injured tendon is always towards the anatomical restoration of the tendon, Preservation of the gliding function and repair of accompanying injured structures, such as nerve and bony parts . To attain this, the following steps are required to be taken :-

(1) Careful Examination of injury :- Special attention should be paid to any possible loss of Sub- cutaneous tissue and skin or injury to nerves , bones or joints.

(2) Surgical Technique :- The repair at tendons is a major Surgical Procedures and should be done in the operating room under rigid aseptic technic. Careful atraumatic handling of tissue is essential .

(3) Intelligent Post -Operative Care:- This should be supervised by the Surgeon who performs the repair . The rate of healing of tendons will depend the duration and the amount of motion to be permissible.

Suturing of divided tendon without loss of time has definite advantage by restoring functional ability of the effected limb over delayed or deferred suture of divided tendon which is very often brought it dangerous infection and consequent loss of function. According to sealy (1946) , outcome of Primary or Secondary repair is influenced by one or more of the five following factors.

(1) Nature of wound :- A cleanly incised wound is less likely to become infected than one which is contused and irregular.

(2) Contamination of wound :- The greater the contamination of wound with foreign materials, organisms , the more the chances of wound becoming infected.

(3) Time interval :- Subject to the condition enumerated under (1) & (2) the longer the interval between the injury and the repair the greater the possibility of developing infection.

(4) Location of the Tendon :- The flexor tendon of the hand enclosed in sheath should be sutured within 4 hours

after the injury and when injury is over the proximal phalanx it should be sutured up to 6 hours after injury.

(5) Facilities necessary for Treatment :- A well equipped operating room is necessary for the proper care of tendon injuries when this is not available treatment should be limited to the care of the superficial wound, and the tendon suture should be deferred to a later date.

One of the Pre-requisite for a successful tendon suturing is to ensure that tendon suture should approximate the cut ends of the tendon as accurately as possible and by means of sufficiently strong material which can hold the tendon ends in apposition until healing takes place. The suture material be non-irritating, of high tensile strength, and of small diameter. Braided silk or cotton can easily meet the above requirements. The disadvantage of catgut is that it causes marked tissue reaction around the tendon, thereby delaying healing favouring the formation of adhesions and increasing the chances of infection.

Workers including Sealy, Butler and O'Connor are of opinion that the ideal suture should have firm anchorage, its pattern should be simple and contain a minimum of suture material, the apposed ends of the tendon should be free of suture should be free of suture material. The suture material should not cause tissue reaction and the suture pattern should not cause strangulation of the tissues.

According to sterning Bunnell, as cited by Padgett and stephenson (1948) stainless Steel wire was the least irritatingsuture . Steel with 18 % chromium , 8% nickel and enough molybdenum making an even mixture can be readily made into wire. He placed the stainless steel wire so that it could be removed, by a Pullout wire under the proximal loop after 3 weeks. This pull-out wire was brough and through the skin and tied over the button. He pointed out that active movement of a tendon during the first two or three weeks retarded healing and provoked fibrosis. For small tendons he used wire No.34 and for larger tendons No. 28 or No. 35 .

Furthermore, various workers including sealy, Butler, Padgett & stephenson, Dinsmore, and Hickman have evaluated the different techniques of tendon suturing.

✓ Following repair the part should be immobilized. The plaster of Paris cast is the most satisfactory material for immobilization and fixes the parts well and avoids tension on the suture line. According to Mason and Allen , as cited by sealy (1946) suggested the following routine :-

- (1) Immobilization for 14 days .
- (2) Restricted active motion under supervision from the 14th to 21st Post-Operative days,
- (3) Gradual increase in motion after% the 21st Post operative day.

Tendon healing forms an important part for the success of operation . According to Flynn (1965) there are too main schools of thought holding different concept in regards to the tendon healing.:-

(1) One view is that new tendon arises mainly from the sheaths that surround the tendon stumps, and that the tendon tissue plays no significant role.

(2) Another school holds that regeneration is affected by proliferation from the cut ends, of the tendon. ~~This~~
~~is~~

Considering the importance of tendon Surgery and its application in bovines, in which very limited work has so far been recorded, was taken up for study. The techniques of tendon suture with different suturing materials and their histo -pathology formed the basis in the present plan .

In bovines, Buffalo -calves which could be easily available were selected for ~~the~~ study.

ANATOMY
OF
SUPERFICIAL FLEXOR TENDON

ANATOMY OF THE SUPERFICIAL DIGITAL FLEXOR TENDON .

GENERAL :- The tendon is a specialised fibro-Collagenous structure, lies between the two heads of the gastrocnemius . It originates from the bottom of the supra-condylar fossa of the femur and is inserted by three slips to the two tubercles and the triangular roughened depression between them, on the posterior aspect of the proximal extremity of the Second phalanx. Its tendon of origin is round and is succeeded by a fleshy belly, which descends on the posterior face of the femore - tibial articulation, and then between the two portions of the gastrocnemius, being intimately attached to its lateral portion. Its tendon of origin is blended with the insertion of adductor . The muscular belly is succeeded by a long tendon which is at first placed in front of the gastrocnemius , but at the lower third of the leg it winds round the tendon of that muscle, lies on its medial face for a short distance and thereafter on its posterior face. It then reaches the summit of the fibular tarsal, widens out forming a sort of fibrous cap over it, and detaches a fibrous band on either side. The tendon passes the grooved area on the summit of the tuber-calcis and is provided in front with a synovial bursae. It then runs down the metatarsal region placing itself behind the tendon of the deep digital flexor. The tendon divides into two branches a little above proximal sesamoids. Each branch receives a slip from the posterior division of the suspensory ligament and forms , behind the metatarso-phalangeal articulation,

a ring for the passage of the corresponding branch of the tendon of the deep digital flexor. The branches then pass down under the two annular ligaments of the digit, and each is inserted by three slips to the tubercles and the triangular roughened depression between them on the posterior aspect of the proximal extremity of the second phalanx.

STRUCTURE :-

As already stated, the tendon is a specialized fibro-collagenous structure that transmits force from a muscle to a movable part. This thick fibrous tissue is arranged in bundles parallel to the line of force of the muscle. Between these bundles are fibrous tissue septa containing blood and lymph vessels. Immediately around the group of tendon bundle is another dense layer of tissue known as Epitenon. In order to fully fill the sliding pathways in regard to proper tendon function, these structures consist of the paratenon and tendon sheath. Paratenon is made up of specialized loose fatty tissue surrounding the tendon and tendon itself. Fascia forms the outer layer of the tendon-sheath. Tendon sheath possesses continuous parietal and visceral layers, analogous to the mesentery, the two being joined by a connective portion termed 'Mesotendon,' It is at this point that the blood-vessels and nerves enter between the sheath and the tendon. In some cases mesotendon may disappear leaving only a strand of tissue the so-called Vincula-tendon-. The mesotendon is never situated

situated on the pressure side of the sheath, but on either the superficial surface or on one of the edges of the tendon. Two adjacent tendons may be surrounded by the same sheath, and in this case the adjacent portions of the two visceral layers are connected by strands of the mesotendon.

RELATIONS :- The superficial digital flexor related :-

(1) Anteriorly :- The posterior (capsular) ligament of the femore -tibial articulation, Popliteal and tibial vessels, Popliteus and deep digital flexor.

(2) Posteriorly :- The gastrocnemius.

(3) Postero-internally :- The skin and fascia .

BLOOD SUPPLY :- Popliteal and Posterior tibial arteries.

Sealy (1946) described that the blood -supply of a tendon enters through three portals :-

(1) From the muscle, (2) From the periosteum at the insertion , and (3) from specialized structures associated with the tendon, the paratenon and the mesotenon. The mesotenon found in tendons with sheaths, is a mesentery like structures which enters the tendon on its under surface and is sufficiently redundant to allow for motion. In the flex tendons of the fingers, the mesotenon is present only as small insertion. After the blood and lymph ~~xxxx~~ vessels enter the tendon they course through the fibrous tissue septa between the

tendon bundles.

Smith (1965) observed the following conclusions for the circulation in the tendon :-

- (1) The blood supply to tendon is through a mesotenon which contains a segmental pattern of arcades. In this regard, it is similar to the small intestine. An anastomotic variation is found where there is a flexor tendon sheath ; the mesotenon is consolidated into vincula.
- (2) The blood -supply to tendon is not significantly increased through its attachments to muscle or bone. Actually, the relative size of the blood -Vessels and their concentration in any one segment of tendon is not significantly greater than in any other.
- (3) These arcades have some ability the support the adjacent circulation within a tendon through collateral channel. However, they will not maintain it over more than comparatively short distances. Studies suggest that this range might be from 1 to 2 cm.
- (4) These studies suggest that large portions of any tendon freed at ~~thkond~~ surgery must function as a free -tendon graft until a blood supply is restored by the ingrowth of vessels.

NERVE - SUPPLY :- Internal Popliteal nerve.

REVIEW
OF
LITERATURE

REVIEW OF LITERATURE .

The researches and experiences made in the human surgery in the field of tendon repair and its different suturing techniques, have all along remained the basis of the research undertaken here .

DACOSTA (1908) reported the procedure of tendon suture. The instruments employed in this operation consist of Esmarch apparatus ; curved needles and needle holder ; chromicized gut, Kangaroo tendon or silk was used for an ordinary case and Silver wire for a supporting wound. Firstly the site was made aseptic in order to render the operation practically blood-less, a rubber bandage was applied centrifugally on the proximal side forcing the proximal end of the tendon into view . The cut end was approximated and sutured with a continuous suture or with tendon suture of Le-fort ; Le Dentu or Le-lejars . Esmarch apparatus was then removed and the wound was closed and dressed antiseptically. Finally splint bandage was applied.

Williams and Evans (1953) described a successful treatment in a clinical case of severed superficial and deep flexor tendons on a 5 year old dairy cow . The limb was supported with an iron bar in a normal position and a vertical bar 17 by 1½ inch strapped on the volar surface of the limb , which was welded to a horizontal plate turned up in front and on

the sides like a boot to enclose the foot. The animal was casted and the ends of the tendon sutured but tore out with the slightest movement. The wound was dressed and the support was strapped on. The wound healed in four weeks and the appliances was removed in six weeks . The cow started walking with slight limp after three months of the injury, which soon disappeared .

✓ Joshua (1953) reported tendon repair on a five month old kitten unable to use the left hind -leg after an accident with hock completely flexed and a small hard object ,clearly palpable behind the distal third of the tibia. Under anaesthesia, on incision the hard object was found to be a detached portion of the tuber -calcis still remaining attached to the superficial flexor tendon. The detached chip was removed and unable to attach it to the os-calcis, it was sutured to the tendon of deep flexor. Six months later, no differences could be detected between the other hind -limb.

Cannaghan and Hanson (1958) believes that rupture of gastrocnemius tendon in fowls is due to hereditary factor and influenced by the activity of the gonads.

O'Connor (1960) described that rupture of tendons in horses occur chiefly in the lower parts of the limbs, affecting chiefly the flexors of the digit and the suspensory ligament. He stated the following causes for both pre-disposing

and exciting causes for this condition:- Pre-disposing causes :-

- (1) Natural weakness of the tendon.
- (2) Weakening of the tendon by some debilitating disease.
- (3) Working a horse in unfit condition.
- (4) A tiring race, the rupture occurring towards the end of the race when the muscles are exhausted, and consequently excessive strain is thrown on the tendons.

The exciting cause of flexor rupture include violent over-extension of the fetlock and inter-phalangeal joints.

He ascribed the following criteria in the treatment for tendon-rupture.

- (1) Keeping the ends of the ruptured tendon as close together as possible.
- (2) The application of supporting pitch or plaster- bandage .
- (3) Keeping the patient at rest, slings being usually indicated to take some of the weight off the limbs, and obviate attempt at lying and rising.

✓ Morcos (1962) reported tendon wound healing after tenotomy of the Achilles tendon in rabbits and rats by injecting daily I/M with either vitamin K (10 mg), isoniazid (12.5 mg) or cortisone (5 mg) or received diphenylhydantoin sodium('dilantin') in the drinking water (100mg . Per 100 ml.) daily , their average intake of water being 20 ml. He concluded that Vitamin

Vitamin K and dilantin were both effective in promoting repaired healing and restoration of function ; isoniazid and cortisone both retarded healing particularly the later.

✓ O'connor (1960) advocated silk for use as suturing material as catgut can not withstand the strain. The author also described the following methods to bring the ends of the tendon into apposition :

(1) Pass the thread obliquely through each end of the tendon and tie the two ends laterally.

(2) Pass the needle through the upper end of the tendon near its border from behind forwards, and then close to the opposite border from before backwards. Then suture the same on the inferior end, but in this case pass the threads successively from behind forwards and then tie them.

(3) Make two sutures - Viz (1) an affronting suture close to the Cut-ends , and (2) a suture of support farther away

(4) Pass the thread twice through the upper end of the tendon, then bring it back through the inferior end and tied laterally.

Butler (1965) have stated the different suturing pattern for tenorrhaphy :

(1) The Bunnell - Mayer tendon suture is the most effective for anastomosing tendons which are round or

semiround in shape. This technic is carried out with a double armed suture with a small straight needle at either end. Either silk or a fine gauged stainless steel wire can be used. The first stitch is taken approximately $\frac{3}{8}$ of an inch proximal to the traumatized region. This is usually about $\frac{1}{4}$ of an inch from the end of the tendon. The needle is pierced the tendon in a transverse direction and then re-enters the tendon at an angle of about 45 degrees pointed towards the traumatized end. A second oblique stitch is taken at a right angle to the first. Following this, two corresponding oblique stitches are taken. The traumatized portion of the tendon is removed with a razor blade or scalpel just distal to the suture ; this will leave a cross section of normal tendon.

When the described step is completed , the tendon is steadied and the needle is again inserted and brought out approximately in the middle of the cross section of the tendon the same procedure is carried out with a second needle. This will result in a double cross stitch which will leave only a small amount of suture material on the surface of the tendon with both ends of the suture coming out through the end of the cross section . The same Procedure is carried out on the distal stump. After this is completed , the two tendons can be drawn together by tightening the suture. Three knots are tied in each suture .

(2) The straight needle enters the Proximal tendon stump from the side about $\frac{1}{2}$ inch from the severed end in such a manner that it emerges in the centre of the cut end of the tendon. The suture is drawn through until the barb on it engages the side of the tendon. The straight needle is then inserted into the centre of the cross section of the cut end of the distal segment. The needle is inserted down the tendon and emerges through the side of the tendon; it is then pulled through the overlying tissues and skin. At this point, the suture is tied to a button. The other end of the suture with the curved needle is brought out through the skin and tied over a button in a similar manner. This technic is possible due to the fact that only the proximal end of the tendon is active; the distal end plays a passive role. This technic is satisfactory for anastomosing tendons which are small in cross section. The suture can easily be removed following healing by removing the distal button and pulling on the proximal button.

The Bunnell Mayer suture is not applicable for use in small flat tendons because they are so small on cross section. In this instance, the buttonhole overlapping suture is preferable. This particular suture has some disadvantages in that it leaves a small portion of tendon exposed, the sutures are not completely buried, and the area of anastomosis is bulkier than the normal portion of the tendon. It is essential that the tendon stumps overlap by at least $\frac{1}{2}$ inch. The buttonhole suture is

contraindicated in areas where a tendon passes through a sheath, as the Circumference of the sheath is closely adopted to the size of the tendon. This technic can be used where the tendons are moving through loose connective tissue and where there is an abundance of paratenon ; here the bulkiness will not be detrimental.

Morel - Fatio and Ducourtieux (1964) described that in Primary repair of flexor tendons in hand surgery, the danger of subsequent infection must be taken into account which is related to the character and degree of the original wound . Retained non- resorbable sutures must be considered as a foreign body.

Hickman (1964) described the use of fine suturing material for tendon suture with sufficient holding strength like cotton, linen thread and multifilament stainless steel wire. The author also stated various technique to bring the ends of the tendon into apposition by Quilted or Mattress suture and Koch - Mason Technique.

Myers et al (1964) reported the tendons repaired with Silk , Cotton, Steel, or Plastic sutures over cohesive steel reinforcing sutures , 69 % healed by Primary Union. The failures were caused by breaking of the sutures, by inaccurate placement of the suture, or by dislodgement of the cohesive steel after the adhesive was no longer

effective .

Batson (1963) reported successful repair of both superficial and deep flexor tendons in a 4 years old dairycow which was injured by the blade of a scoop on a farm tractor . The wound was a horizontal incision about 7 to 10 cm long. It was decided not to enlarge the wound to facilitate suturing. The foot was held in a flexed position and the ends of the deep flexor tendon were grasped with Allis tissue forceps. The ends of the deep flexor tendon were approximated and sutured together with two sutures of extra heavy Synthetic suture material positioned so that the knots were on the sides of the tendon. The process was repeated with the superficial flexor tendon except that four sutures were used to secure the severed ends and they were so placed that the knots were medial, lateral and Posterior. A Plaster of Paris caste was not used because of the difficulty of keeping a cast on the entire leg and foot, the danger of necrosis, and the slushy wet quarters which would keep the padding under the cast wet for the entire time it was in place.

Instead, the leg was padded lightly with cotton and wrapped with gauze, and an aluminum splint was applied. The leg and foot were then heavily taped with adhesive tape. The wound was left open and when the cow rose, however the splint crumpled, and the foot extended beyond the normal

position. The cow walked a few steps and then assumed a recumbent position again. After this occurrence, it was decided to make a special brace. The tape and the aluminum splint were removed, leaving the leg covered only with gauze except near the foot where tape was also applied. The brace was then applied and secured in place with two leather straps. When the cow stood, the leg and foot remained in the normal position. The wound healed without complications, and the sutures were removed from the skin after three weeks. The brace was removed five weeks after initial application, and the cow walked well except for a slight limp which was noticeable when the cow walked but not when she ran. There was no significant loss in milk production.

Pulvertaft (1965) described the three methods of joining tendons in human surgery employing stainless steel wire and silk for apposition of tendon ends:

- (1) The Mayer - Bunnell criss cross stitch, excellent in securing a firm grip and accurate apposition. The only possible criticism is that the epitenon is penetrated several times.
- (2) The second method used is the Bunnell double angle stitch. This is an extremely useful suture for bringing into apposition more than two secured tendon ends at a time

(3) The mason or Chicago stitch technique though widely accepted , but did not found favour with the author .

✓ Belenger et al (1965) reported the repair of ruptured Achilles tendon in human by the use of autogenous skin without removing the epidermis. After resecting extensively all degenerated and frayed tendon, the strip of skin was sutured with Nylon and immobilized in plaster for three weeks . Weight bearing was started at five to six weeks time.

✓ Stuart (1965) described Primary repair of the extensor tendons over the meta carpophalangeal joints. Accomplished primary end to end suture with No. 3-0 Silk and all the fingers were immobilized on a plaster slab. Patients were divided into three groups : 35 patients were splinted for one day , 80 patients for 10 days and 22 patients for three weeks. The author reported excellent result in 79 % in group II , 73 % in group III and 60% in group I .

Lewis and Manelis (1965) stated direct suturing of tendon ends for spontaneous tendon rupture associated with either tenosynovitis, previous, trauma or systemic degenerative disease by frequent attrition of tendon at the rupture site.

Moberg (1965) reported three causes of tendon rupture:
(1) Attrition from raw bony parts over which the tendon must pass .

(3) The mason or Chicago stitch technique though widely accepted , but did not found favour with the author .

✓ Belenger et al (1965) reported the repair of ruptured Achilles tendon in human by the use of autogenous skin without removing the epidermis. After resecting extensively all degenerated and frayed tendon, the strip of skin was sutured with Nylon and immobilized in plaster for three weeks . Weight bearing was started at five to six weeks time.

✓ Stuart (1965) described Primary repair of the extensor tendons over the meta carpophalangeal joints. Accomplished primary end to end suture with No. 3-0 Silk and all the fingers were immobilized on a plaster slab. Patients were divided into three groups : 35 patients were splinted for one day , 80 patients for 10 days and 22 patients for three weeks. The author reported excellent result in 79 % in group II , 73 % in group III and 60% in group I .

Lewis and Manelis (1965) stated direct suturing of tendon ends for spontaneous tendon rupture associated with either tenosynovitis, previous trauma or systemic degenerative disease by frequent attrition of tendon at the rupture site.

Moberg (1965) reported three caused of tendon rupture:
(1) Attrition from raw bony parts over which the tendon must pass .

- (2) Invasion of granulations into the tendon structures.
- (3) Tendon necrosis due to injections of hydrocortisone.

Tubiana (1965) Preferred long incisions in Secondary or late repair cases in order to resect the tendon sheath, free the adhesion, and to protect the neuro-Vascular bundle.

✓ Land and Viernstein (1966) reported the study of spontaneous non- traumatic ruptures of the achilles tendon and stated that rupture of the tendon occur after degenerative changes have set in . This has also been supported by Hipp and weigert (1966) .

✓ Lynn (1966) have reported the repair of ruptured achilles tendon by employing plantaris tendon as a membrane to re inforce the repair .

Myers and Lundvall (1966) reported that normalcy could be restored to great extent in feals with weak flexor tendon by application of supportive bandage.

✓ Schauwecker et al (1967) described the use of direct suture for the Achilles tendon rupture in human with symphetic material, the use of tendon graft from the plantaris Palmaris tendon , or a Z- plasty using autojenous tendon.

Hernandez et al (1967) instituted a Programme of early mobilization of the affected digit in order to accelera-

accelerate rehabilitations of patients with flexor tendon injuries :-

(1) Passive movement were started on the first and second Post operative days. These movements consisted of both flexion and limited extension, because flexion mainly relaxed the tendon and extension moved it back and forth, allowing no adhesions to form.

(2) Active mobilization started on the second, seventh and fourteenth days.

Mekenzie (1967) described two different type of multiple barbed suture for the long flexor tendons of palm and fingers, made from nylon. The advantage of using barbed sutures provided less suture material within the tendon and less trauma to the tendon at the suture site. Nylon appeared to be the best material because of its low stretch co-efficient

Bruner (1967) have described a Zig -zag Volar digital incision on flexor tendons , provide direct exposure and clear vision of the tendon without disturbing neuro -muscular bundle . There was no complication of flexor contractures or adhesions.

Langenskiöld (1967) reported a satisfactory result in the treatment of chronic nonspecific tenosynovitis of the posterior tibial tendon in man by removal of granulation tissue present over the tendon sheath.

✓ Stenstrom (1967) described a new method for the distal anastomosis in flexor tendon grafting. The distal anastomosis was performed after determining the proper tendon length. A nonabsorbable thread was looped around the distal tendon, being held to the tendon in sling fashion by a 5-0 steel suture ligature in the graft. The thread was passed through the nail-bed and affixed to the other side of a button above the nail.

Robinson (1968) reported a technique of injecting a sclerosing agent (monoethanolamine oleate) into damaged tendons. This method produced a deep seated inflammatory reaction at the site of the injury. The intense hyperaemia produced help in the healing process and the weakened structures are considerably strengthened by the dense deposition of connective tissue . This line of treatment can perhaps be only advocated when facilities for more conventional or radical method is not readily available.

Nilsson (1969) have described the operations for the repair of superficial flexor tendons, in horses by splitting the tendon and suturing it, with either continuous No.0 or I catgut or with simple interrupted stainless steel(0.21 mm) sutures .The author has classified more than 50 % success in this technique .

✓ Me Farlane et al (1968) reported better results

with tendon suture in comparable to tendon graft with profundus tendon injuries in man. In patients with the Profundus tendon sutured average range of motion of the distal joint was approximately 80 % of normal . With tendon graft, the average range was approximately 55% of normal.

Pulvertaft (1965) has reported the low reaction to stainless steel which make it the most desirable material and the disadvantage of kinking and breakage in the single strand type can be overcome.

Reed (1962) stated that chances of recurring injury are great because the scar tissue formed has insufficient tensile strength to withstand the stresses of heavy training and racing.

According to Bunnell (1944) , as cited by Padgett and Stefenson (1948), has stated the method of using removable stainless steel wire for tendon suture allows a little tendon motion if the suture anchorage is made beyond the first joint distal to the suturing. It is found that in the first two or three weeks active exercise of the sutured tendon does not hasten healing but instead provokes adhesion.

Hickman (1964) has stated that when connective tissue will be slowly replaced by specific tendon

tissue (Collagen fibres) in time , though may be never completely ; complete rest is to be avoided as it would aid the formation of adhesions.

Melmed (1965) reported that the strength of surgically repaired tendon during steroid therapy is 40% less than in control animals . Histologic studies of these tendon also showed a suppressed fibroblastic reaction and delayed maturation of fibrous tissue.

According to Mason and Allen, as cited by sealy (1946) has stated three stages in the repair of tendons :-

- (1) Fibroblasts derived from the paratenon, epitenon and fibrous tissue septa between the tendon bundles gives a fibrous union . This stage extends to the 5th day, with the tensile strength of the wound decreasing during this time. Until the 5th day of tensile strength is dependant upon the sutures. About the 5th day the sutures tend to pull out easily of softening of the tendon constricted by the suture.
- (2) From the 6th to 14th day the tendon fibres grow unto the soft callus like fibrous tissue , and during this time the tensile strength at the site of repair gradually increases . After the 16th day increase in tensile strength continues, but at a greatly reduced rate, for a period of about six weeks.

(3) During this period, usually the 19th to 21st day, the tendon becomes differentiated and organised and the gliding function returns.

✓ The gliding function gradually returns from about the 14th to the 21st day, regardless of motion. Function exerts two opposed influences on a healing tendon. Too early motion enhances the reaction around the suture line and causes retraction of the tendon ends, with delay in bridging the gap. On the other hand, if these results are avoided early motion promotes the tensile strength at an earlier period. Thus the time for starting motion is dependant upon the proper evaluation of these factors.

Flynn (1965) reported gross and microscopical findings of sutured tendons at different interval. :-

Three days after suture:-

Gross :- Edema was seen in the sheath and in the peritendinous tissues. The proximal and the distal stumps were edematous and hyperaemic, and there was some separation of the stumps. The suture hold the stumps but not very securely. The gap between the stumps was filled with red gelatinous granulations without any tensile strength.

Microscopic Examination :- Proliferative changes were not advanced sufficiently to afford functional union. The

stumps were separated and end against granulation tissues in the gap. Anuclear necrosis involved the ends of the tendon . No mitoses were seen. The silk suture was surrounded by white blood cells. Intra tendinous vessels were seen. The sheath showed a great proliferation of leucocytes, lymphocytes, histiocytes, and fibroblasts and an increased number of blood vessels. Sheath tissues entered into the gap and form granulation tissue. The early granulation tissue in the gap consisted of many leucocytes, lymphocytes, histiocytes, and fibroblasts. There were many red blood cells and much fibrin and capillary proliferation. The suture seemed to be the main unifying factor.

At the end of one week :-

Gross examination :- Continuity appeared to be due to the proliferation of the sheath and the peri-tendinous tissues. The sheath had fused with the stumps . The gap was filled by a fusion of the sheath and organizing granulations .

Microscopic Examination :- Revealed a union of the stumps effected by proliferation tissue from the sheath. The proliferating sheath tissue was greater than at three days and contained leucocytes, lymphocytes, histiocytes, fibroblasts, and proliferating capillaries. The gap was penetrated by sheath tissues. Both stumps showed active proliferation of tenoblasts. The nuclei of the tenoblasts were

larger than at three days and there were many basophilic fibres . Some mitoses were seen . There was a great proliferation of the capillaries. The gap was invaded by tenoblasts from the stumps. At the end of one week the union appeared to be effected by the sheath .

After two Weeks :-

Gross Examination :- The tendon stumps showed fusion by a fibrous bridge across the gap. Union was mainly by tendon.

Microscopic Examination :- The stumps showed a marked increase and advancement in fibroblastic and Vascular Proliferation and a decrease in other cellular reaction . Mitoses were more numerous than at one week . Tenoblasts with many collagen fibres bridged the gap from proximal to the distal stump. Tenoblasts were arranged longitudinally in the lines of stress. The gap was penetrated by sheath tissues. The union at the end of two weeks was effected by tenoblasts and sheath.

After third week :-

Gross Examination :- The gap was bridged by a tough fibrous tissue. The fibrous sheath, which was less edematous than previously extend from stump to stump.

Microscopical Examination :- The stumps contained fibroblasts which were more mature than at two weeks .The nuclei were smaller and many more collagen fibres were seen. There

was a continuity of similar fibroblasts extending from stump and stump. The fibroblasts were arranged longitudinally in lines with the pull of the tendon. Longitudinal blood vessels were numerous. Union after three weeks was mainly due to the tendon.

After Four Weeks :-

Gross Examination :- The healed tendon appeared to glide beneath a thin fibrous sheath.

Microscopical Examination :- The tenoblasts in the stumps and the gap site were more mature than at three weeks. The nuclei were smaller. No mitoses were seen. There was more collagen. Tenoblasts appeared to form into bundles as in mature tendon.

After Seven Weeks :- Tendon cells, arranged in bundles were seen microscopically.

After Ten Weeks :- Mature tendon cells were arranged in bundles and resembled a normal tendon.

Peacock (1965) described three phases in the tendon wound healing. :-

(1) Cellular reaction phase :- In this phase neither mature tendon nor the surrounding fibrous sheath contain cells capable of amalgamating coapted tendon ends. Tendon

healing was entirely dependant upon large stellate fibroblasts migrating into the anastomosis from outside the tendon itself.

(2) Fibrous Protein Synthesis Stage :- This stage began on the third day after fibroblastic migration. A soluble molecular precursors of Collagen was synthesized and was extruded into the intercellular milieu.

(3) Scar remodeling Phase :- In this phase the tendon gliding action was possible due to an enzymatic reaction which had the capacity to degrade collagen.

M A T E R I A L S
A N D
M E T H O D S

M A T E R I A L S A N D M E T H O D S

P A R T - I

OPERATIVE SURGERY

Materials

(1) Selection of Animals :- Buffalo - Calves, representing the bovine species, were selected for the present study. Animals were procured at different intervals and soon after their receipt, a preliminary examination was done and temperature, Pulse and respiration were recorded. This was done to ensure that they are reasonably healthy so that the results of the present work may not be materially affected. All the selected animals, thus, were apparently healthy.

Approximate age varied from one to two and half years, while the body weight varied rather widely from 200 to 300 lbs. The body weight was calculated by measuring the length and girth in inches, according to the standard formula :-

$$\frac{L \times G^2}{300} = \text{Body weight (lbs)}$$

(2) Design of the Experiment :- Before proceeding to the actual operation, the selected animals were divided at random into different groups. In total, twelve buffalo calves were used, and they were divided into three groups.

Each group consisting of four animals according to the number of suturing technique employed.

In this experiment three techniques :-

(1) Koch- Mason method of tendon suturing ; (2) Bunnell - Mayer double cross technique of tendon suturing and (3) Simple Mattress method of tendon suturing were taken up for study respectively for the first , Second and third group.

Each technique comprised of separate suturing material. The Koch - Mason Technique in group I employing silk suturing material ; Bunnell Mayer double cross technique in group II employing stainless steel suture while in group III Cotton sutures were used as suturing materials .

(3) Suturing Materials :-

- (1) Braided Silk (3-0)
- (2) Stainless steel wire (35 mm)
- (3) Cotton - Mercerized Commercial.

METHODS :-

PRE - OPERATIVE PREPARATIONS :

(1) Clinical Examination :- The following Pre-Operative Examinations were made :-

(1) Recording of Temperature, Pulse and respirations :-

Temperature , Pulse & respirations were daily recorded morning and evening at rest. (Table No : -3) .

(ii) Faecal sample Examination and Treatment :- Faecal sample from every animal were examined and routine investigation for the presence of any parasitic infestation was done. All the buffalo- Calves, usually, harboured stomach and intestinal worms, belong to the species of Haemonchus , Bunostomum strongyles. They were treated suitably (Phenothiazine, Carbon tetrachloride, sulphamazathin 5 gm. Tablet -ICI) in the prescribed doses. After the administration of ^{at} the drug an interval of seven days was allowed , before taking up the operation .

(iii) Ecto Parasites:- Ticks and lice infestation , if found were treated with Gammexene lotion.

(iv) Haematological Studies:- was done primarily for anaemia and blood borne protozoan infection. Nothing significant was found (Table No.4)

(v) Recording of body weight :- The body weight of individual animal was again calculated and recorded (Table No. 2)

(2) Preparation on the Previous day of Operation :-

The buffalo -calf to be operated upon the next morning was selected at random . The animal was washed and the

skin around the right side of the leg, between the hock and fetlock joint was scrubbed thoroughly, shaved and cleaned with soap and water. The saved area was disinfected with savlon (ICI) lotion, Sponged , dried and swabbed with spt. Mercurochrome 1%.

Only light feed was allowed in the morning consisting of small amount of straw and green grass. It was then separated from others to a clean dry stall . Water was given adlibidum for the whole day.

(3) Preparations on the Operation day :-

The operation was carried out in the morning to get maximum time for observation during the rest of the day.

(i) Preparation of the Animal :- The temperature, Pulse and respirations were recorded. Prior to operation the shaved area was thoroughly scrubbed with soap and water and sponge dried and finally swabbed with Spt. Mercurochrome 1% .

(ii) Sterilisation :- The instruments, drapes, gauzes and other appliances were sterilised properly. B.P.Blade and rubber tubing of Doyen clamp were sterilised with conc. Savlon lotion.

Suturing materials such as silk, Cotton,Stainless Steel wire and Vetafil were sterilized by boiling along with other instruments.

Scrubbing of the Surgeon's hand with soap and water

followed by savlon lotion was done as a routine procedure.

(iii) Anaesthesia :-

(a) Narcosis :- Chloral hydras in the doeses of six drachms was used as Sedative. The animal was drenched atleast half an hour prior to the operation.

(b) Posterior tibial block :- Novocaine 2.5 % solution was used for posterior tibial block.

(iv) Positioning of the Animal :- The animal was cast on its right side and secured Properly. The limbs except the right limb was secured by a single rope. The limb to be operated was kept over a sterilised drape and tourniquet was applied well above the operative site.

(4) OPERATIVE PROCEDURE

The site of the operation was finally painted with spt. Mercurochrome 1 %, and the drapes applied, leaving the operative site completely exposed.

(i) Site of Incision. :- An incision about 6" long was made longitudinally on the medio lateral aspect begining just behind the hock and extending toward the fetlock . The skin flap was retracted with Allis forcep/ to fascilitate exposure.

(ii) Exposure :- The exposed superficial and deep fascia was cleared off by blunt dissection to expose common sheath of

the superficial and deep flexor tendon with the help of small artery forceps. The area was mopped up with sterilized gauze and belleding, if any, checked by artery forcep and some times by ligation.

(iii) Withdrawal of superficial digital flexor tendon :-

A longitudinal incision was made with scalpel over the common sheath of both superficial and deep digital flexor with great care to minimum injuries and the tendon sheath was grasped on either side with artery forceps. A sharp demarcation between the superficial and deep digital flexor enabled clear cut exposure of superficial flexor tendon and was achieved by the help of tenaculum introduced between the superficial and deep flexor tendons . (Photo- 1).

(iv) Tenotomy :- Sterilised pieces of gauze were placed around the whole circumference at two points of the exposed tendon. Again a rubber shod Doyens clamps were applied and the tendon of superficial flexor was secured by placing a tenaculum underneath . This procedure was adopted in all the three groups (Photo - 2)

(V) Techniques of Tendon Suturing :-

The three techniques of suturing were taken up for study:

I BUNNELL - MAYER DOUBLE CROSS TECHNIQUE

The Cut -ends of the tendon were brought close together

for suturing. The end of the devided tendon was grasped with tissue forceps to steady the tendon for placement of suture. The forceps was grasped between the thumb and middle finger, allowing the tendon to rest against the index finger. This technic was best carried out with a double armed suture with a small straight needle at either end. The stainless steel wire was used as suturing material. The first needle was pierced about half of an inch from the end of the tendon in a transverse direction and then re-enter the tendon at an angle of 45 degrees pointed towards, the end. This fashion of Piercing followed by a second oblique stitch, was given at a right angle to the first. Following this, two corresponding oblique stitches were given and the tendon was steadied. The needle was again inserted and brought out approximately in the middle of the cross-section of the tendon. The same procedure was carried out with a second needle. Then both ends of the suturing material was grasped with artery forceps

The same suturing technique was adopted for the distal stump of the tendon. Doyens clamps were pushed forward on the same course to facilitate close apposition of both stumps and drawn together by tightening the suture. Three knots were tied in each suture. Terramycin liquid was applied to prevent infection.

II KOCH - MASON TECHNIQUE :-

The stumps of the tendon were brought in apposition and

braided Silk Ligature (3-0) with two straight thin atraumatic needle introduced at each end . In the proximal stump of the tendon behind half an inch from the cut end, the first needle was pierced transversely straight through the diameter of the tendon . The same needle was then angularly pierced at an angle of about 45 degrees through the tendon by the side of previous point and continued piercing until it emerged through the end on the opposite side of the base-line of the tendon and grasped with artery forcep. The Silk ligature eyed through the second straight needle, travelled in the same direction as the first one and grasped with artery forcep after it emerged through the opposite base-line.

In the other stump of the tendon, the same course of suturing pattern was followed as in the first resected portion of the tendon. (Photo -3)

The Doyens clamps were pushed forward on the same course to facilitate close proximity of both stumps and drawn together by tightening the suture and placing considerable tension . Three knots were tied in each suture - (Photo - 4) . Few drops of terramycin liquid applied to prevent infection.

III MATTRESS TECHNIQUE OF TENDON SUTURING :-

The Cut -ends of the tendon were brought close together

for suturing. The end of the divided tendon was grasped with tissue - forceps to steady the tendon for placement of suture. The forcep was grasped between the thumb and middle finger, allowing the tendon to rest against the index finger. This technique was best carried out with a small straight thin needle. Cotton mercerized was used suture material for this technique.

The needle was pierced in vertical direction half the way and then projecting straight its point through middle of the thickness towards the end of tendon. The needle was taken out from the thickness of the first stump of the tendon and again directed through the thickness of second stump . After directing for a considerable distance, the needle was turned upward and taken out of the surface of the tendon. The needle was then pierced behind the previous point half way vertically and projecting , in turn , through middle of the thickness towards the end of the stump and was taken outside from the second stump. Again , the needle was inserted straight through the thickness of the first stump. After directing for a considerable distance, the needle was turned upward and taken out of the surface of the tendon and grasped with artery forcep. The Doyens clamps were pushed forward on the same course to facilitate apposition of the tendon stumps. The artery forceps were removed to hasten free the suture materials and were tied by giving three knots. If , the

separation of the tendon stumps remained, the ends were brought into apposition by interrupted sutures on both sides

(Vi) Suturing of tendon sheaths :- After completed the suturing of tendon ends it is necessary to examine for proper placement of the sutures. The Doyens clamps were removed and the area under clamp was gently manipulated to restore the blood circulation. The area was mopped with sterilised gauze. The retracted tendon sheath already grasped with artery forceps was sutured with either Silk or Cotton thread. Finally terramycin applied over the area to prevent infection.

(Vii) Suturing of Skin Incision. :- Finally the skin was placed into apposition with the help of Allis forceps and suturing was accomplished with vetafil sutures, in the horizontal Halsted fashion (Photo 5). Then the incision site was cleaned with Rectified spirit and the the skin edge was supported with gauze pad soaked in terramycin liquid .

(Viii) Application of bandage and Plaster Cast :-

After padding with gauze, light bandage was applied which was followed by the application of Plaster cast (Velroc). Velroc was wrapped tightly from hock to fetlock joint (Photo -6)

Post Operative Care And Management :-

(i) Recovery after the Operation :- Recovery was quite normal in most of the cases and were able to stand and bear weight. Animal moved with marked limping for about a week after the operation.

(ii) Keeping the animals in Separate stall :- The Experimental animals were kept in stall for 5 to 6 days and then allowed to graze.

(iii) Recording of Temperature, Pulse and Respiration :-

After recovery from the operation, temperature, Puls and respiration were recorded . Daily recording was done every morning and evening till the 7th day of the operation .

(iv) Removal of the Skin Sutures :- The Plaster cast (Velroc) was cut at 10th day and the skin sutures were removed . The site was painted with 1 % spt. Mercurochrome and tight supported bandage was applied between hock and fetlock joint .

(v) Post -Operative Treatment :- Antibiotic (Dicrysticin) Started from the day of operation upto the fourth day in all groups of animals.

PART - II

SURGICAL PATHOLOGY

MATERIALS

Experimental animals were euthanized on the 10th, 14th, 21st and 30th day of Operation. Autopsy was conducted with special reference to Post Operative sequelae of tendon suture. A piece of superficial digital flexor including the sutured part was collected and Preserved in 10 % formaline for gross and microscope studies.

METHODS

Gross- Examination :- At autopsy every animal was carefully examined for adhesion, thickening of sutured part, presence of Scar or for other abnormalities.

Microscopic Examination :- Paraffin blocks of the tissues were made by standard techniques. The sections through sutured parts were made and the slides were stained with standard technique of Haematoxylin and Eosin stain and mounted. The slides were then examined for his-to - pathological changes.

OBSERVATIONS

AND

RESULTS

OBSERVATIONS AND RESULTS

The Tendon suture was studied in buffalo -calves with particular reference to its clinical function, macroscopic and microscopic appearances .

The clinical function of tendon suture included :- Preservation of gliding function and movement of animals,. The macroscopic observations were confined to adhesion, thickness of stump and Presence of scar resulting from tendon suture . The microscopic examination included histopathological changes found at the site of suture.

Suturing materials used in the present plan were Silk (3-0) , Cotton mercerized and stainless steel wire (35 mm). The techniques in this study were Koch - Mason and Mattress as advocated by Hickman (1964) ., and Bunnell - Mayer double cross Technique advocated by Butler (1965) .

GROUP - I

Buffalo- Calf No. 1 :- The animal weighed 210 lbs approximately. The R.B.C. and differential count was normal . Silk (3-0) was used as suturing material for tendon repair.

No untoward symptoms except in gait were observed during the post -operative management of the animal. The intense limping was observed up to the second post -Operative

week - From the beginning of 3rd week, the limping movement of the animal gradually decreased and after 20th Post-operative days there was only a slight limping tendency and it soon disappeared from the 28th day.

The animal was sacrificed on the 30th Post operative day. On autopsy, the tendon appeared to glide within the tendon sheath. The union at the sutured site was found perfect, which established a complete continuity with an invisible scar (Photo- 7)

The microscopic examination revealed longitudinal arrangement of dense Collagen fibres. In between the bundles of dense collagen fibres, there was loose presence of connective tissue and this loose connective tissue was infiltrated by large number of lymphocytes. Rare number of fibroblasts were seen.

Buffalo -Calf No.2 :- The approximate body weight of the animal was 232 lbs. The R.B.C. and differential count was found normal. Silk (3 -0) was used as suturing material for tendon repair to regain continuity.

Clinically, the part beyond the wrapped plaster cast was swollen. The swelling continued till the 5th post operative day. The intense limping movement of the animal was present through out the second Post- Operative week.

From the 18th Post- Operative day the intensity of the limpness decreased.

The animal was sacrificed on the 21st Post Operative day. The gross examination of the tendon appeared to have perfect continuity although distinct Scar was visible at the suture site. There was a marked adhesion around the line of sutured part (Photo -7 -(2) .

Microscopically, the more collagen fibres were seen which were nearly arranged in longitudinal direction. Very few number of fibroblasts were seen. Lymphocytes were absent.

Buffalo- Calf No. 3 :- Approximate body weight of the animal was 236 lbs. The R.B.C. and differential count was found normal. Silk (3-0) was used as suturing material for adjoining the tendon ends.

Clinically, no untoward symptoms were observed during the post operative period. The limping gait remained throughout this period .

The animal was sacrificed on the 14th Post operative day on antopsy, the gross examination of tendon revealed fusion of the tendon ends. A distinct scar was present at the site of suturing . The tendon -sheath was more oedematous and had marked adhesion. (Photo No. 8 -(3).

The microscopical examination revealed presence

of irregularly arranged collagen fibres. More number of fibroblasts were seen . Lymphocytes were present in few numbers .

Buffalo -calf No. 4 :- Approximate body weight of the animal was 225 lbs . The R.B.C and differential count was normal silk (3-0) was used as suturing material for adjoining tendon ends.

Clinically, no complications were observed during the post-operative period . The limping gait remained through out this period.

The animal was sacrificed on the 10th Post operative day. On autopsy, the macroscopic examination showed breakage of tendon suture. The tendon sheath was more oedematous and found broken. Marked adhesions were noticed (Phot No.8- (4) .

The microscopical examination revealed less number of Collagen fibres present irregularly . The fibroblasts were seen in few numbers but lymphocytes were present in a large number.

G R O U P - R E S U L T .

All the four animals in this group under observation showed no post-operative complications except

Buffalo- calf No.2 . The animal developed swelling of the part beyond the wrapped plaster cast . The movement of the animal remained limp in all with varying degree of intensity but in Buffalo -calf No.1 the limping tendency in gait disappeared towards the end of a month.

On autopsy after the observation period , the gross examination of the sutured part revealed no complications in the animals except that of Buffalo-Calf No.4. In this case suturing material of both tendon sheath and tendon ends were found broken. The degree of adhesion was marked with mild to Severe degree on different duration of time. The adhesion was absent in the animal sacrificed on the 30th day. Among the group of four animals, the tendon wound showed normal healing except in Buffalo- calf no.4 in which failure of suturing was found .

Microscopically , the amount of collagen fibres increased with post- operative extension period. At one month the collagen -fibres reached nearly normal position and were regularly arranged in longitudinal direction. The number of fibroblasts relatively decreased towards the end of a month . The infiltration of lymphocytes between the dense collagen fibres were more or less relatively lower at one month.

GROUP I I

Buffalo- Calf No.5 :- Approximate body weight of the animal was 285 lbs. The R.B. C and differencial count was found normal . The suturing material used in this technique was stainless steel wire (35 mm) for approximating the tendon ends .

No untoward symptoms were observed during the post operative period except in the movement of the animal . A high degree of limping gait was present during the first week . The limpness of the same intensity remained throughout the second week but gradually it declined from the 18th Post -Operative day. After 28th day, the gait pronounced with a slight limping tendency and remained till it was sacrificed. The animal was sacrificed on the 30th Post Operative day. On autopsy, the gross examination of the tendon appeared to have perfect continuity and healed without leaving scar . There was no adhesion of the tendon with the tenden sheath . (Photo -9 - (5) .

The microscopical examination revealed an increase amount of collagen fibres which were infiltrated by less number of lympho cytes . The fibroblasts were present in few number.

Buffalo- Calf No. 6 :- The approximate body weight of the animal was 270 lbs . The R.B.C. and differential count was

found normal. The suturing material used was stainless steel wire for uniting the tendon -ends.

In this case, the part beyond the wrapped plaster cast was swollen and revealed intense Pain which was observed on manipulation . The limping gait of the animal was present through out the post -operative days . During the first and second week the intensity of the limping was more pronounced. After entering the third week, the limpness gradually declined and continued till the animal was sacrificed on the 21st post operative days.

On autopsy, the gross examination of the tendon showed a perfect continuity. An ill developed scar with adhesion was also present at the site of suture. Photo No. 9 - (6) .

The microscopical examination revealed increase in amount of collagen fibres and coming to normal shape, although they were irregularly arranged in the shape of whorl like. No lymphocytes were seen .

Buffalo -Calf No. 10 :- Approximate weight of the animal was 290 lbs. The R.B.C and differential count was found normal .Stainless steel wire was used as suturing material for anastomosing tendon ends.

Clinically, the animal did not show any

Complication other than limping gait and was more intensively throughout the first week of observation. The limping syndrome lasted more or less till it was sacrificed.

The animal was killed on the 14th Post operative day. The gross examination of the tendon revealed fusion of the tendon- ends. A well - developed scar was distinct at the site of suturing . Adhesion was also well marked and the suturing of the tendon-sheath was found broken . (Photo No. 10)

Histopathologically, the Collagen fibres were arranged loosely. There were more number of fibroblasts. Lymphocytes were present but in less number.

Buffalo- Calf No. 11 :- The approximate weight of the animal was 262 lbs. The blood picture was found normal . Stainless steel wire (35 mm) was used as suturing material to regain continuity of the tendon-ends.

The animal showed marked swelling of the Part beyond the wrapped plaster cast and continued till the 7th Post -operative day and disappeared after usual anti-biotic therapy. The gait of the animal remained abnormal throughout the post-operative period.

The animal was sacrificed on the 10th Post-Operative day. The tendon -sheath was found oedematous and its suturing was disrupted . Although the tendon ends

were fused yet the distinct gap was visible. Moreover adhesion was also well marked in the tendon (Photo-10 (11)).

The microscopic examination revealed less number of collagen fibres which were irregularly distributed. Fibroblasts were present more in number. Lymphocytes were also less encountered.

GROUP RESULT.

Stainless steel wire was used as suturing material in the four animals of this group (Buffalo - calf No. 5, 6, 10 and 11) and the suturing of tendon -ends were carried out by Bunnell - Mayer double cross technique.

The Post-operative complication of swelling part beyond the wrapped plaster cast, was found in buffalo-calf No. 6 and 11. The clinical recovery did not return in any animal due to its presence of limping gait from mild to intense degree. A mild degree of limped gait present in the animal sacrificed on 30 post-operative day.

On autopsy, the gross examination of the sutured part after the observation period, revealed no complication other than adhesion. The breakage of suturing material was not found in any animal. The adhesions were present with varying amount in all animals except in buffalo-calf No. 5

The tendon wound showed normal healing in all the four animal but in buffalo- calf No.11 although tendon-ends regained continuity but a small gap was present at the suture site .

The microscopical examination of healed tendon showed relatively an increase in the amount of Collagen fibres and were regularly arranged in about a month Post operative period . More or less the fibroblasts and lymphocytes were reduced in number with increasing the post operative intervals.

G R O U P I I I

Buffalo -Calf No. 7 :- The approximate weight of the animal was 206 lbs. The R.B.C and the differencial count was found normal . Mercerized cotton was used as suturing material for uniting the tendon ends.

Clinically, the animal did not show any complication other than abnormality in the gait the gait of the animal was limping and its intensity remained more pronounced during the first post-operative week . From the 10th day the intensity of the limpness gradually declined. Toward the end of third week , a mild degree of limping gait was observed . This degree of gait remained for sometimes in the 4th post -Operative week and soon dis-appeared.

The animal was sacrificed on the 30th post-operative

day. On autopsy, the tendon appeared to move freely within the tendon -sheath as there was no adhesion in it . The tendon ends were completely fused and perfect continuity appeared although the scar was not distinct . The suturing material was clearly visible well embedded in the tendon. (Photo -11 (7) .

Microscopically, the more number of collagen fibres present which were regularly arranged in longitudinal direction. The less number of fibroblasts were seen. The infiltration of lymphocytes in between the Collagen fibres were also present .

Buffalo - Calf No. 8 :- Approximate body weight of the animal was 240 lbs. The blood picture was found normal . Mercerized cotton was used as suturing material for the union of tendon ends.

Clinically , the animal did not show any complication. The animal showed the symptoms of limping which continued with greater intensity during the first post -Operative week. From the 10th day the intensity of the lameness gradually declined. A mild degree of limping movement was marked towards its end.

The animal was sacrificed on the 21st post op rative day . On autopsy the gross examination revealed no adhesion. The tendon ends were fused and perfect continuity was established at the site of suturing with an ill- developed scar

Scar (Photo No. 11 - (8) .

The microscopic - examination revealed presence of more collagen fibres which nearly arranged towards the longitudinal axis. The less number of fibroblasts were present . Lymphocytes were also seen in less number.

Buffalo- Calf No. 9:- The approximate body weight of the animals was 226 lbs . The blood picture of the animal was found normal. Mercerized cotton was used as suturing material for approximating the tendon ends.

Clinically , no untoward symptoms other than limping gait were observed . The lameness was present with high internity during the first post -operative week and continued to a lesser extent towards the end of second week .

The animal was sacrificed on the 14th post Operative day, on autopsy, the adhesion between tendon and the tendon sheath was well marked. The tendon -ends were fused and continuity was regained . A small scar was present at the site of suturing (Photo 12 - (9)

The microscopic examination revealed irregular distribution of Collagen fibres. A large number of fibroblasts were present which intermangled with lymphocytes. At one point there was a aggregation of lymphocytes .

Buffalo -Calf No. 12 :- The approximate body weight of the animal was 218 lbs . The blood - picture was found normal. Mercerized Cotton was used as suturing material for uniting the tendon ends .

The animal did not show any complication. The gait was limping and continued till it was sacrificed .

The animal was sacrificed on the 10th Post Operative day. On autopsy, the tendon sheath was very much oedematous . The tendon sutures were found broken on one side where as the other side was found in better union. It was marked by distinct scar with adhesion. (Photo No.12(12)).

The microscopic examination revealed the presence of less number of collagen fibres which were arranged irregularly. Lymphocytes were seen more in number but the number of fibroblasts less.

GROUP RESULT

Mercerized cotton was used as suturing material in all the four animals of the same group (Buffalo-Calf No. 7, 8, 9, 12) and suturing of the tendon ends were carried out by Mattress Technique.

No post operative complications were seen in any animal other than abnormality in the gait. The clinical recovery returned to normal in Buffalo Calf No.7, sacrifici-

-ced on the 30th Post operative day but were obstructed the recovery of clinical functions in remaining animals by mild to severe degree of limpness.

On autopsy after the observation period, the gross examination of the sutured part revealed no complication except in Buffalo-Calf No.12, in which tendon suture was found broken on one end, but the other end regained continuity and marked by distinct scar. The tendon wound showed normal healing in all the animals except Buffalo-Calf No.12 as already mentioned. Adhesions were present in the animals with varying degree on different duration of time but in Buffalo-Calf No.7 and 8, no adhesion was marked, and the suturing material clearly visible embedded in the tendons.

Microscopically, the amount of collagen fibres relatively increased with the increase of post-operative intervals. The collagen fibres attained regular longitudinal arrangements in about one month. But consequently, the lymphocytes and fibroblasts reduced more or less with increasing the post-operative period.

EVALUATION OF DIFFERENT TECHNIQUES

The evaluation of different techniques of tendon suturing in buffalo-calves, was made on the basis of clinical function, macroscopic and microscopic appearances.

KOCH-MASON TECHNIQUE:

This technique was employed in four animals using braided silk (3-0) suture material and all the animals were sacrificed on the 30th , 21st, 14th and 10th Post operative day respectively.

On clinical examination, the only one animal (Buffalo-Calf No.1) was returned to normal clinical function (25%) and remaining three animals showed limping gait (75%) . No post-operative complication other than limpy gait were observed except in Buffalo -Calf No.2 showed swelling of part beyond the wrapped plaster Cast(25%).

On autopsy, the gross examination of the Part revealed perfect continuity of the tendon ends in all the animals (75%) except the Buffalo-Calf No.4. Adhesion of tendons with tendon-sheaths were found in three animals (75%) except the Buffalo-Calf No.1. The tendon sutures were broken in only Buffalo-Calf No.4 (25%). Scar from distinct to obscure were present in two animals (50%) except in the Buffalo-Calf no.1 in which scar was invisible and Buffalo-Calf No.4 in which tendon sutures were found broken .

Microscopically , the amount of collagen fibres increased with post operative extension period. At one month, the collagen fibres reached nearly normal position and were regularly arranged in longitudinal direction. The number of fibroblasts relatively decreased towards the end of a month. The infiltration of lymphocytes between the dense collagen fibres were more or less relatively lower at one month.

BUNNELL-MAYER DOUBLE CROSS TECHNIQUE :

This technique was employed in four animals, using stainless steel wire as suturing material and all the animals were sacrificed on the 30th, 21st, 14th and 10th post operative days, respectively.

Clinically , not a single animal restored normal function but the limping gait were marked by all of them (100%). The post operative complication other than limping gait were observed in two animals (50%) with swelling of the part beyond the wrapped plaster cast except in Buffalo- Calf No.5 and 10.

The gross-examination of the part on autopsy, showed adhesions in three animals (75%) except the Buffalo-Calf No.5. The perfect continuity were established in all the animals (100%). Scars from distinct to an ill-developed were marked in three animals (75%) except in the Buffalo-Calf no.5. The sutures for tendon ends were not found broken in any animal.

The microscopical examination of healed tendon showed relatively an increase in the amount of Collagen fibres and were regularly arranged in about a month post operatively. More or less the fibroblasts and lymphocytes were reduced in number with increasing the post operative intervals.

MATTRESS TECHNIQUE :

This technique was employed in four animals, using Mercerized cotton suture material and all the animals were sacrificed respectively on the 30th, 21st, 14th and 10th post operative days.

On clinical examination , only one animal (Buffalo Calf no.7) was returned to normal clinical function (25%). No post operative complication other than limping gait was observed in any animal. The limping gaits were marked in three animals (75%) except in Buffalo-Calf No.7.

The gross-examination of the part on autopsy, showed adhesions in two animals (50%) except the Buffalo-Calf No.7 and 8. In all the animals except in Buffalo-Calf No.12, healing was marked with the perfect continuity of the tendon ends (75%). Scars from distinct to an obscure were present in all animals (75%) except in the Buffalo-Calf no.7. The tendon sutures were found between in only one animal (25%).

Microscopically , the amount of collagen fibres relatively increased with the increase of post operative intervals. The Collagen fibres attained regular longitudinal arrangements in about one month. But consequently, the lymphocytes and fibroblasts reduced more or less with increasing the post operative periods.

IT WAS CONCLUDED, after evaluating the above techniques that more or less the similar findings appeared in all the animals. But Mattress Technique using mercerized cotton was slightly edged over the other two techniques, in respect to the popular availability of suturing material and easier technique which emphasizes its needs under field condition.

DISCUSSION

DISCUSSION .

The researches and experiences made in the human surgery in the field of tendon repair and its different suturing technique, have all along remained the basis of the research under taken here.

The tendon repair entails greater hazards in bovines on account of septic nature of the tendon. According to Padgett and Stephenson (1948), an absolutely sterile field for tendon suture is necessary. Batson (1963) has also the similar opinion while performing tenorrhaphy in a cow.

In the present series, stainless steel wire suture material was used in four animals employing Bunnell-Mayer double cross technique. The tendons were healed in all the animals but the adhesions were present in three animals up to the 21st post operative period. According to Bunnell (1944) as cited by Padgett and Stephenson (1948) the method of using removable stainless steel wire for tendon suture allows a little tendon motion if the suture anchorage is made beyond the first joint distal to the suturing, and it is found that in the first two or three weeks active exercise of the sutured tendon does not hasten healing but instead provokes adhesion. Pulvertaft (1965) reported low reaction to stainless steel suturing suggesting it to be the most desirable material as there is little chance of kinking and breaking even in the single strand type of suture.

Nilsson (1969) has performed operations on the Superficial flexor tendons in the horses by splitting the tendon and suturing it either with continuous No.0 or 1 catgut or with simple interrupted using stainless steel (0.21 m.m.) wire as sutures. He has claimed 36.4% of the horses were able to start more than ten times after the 66 operations on the forelegs, and seven of the horses started more than ten times among eight operations.

Hage and Dupuis (1965) have advocated a primary direct suture in children with clean injuries when it is presented within the first eight hours. According to Lindsay, as cited by Entin (1965), 70% excellent results in children were obtained by direct tendon suture in a series of 31 tendons sutures. Myers et al (1964) reported that the tendons those were repaired with silk, cotton, steel or plastic sutures over cohesive steel reinforcing sutures, 69% were healed by primary union. The failures were caused by breaking of the sutures, by inaccurate placement of the suture, or by dislodgement of the cohesive steel after the adhesive was no longer effective. Solonen(1967) reported the experiences of 140 reconstructions in the human finger including 112 involving the flexor profundus tendon and 28 involving the flexor pollicis longus tendons. He claimed that there had been over all good results in 54%, fair in 33% and poor in 13% of the flexor profundus tendon injuries; and 75% good, 18% fair and 7% poor results of the flexor pollicis longus tendon injuries.

The animals of the different groups were immobilized with plaster cast for 10 days after the suturing of the tendon ends. Stuart (1965) stated a primary end to end suture with No.3-0 Silk in the repair of extensor tendons in the hand over the metacarpo-phalangeal joints and immobilized all the fingers on a plaster slab. In this study, patients were divided into three groups : 35 patients were splinted for one day, 80 (eighty) patients for ten days, and 22 patients for three weeks. Excellent results were achieved in 79%, the fingers splinted for 10 days; in 73% splinted for 3 weeks; and in 60% splinted for one day.

Batson (1963) performed successfully tenorrhaphy on a cow by employing a special brace to immobilize the affected leg. The ends of the superficial and deep flexor tendons were approximated with extra heavy synthetic suture material. The skin and fascia were closed with extra heavy synthetic suture material. Plaster of Paris cast was not used because of the difficulty of keeping a cast on the entire leg and foot, the danger of necrosis, and the slushy, wet quarters which would keep the padding under the cast wet for the entire time it was in place. Instead, the leg was padded lightly with cotton and wrapped with gauze, and an aluminum splint was applied. The leg and foot were then heavily taped with adhesive tape. When the cow rose, however, the splint crumpled and the foot extended beyond the normal position. The cow walked a few steps and then assumed a

recumbent position. After this occurrence, it was decided to make a special brace. The tape and the aluminum splint were removed, leaving the leg covered only with gauze except near the foot where tape was also applied. The brace was then applied and secured in place with two leather straps. When the cow stood, the leg and foot remained in the normal position. The wound healed without complications, and the sutures were removed from the skin after three weeks. The brace was removed 5 weeks after initial application, and the cow walked well except for a slight limp which was noticeable when the cow walked but not when she ran.

Post operative limping gait from mild to intense was common in all the groups of animals till the 21st post operative days and in group II, one animal that was sacrificed on the 30th day exhibited slight lameness. Williams and Evans (1953) reported a successful treatment in a 5 year old dairy cow with a deep, unexplained wound severing both the superficial and deep flexor tendons about ten inches below the point of hock. An iron bar support was fashioned to hold the limb in a normal position. The vertical bar to be strapped on the volar surface of the limb, was welded to a horizontal plate turned up in front and on the sides like a boot to enclose the foot. The animal was cast and an attempt was made to suture the ends of the tendons. But the sutures were torn out with the slightest movement

The wound was then dressed and the support strapped on. The wound healed in 4 weeks and the appliances were removed in 6 weeks. There was considerable sagging of the fetlock at that time, an elastoplast bandage was applied in a figure of 8 and in 3 months the leg assumed a fairly normal position. During the period of three months from the time of injury, the cow walked with only a slight limp, which soon disappeared. Belenger ^e et al. (1965) reported that nylon suture in the repair of ruptured achilles tendon was used alongwith autogenous skin and the part was immobilized with plaster cast for 3 weeks. Weight bearing began at 5 to 6 weeks after range of motion regained.

In the present studies, the Post operative adhesion following tendon repair was a common complication met with different techniques. Adhesions were present in all the animals sutured by Koch-Mason and Bunnell - Mayer double cross technique using silk (3-0) and stainless steel wire (35 mm) respectively till they were sacrificed on the 21st Post-Operative days but by Mattress Technique using cotton, no adhesion was marked after post operative period of 21st day. Hickman (1964) stated that the connective tissue will be slowly replaced by specific tendon tissues (Collagen

(Collagen fibres) in time , though may be never completely ; Complete rest is to be avoided as it would aid the formation of adhesions . Butler (1965) have reported that penetration of fibroblasts from surrounding tissues are responsible to cause adhesions.

Post -operative formation of scar were also common in all the animals sutured with different techniques till sacrificed on the 21st day . Reed(1962) has reported that the scar tissue formed has insufficient tensile strength to withstand the stresses of heavy training and racing in horses , in which chances of recurring injury are great .

Elynn (1965) has reported the gross finding of the tendon suture. The tendon ends which were sutured showed fusion by a fibrous bridge across the gap after two weeks . After the third week, the gap is bridged by tough fibrous tissue. The fibrous sheath which is less oedematous than Previously, extends from stump to stump. But after four weeks the healed tendon appears grossly to glide beneath a thin fibrous sheath.

The microscopical examination of the sutured part revealed nearly the same histological findings from 10th to 30th Post -Operative days using different suturing

Techniques and the suture materials. The amount of of Collagen fibres were increased relatively more from 10th day onward . The collagen fibres regularly arranged in longitudinal direction in about a month after the tendon suture . But just opposite to it the number of fibroblasts were found lesser towards the end of a month. Flynn (1965) have reported the similar findings of tendon -suture at various intervals. Accordingly after two weeks , the stumps show a marked advancement in fibroblastic and vascular proliferation and decrease in other cellular reaction. After the third week , the stumps contain fibroblasts which are more mature and having more Collagen fibres. The fibroblasts are arranged longitudinally in line with the pull of the tendon. In about a month interval , there is more collagen fibres .

.....
.....
.....

S U M M A R Y

S U M M A R Y.

In the present study an attempt has been made to evaluate the value of different techniques for suturing the tendon-ends at various interval in bovines, taking buffalo-calves as the type species.

Three techniques namely , Koch- Mason technique of tendons suture, Bunnell - Mayer double cross technique of tendon suture, and Mattress technique of tendon suture have been studied on twelve buffalo-calves.

Koch- Mason technique of tendon suture in group I employing braided Silk- (3-0) has been studied on four buffalo calves . Bunnell- Mayer double cross technique of tendon suture in group II using stainless steel wire (35 mm) was studied on four buffalo -calves. And Mattress technique in group III employing cotton mercerized has been studied on four buffalo- calves . In each technique, the animals were sacrificed respectively for 30th ,21st, 14th and 10th days .

The success of the tendon suture was assessed from the clinical observations made Post -Operatively up to a period of thirty days, macroscopic and microscopic appearances .

In Koch - Mason technique of tendon suture employing braided silk (3-0) , clinical function was found satisfactory in one animal (25 %) observed post -operatively for thirty days and in the remaining three animals, (75 %) limping gait was present Post-operatively up to the twenty first days. Other post - Operatively/ complication associated was Swelling of the part beyond the wrapped plaster cast in only one animal (25 %) .

The gross examination of the tendon ends revealed perfect continuity in three animals (75 %) except in one animal (25 %) sacrificed on 10th Post-Operative day, in which the tendon sutures were found broken. Adhesion of tendons with tendon sheaths were present in three animals (75 %) and in one animal observed Post-operatively for thirty days, was not marked by adhesion . Scar from distinct to obscure was present in two animal (50 %) , in one animal observed for thirty days, no scar was visible.

Microscopically, the amount of Collagen fibres increased with Post-Operative extension period. At one month , the Collagen fibres reached nearly normal direction. The number of fibroblasts relatively decreased towards the end of a month. The infiltration of

lymphocytes between the dense collagen fibres were more or less relatively lower at one month .

In Bunnell- Mayer double cross technique of tendon suture employing stainless steel wire (35 -mm), not a single animal restored normal function. The limping gait was marked in all the animals (100 %) other Post- Operative complication associated with Swelling at the part beyond the wrapped Plaster cast, was present in two animals (50 %) .

The gross examination of the tendon ends established perfect continuity in all animals (100 %) Adhesion of tendons with tendon-sheaths was present in three animals (75 %) except in only one animal observed Post-Operatively for thirty days did not show adhesion. Scar from distinct to an ill- developed was present in three animals (75 %) except in one animal sacrificed on 30th Post -Operative days.

The microscopical examination of healed tendon showed relatively a-increase in the amount of Collagen fibres and were regularly arranged in about a month post-Operative period . More or less the fibroblasts and lymphocytes were reduced in number with increasing the Post operative intervals.

In Mattress technique of tendon Sutures employing cotton mercerized , clinical function was found satisfactory in one animal (25 %) observed post-operatively for thirty days and in the remaining three animals (75 %) limping gait was present post-operatively up to the twenty first days. No other post Operative complication was encountered in any animal.

The gross examination of the tendon-ends revealed perfect continuity in three animals (75 %) except in one animal, tendon suture was found broken (25 %) Adhesion was present in two animals (50 %) sacrificed on 14th and 10th Post-operative day, Scar from distinct to obscure was present in all animals (75 %) except in one animal sacrificed on thirty days post- operatively.

Microscopically , the amount of Collagan fibres relatively increased with the increase of Post- Operative intervals . The collagen fibres attained regular longitudinal arrangements in about one month . But consequently, the lymphocytes and fibroblasts reduced more or less with increasing the post operative period.

A new approach on bovine tendon suturing, employing different techniques has been tried in this

experiment and nearly more or less the similar findings appeared in all the animals . But Mattress technique using mercerized cotton has been edged slightly over the other two techniques in respect to the popular availability of suturing material and easier technique which emphasized its needs under field condition.

.....
.....
.....

TABLE NO. - 1

XK

ANIMAL NO	TECHNIQUE OF TENDON SUTURING .	SUTURING MATERIAL
1 .	Koch- Mason	Silk (3-0)
2 .	Koch - Mason	Silk (3-0)
3 .	Koch - Mason	Silk (3-0)
4 .	Koch - Mason	Silk (3-0)
5.	Bunnell- Mayer Double - Cross	Stainless Steel Wire (35 mm)
6 .	Bunnell- Mayer Double - Cross	Stainless Steel Wire (35 m-m)
7.	Mattress	Cotton (Mercerised)
8.	Mattress	Cotton (Mercerised)
9.	Mattress	Cotton (Mercerised)
10.	Bunnell- Mayer Double Cross.	Stainless Steel Wire (35 mm)
11.	Bunnell- Mayer Double Cross .	Stainless Steel Wire (35 mm)
12	Mattress	Cotton (Mercerised)

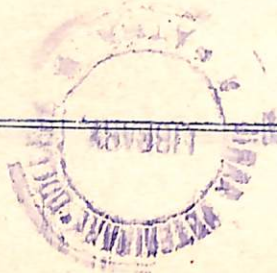


TABLE NO - 2

ANIMAL NO.	GROUP	APPROX . BODY WEIGHT IN LBS	OBSERVATION PERIOD IN DAYS
1.	Group I.	210	30 days.
2.	Group I.	232	21 days.
3.	Group I	236	14 days.
4.	Group I	255	10 days.
5.	Group II	285	30 days.
6.	Group II.	270	21 days.
7.	Group. III.	206	30 days.
8.	Group. III.	240	21 days.
9.	Group. III.	226	14 days.
10	Group . II.	290	14 days.
11.	Group . II.	262	10 days.
12.	Group . III.	218	10 days.

T A B L E N O -3

AVERAGE TEMPERATURE, PULSE AND RESPIRATION OF DIFFERENT GROUPS

(PREOPERATIVE AND POST- OPERATIVE RECORD)

Days. Time .	GROUP I			GROUP II			GROUP III		
	Temp In F.	pulse/ min.	Resp/ min.	Temp in F.	Pulse/ min.	Resp/ min.	Temp in F.	Pulse/ min.	Resp/ min.
1st M	100.2	46	11	100.4	41	12	99.6	38	12
E	100.4	48	10	101.0	45	12	100.0	46	11
2nd M	100.6	44	10	100.4	43	11	100.0	41	10
E	100.8	58	12	102.8	56	15	102.6	56	14
3rd M	100.8	56	11	102.0	54	16	102.2	55	15
E	101.8	57	13	102.4	53	18	102.4	53	16.
4th M	100.6	52	12	101.4	51	17	101.6	49	14
E	101.6	51	10	101.8	47	17	102.2	51	15
5th M	100.4	50	11	101.4	43	15	101.2	50	15.
E	101.2.	52	10	101.6	46	17	101.8	52	15.
6th M	100.6	46	11	101.0	47	16	100.6	43	13.
E	101.4	48	11	101.2	44	16	101.6	48	14.
7th M	100.4	45	10	100.8.	40	16	100.6	45	13.
E	101.0	47	11	101.6.	42	18	101.0	46	13.
8th M	100.0	41	10	100.4.	43	17.	100.4.	41	14.
E	100.4	43	11	101.4.	40	17	100.8	42	13.

M-Morning

E- Evening.

1st day M.&.E.- Pre-Operative Record.
The above figures are obtained from the daily
recordings noted Pre-and Post-Operatively till the
8th day.

T A B L E N O - 4

TOTAL AND DIFFERENTIAL LEUCOCYTIC COUNT OF THE EXPERIMENTAL ANIMALS.

GROUP No.	Buff. Calif. No.	Total Count.	R.B.C in Million.	W.B.C in Thousand	Differential Count.				
					Lymphocytes.	Monocytes.	Neutrophils.	Eosinophils.	Basophils.
GROUP I.	1.	5.6	10014	67	4	26	3	Nil	
	2	4.9	8692	68	3	26	3	Nil	
	3	4.4	9520	71	4	23	2	Nil	
	4	5.1	10135	77	4	18	1	Nil	
GROUP II.	5	7.8	12338	72	5	21	2	Nil.	
	6	6.6	8920	65	4	29	2	Nil.	
	10	7.2	9280	68	7	23	2	Nil	
	11	5.7	7800	72	4	22	2	Nil	
GROUP III.	7	4.3	9615	66	4	30	Nil	Nil	
	8	5.1	10225	58	5	32	4	1	
	9	5.3	9468	61	6	32	1	Nil.	
	12	5.6	11036	67	3	28	1	1	

T A B L E N O - 5

SUMMARY OF HAEMATOLOGICAL STUDIES

Group No.	Average of Total count.			Average of Differential Count.				
	R.B.C.in Million/ Cmm	W.B.C. in sand / C m.m	Thou- C m.m	Lympho cytes %	Mono Cytes %	Neutro phil %	Eosino phil. %	Basophil %
I.	5.0	9590		71	4	23	2	N11 .
II.	6.82	9584		69	5	24	2	N11
III.	5.07	10086		63	4	30	2	1

T A B L E N O - 6 (1)

SUMMARY OF THE CLINICAL FUNCTION DURING

POST - OPERATIVE PERIOD .

Animal No.	Technique Of Suturing.	Observation Period.	Clinical Function.
1.	Koch- Mason Technique.	30 days.	No untoward Symptoms except in gait were observed during the Post Operative management of the animal. The intense limping was observed upto the Second Post -Operative Week. From the beginning of third week, the limping movement of the animal gradually decreased and after 20th Post -Operative days , there was slight limpness and disappeared from 28th days.
2.	Koach- Mason Technique.	21 days.	The Swelling of the part beyond wrapped Plaster cast was evident . The limping movement was marked till the animal was sacrificed.
3.	Koach- Mason Technique .	14 days.	No untoward Sympton was encountered except that of limping gait, which remained throughout the Post -Operative period.
4.	Koch- Mason Technique.	10 days.	The limping gait was marked through out the Post- Operative Period.

T A B L E - N O 6 - (11)

SUMMARY OF THE CLINICAL FUNCTION DURING
POST- OPERATIVE PERIOD .

Animal No.	Technique Of Suturing.	Observation Period .	Clinical Function.
5.	Bunnell Mayer double Cross Technique.	30 days.	No untoward symptom except that limping gait was observed. The limping gait gradually declined and remained slight when the animal was sacrificed.
6.	Bunnell Mayer double cross technique.	21 days .	The Part beyond the wrapped plaster cast was Swollen. The gait of the animal was limping and continued throughout the Post- Operative Period.
10.	Bunnell. Mayer double cross Technique.	14 days.	The limping Syndrome of the animal was continued through out this period .
11.	Bunnell- Mayer double cross Techni- que.	10 days.	Swelling of Part beyond the wrapped Plaster cost was pronounced in the animal for seven days and the gait remained limp throughout the Post -Operative Period.

TABLE NO - 6 (111)

SUMMARY OF THE CLINICAL FUNCTION DURING
POST - OPERATIVE PERIOD

Animal No.	Technique Of Suturing	Observation Period.	Clinical Function.
7.	Mattress Technique.	30 days.	The animal did not show any Post-Operative Complication other than limping gait .The limping gait with varying degree was present till the third week but from in the fourth week, the lameness disappeared .
8.	Mattress Technique.	21 days.	No untoward sympton was noticed other than limpy gait.A mild degree of limpness was present when the animal was sacrificed.
9.	Mattress Technique.	14 days.	The animal did not show any compli-cation other than limping gait. The limpness was present through-out this period.
12.	Mattress Technique.	10 days.	The animal did not show any comp-lication except that of limpy gait which was marked through out the Post-Operative period .

TABLE NO -7 (1)

SUMMARY OF GROSS CHANGES .

Animal No.	Technique of Suturing .	Observation Period .	Gross - Changes .
1.	Koch-Mason Technique.	30 days	Tendon appeared to glide within within the tendon-Sheath.Tendon Showed perfect healing .Scar was invisible. No adhesion was present.
2.	Koch Mason Technique .	21 days	Tendon -ends regained Continuity but marked by distinct Scar. Adhesion was present around the site of suturing .
3.	Koch- Mason Technique.	14 days.	Tendon-ends established Continuity and marked by distinct Scar. The tendon- Sheath was oedematous and formed marked adhesion.
4.	Koch- Mason Technique.	10 days.	Sutures of the tendon- Sheath and tendon itself was found broken.Marked adhesions were noticed.

TABLE NO - 7 (11)

SUMMARY OF GROSS - CHANGES

Animal No.	Technique Of Suturing.	Observation Period.	Gross - Changes.
5.	Bunnell Mayer double Cross Technique.	30 days.	Tendon-ends regained Perfect Continuity without leaving any Scar. Adhesion was not marked with the tendon- sheath.
6.	Bunnell Mayer double Cross technique.	21 days.	Tendon- ends showed union with the presence of an ill-developed Scar . Adhesion was also present around the suture site.
10	Bunnell Mayer double cross Technique.	14 days.	Tendon ends appeared to fuse and an ill developed Scar was present. Adhesion was well. Marked around the site of suture.
11.	Bunnell Mayer double cross technique .	10 days.	The tendon sheath was more Oedem -yous and its sutures disrupted. Tendon ends fused but distinct gap was visible.

TABLE NO - 7 (111)

SUMMARY OF GROSS CHANGES

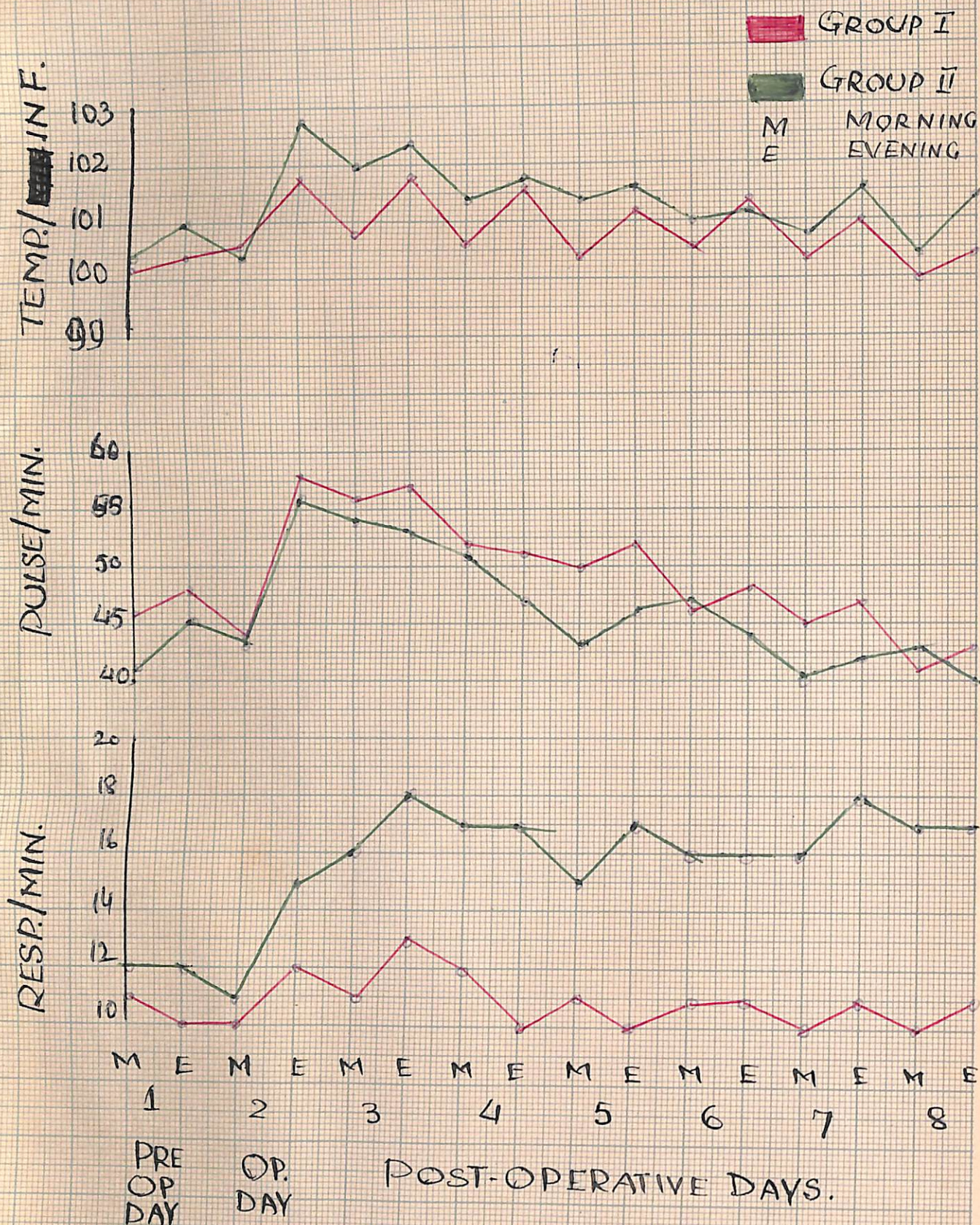
Animal No.	Technique Of Suturing .	Observation Period.	Gross- Changes.
7.	Mattress Technique.	30 days.	The tendon appeared to move freely within the tendon-sheath as there was no adhesion in it. The tendon-ends regained perfect continuity although the Scar was not distinct.
8.	Mattress technique .	21 days.	Tendon-ends established Perfect continuity and an iml developed Scar was visible. There was no adhesion around the site of suture.
9.	Mattress Technique .	14 days .	Tendon-ends fused and well marked adhesion was present around the site of Suture . A small Scar was present at the site of fusion.
12.	Mattress Techniques.	10 days.	Tendon sheath was more Oedematous. Tendon sutures were broken on one side while the other side fused and was marked by distinct Scar. Adhesion was well -marked.

TABLE NO - 8

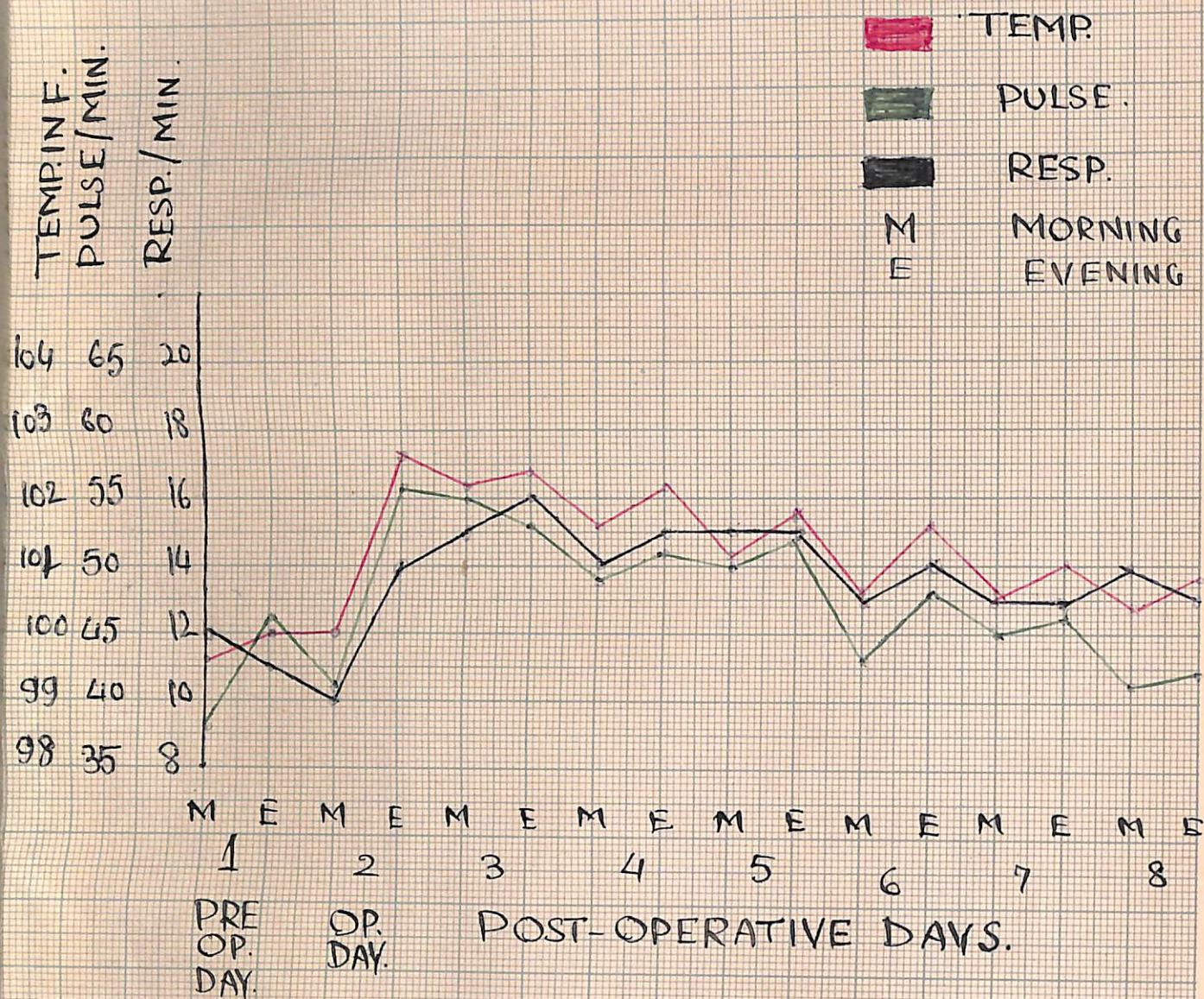
SUMMARY OF THE TOTAL GROSS - RESULTS

Techniques Of Tendon Suturing .	Suturing Material.	Number Of animals	Limping Gait	Other Compl - cation.	Healing of Tendon- ends.	Adhesion. Of Tendon- Suture.	Breakage Scar formation
KOCH- MASON TECHNIQUE .	Silk. (3-0)	4	75 %	25 %	75 %	75 %	50 %
BUNNELL -MAYER DOUBLE CROSS TECHNIQUE.	Stain - lessSteel wire (35 mm)	4	100 %	50 %	100 %	Nil.	75 %
MATTRESS TECHNIQUE.	Cotton 4 Merceri- zed.		75 %	Nil	75%	50%	75 %

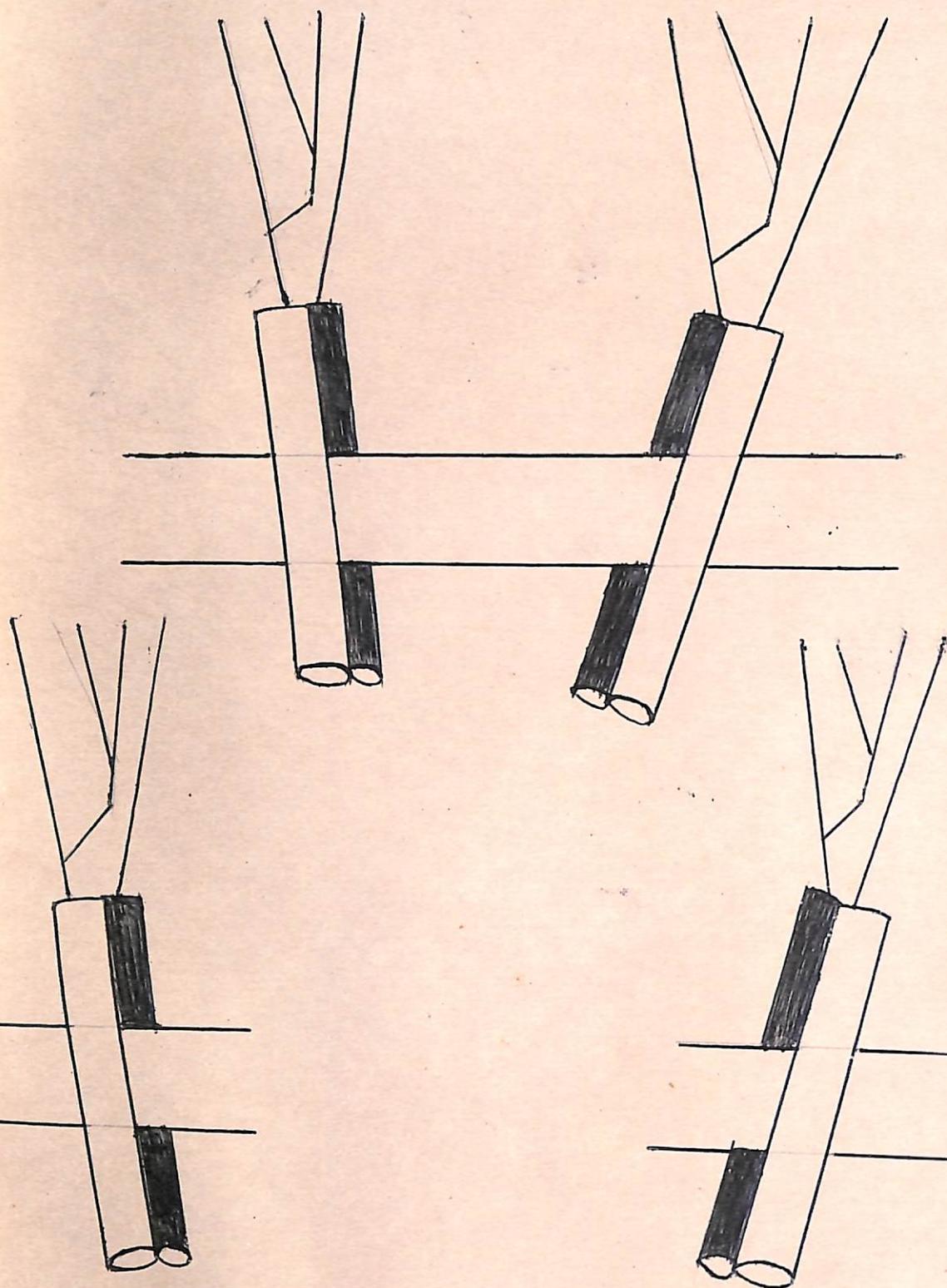
AVERAGE TEMPERATURE, PULSE AND RESPIRATION.



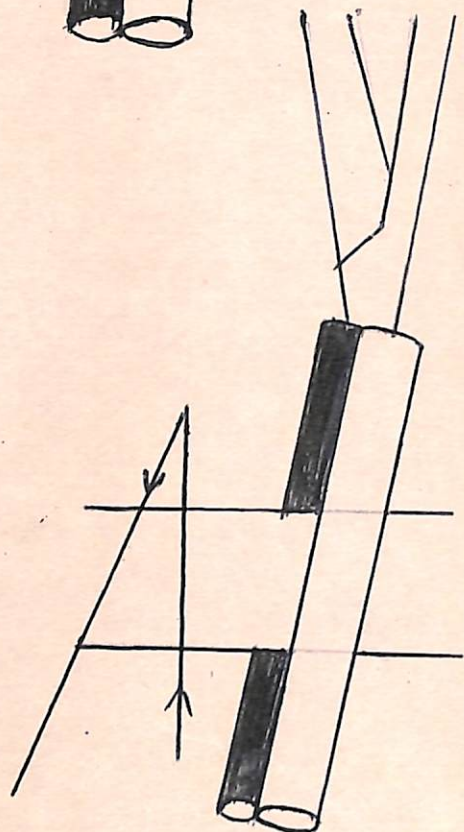
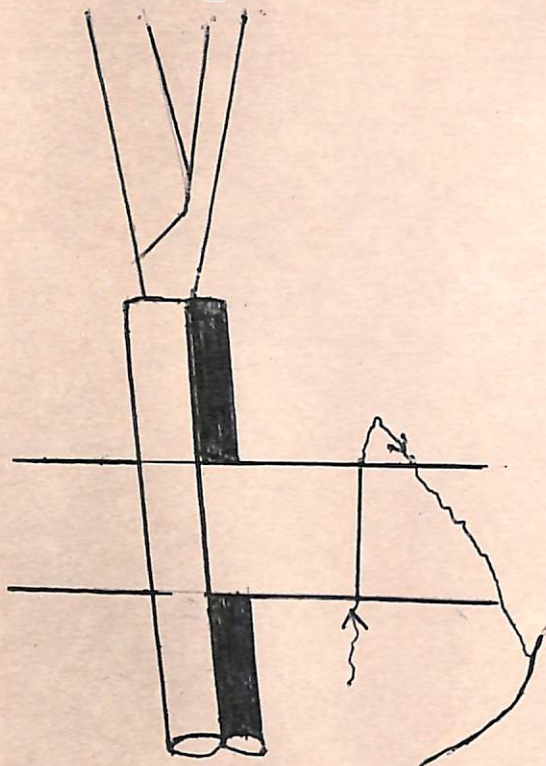
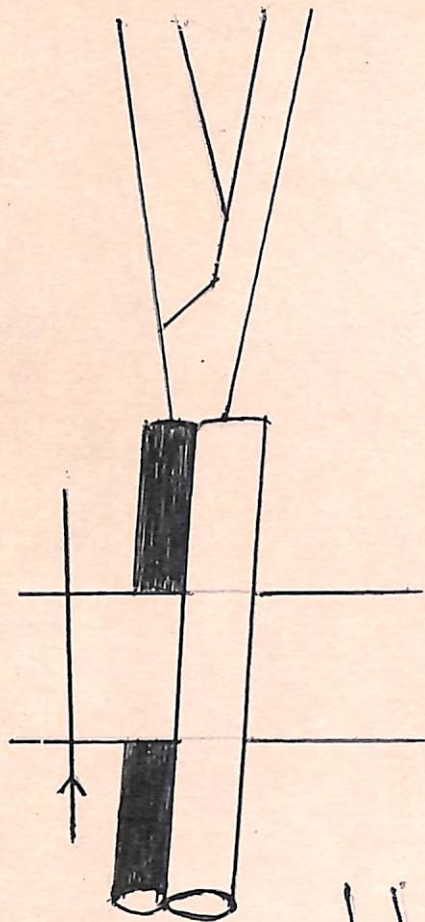
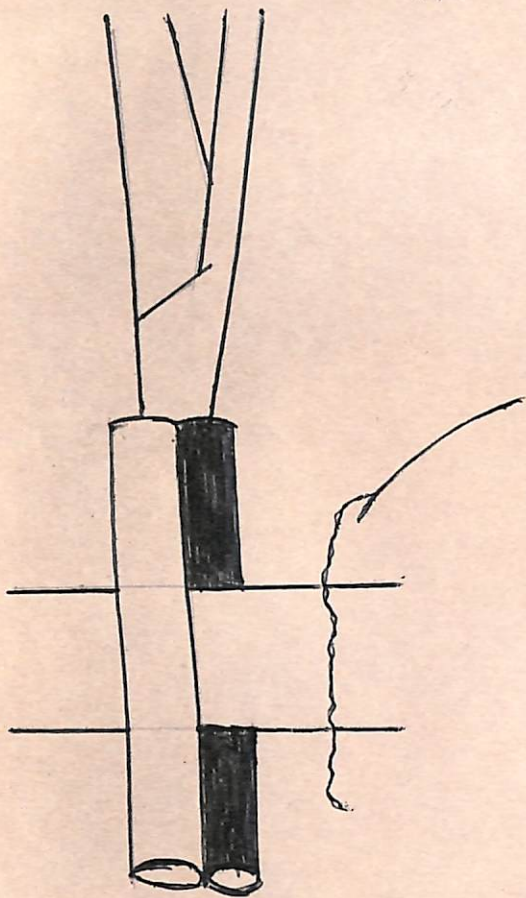
AVERAGE TEMPERATURE, PULSE AND RESPIRATION.



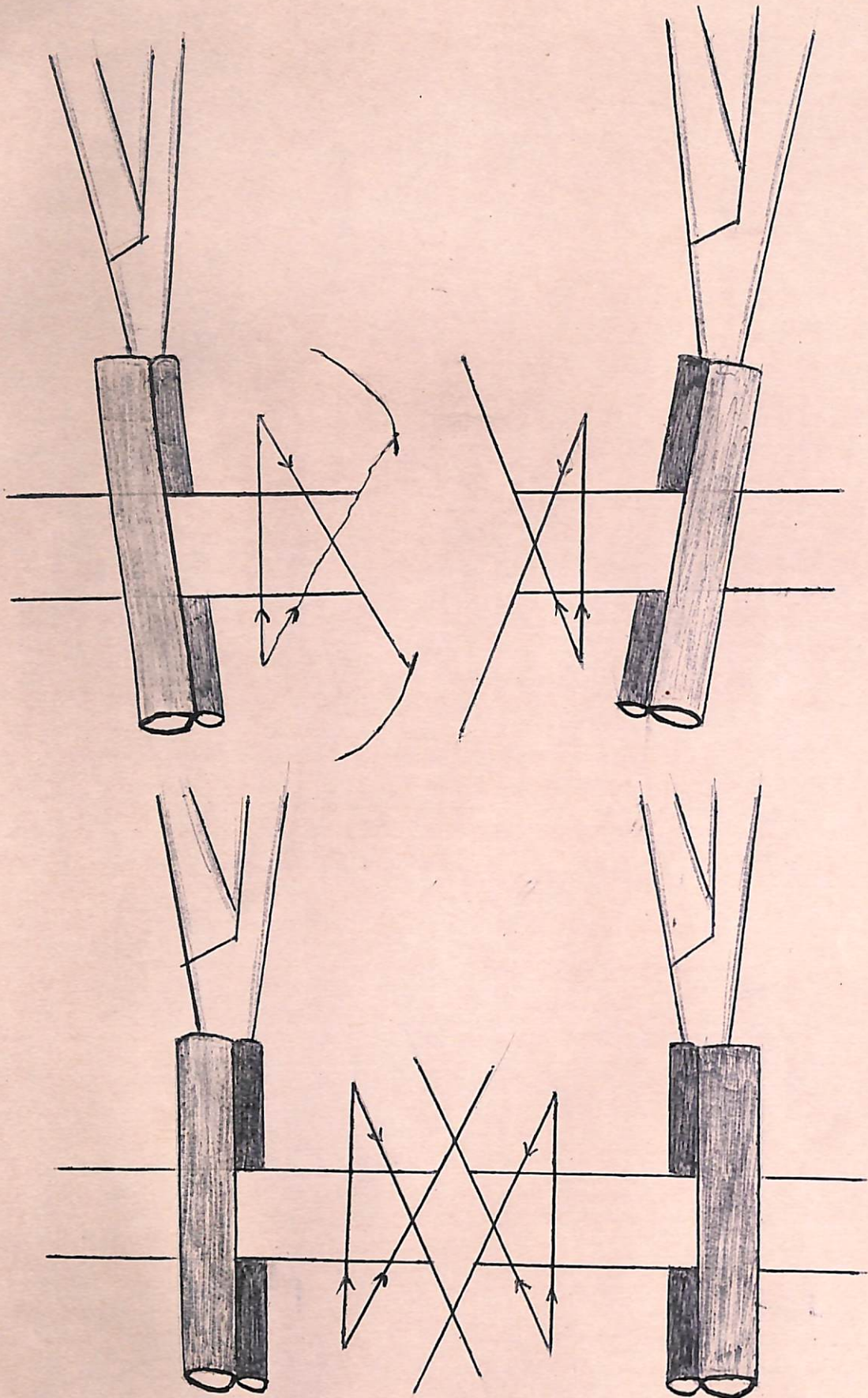
TENOTOMY PROCEDURE



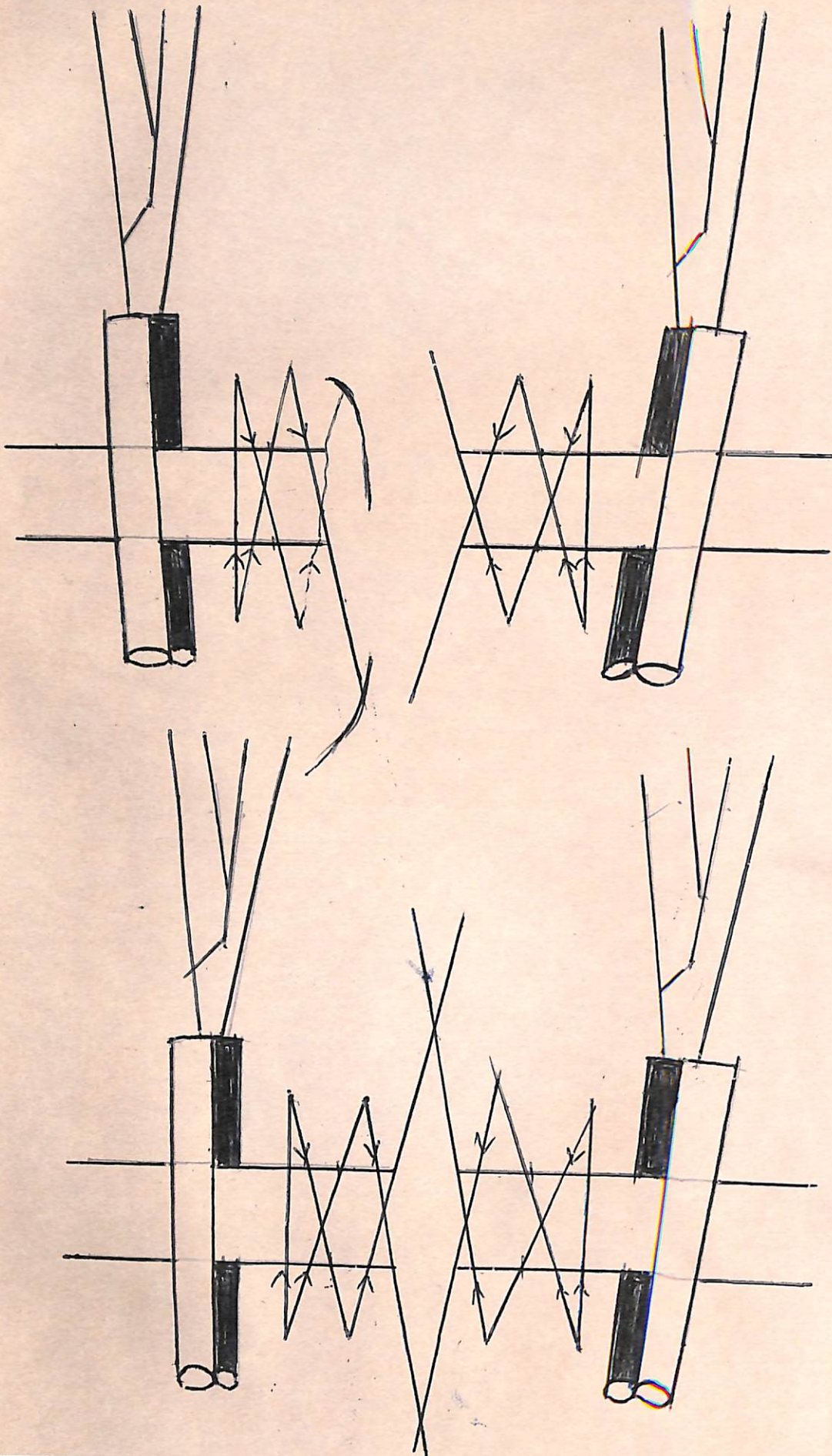
STEP IN KOCH-MASON TECHNIQUE



KOCH-MASON TECHNIQUE



BUNNELL-MAYER DOUBLE CROSS TECHNIQUE.






Photo No .1:- Photograph showing exposure
of Superficial flexor tendon,
elevated with the help of tēna
-culum .



Photo No.2 :- Photograph showing the two
ends of the tendon.

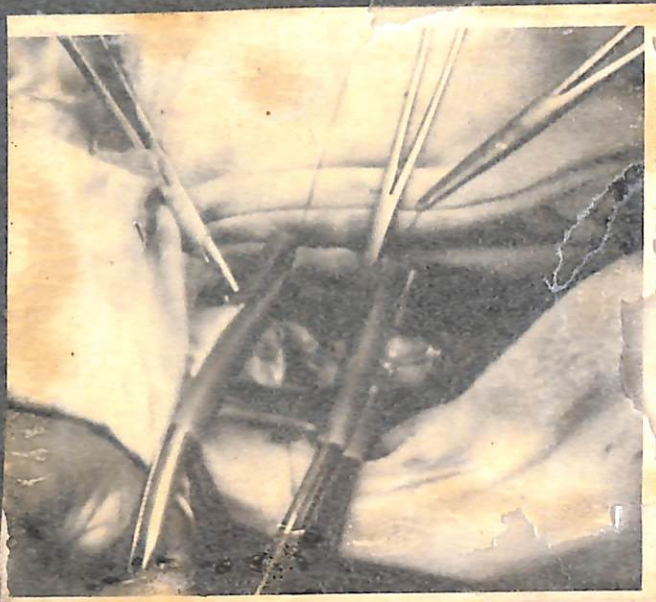


Photo No. 3 :- Photograph showing suturing technique of tendon-ends by Koch Mason, Four ends of Silk Sutures grasped by artery forceps .

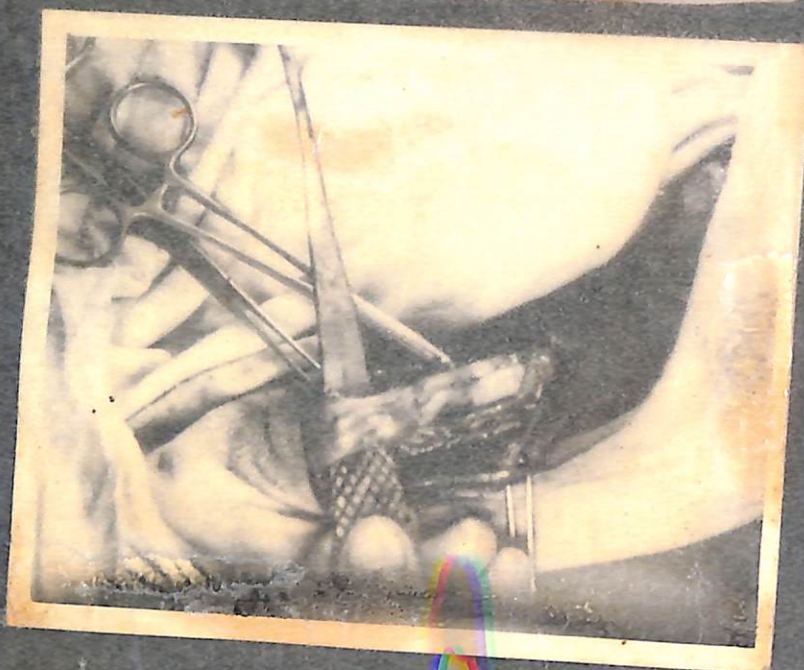


Photo No. 4 Photograph showing, Sutured of the tendon -ends.



Photo No.5 :- Showing Closure of the Skin
incision after suture of the
tendon-ends.




Photo No.6 :- Showing standing of the
animal just after Operation.



Photo No.9 :- Photograph showing sutured tendon ends by Bunnell Mayer double cross technique on autopsy.

- (5) Tendon after 30 days , showing perfect continuity of tendon-ends.
- (6) Tendon after 21 days , showing union of the tendon -ends.



Photo No. 10 :- Photograph showing sutured tendon by Bunnell- Mayer double cross technique on autopsy.

- (10) Tendon after 14 days , showing regained continuity of the tendon ends.
- (11) Tendon after 10 days , showing Union of the tendon ends and well-marked adhesion.



Photo No. 11 :- Photograph showing sutured tendon ends by Mattress technique on autopsy.

- (7) Tendon after 30 days , Showing perfect continuity of the tendon ends and embedded suture material.
- (8) Tendon after 21 days, showing union of the tendon ends.



Photo No. 12 :- Photograph showing sutured tendon by Mattress Technique on autopsy.

- (9) Tendon after 14 days, showing union of the tendon ends .
- (12) Tendon after 20 days , showing fusion of the tendon ends on one side with distinct scar but on other side the suture of tendon broken.



Photo.No. 13:- Longitudinal section of tendon through the sutured part by Koch - Mason Technique after 30 days from operation.



Photo.No. 14:- Longitudinal section of tendon through the sutured part by Koch-Mason Technique after 21 days from the operation.



Photo.No.15:- Longitudinal Section of tendon through the sutured part by Koch-Mason Technique after 21 days from operation.



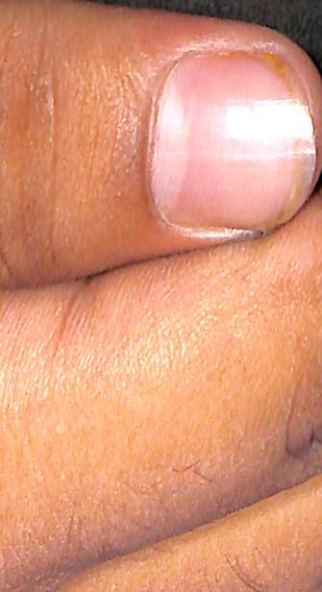Photo.NO.17:- Longitudinal Section of tendon through the sutured part by Mattress Technique after 21 days from the operation.



Photo.NO.16:- Longitudinal Section of tendon through the sutured part by Mattress Technique after 30 days from the operation.



Photo.NO.18:- Longitudinal Section of tendon through the sutured part by Mattress Technique after 14 days from the operation.



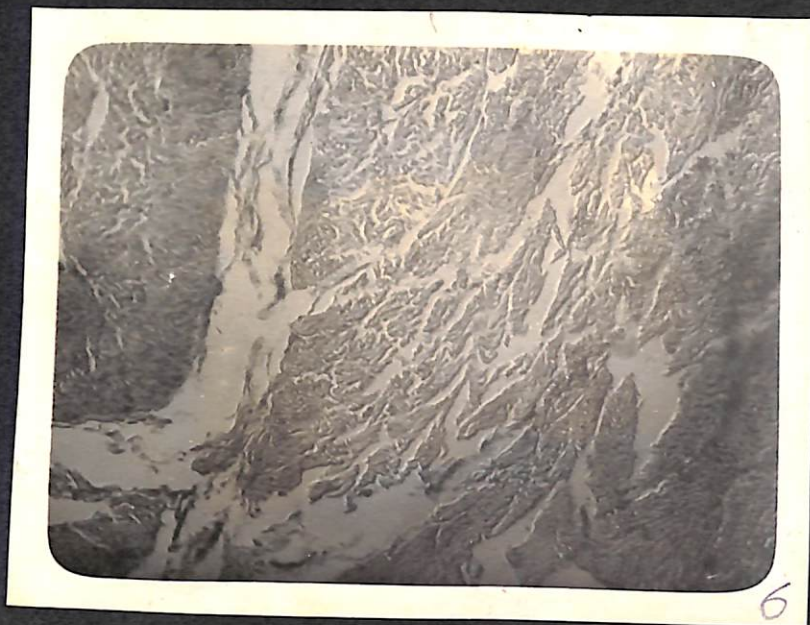


Photo.NO.20:- Section oftendon through the sutured part by Bunnell-Mayer Technique after 21 days from the operation.



Photo.NO.19:- Section of tendon through the sutured part by Bunnell-Mayer Technique after 30 days from the operation.



REFERENCES

REFERENCES

✓ Altmann, K .(1963)

" The structure and Mechanical stressing of microscopic muscle tendons "

Z. Anat. Entwickl ; 124/1 : 57- 69

Quoted from Excerpta Medica(1965) ; 19 :307.

✓ Batson, Maurice.S. (1963)

" Tenorrhaphy in a cow "

J . A .V . M. A .; 142 : 258 - 259 .

✓ Belenger, M.; Vander Elst , E and Toussaint, J.P. (1965).

✓ "Use of autogenous Skin in the repair of ruptured Achilles Tendon "

Acta . Orthop . belg ; 31 : 454

Quoted from Surg. Gynec. & obst (1966);122:1394.

✓ Boyes, Joseph, H.(1965) .

✓ " Problems of Tendon surgery "

AM . J. Surg .; 109: 269-271.

Bruner, Julian M. (1967)

" The zig zag volar digital incision for flexor tendon surgery "

Plast . Reconstr. Surg.; 40:571.

Quoted from Surg.Gynec .& obst .(1968),127:702

Buter, Hugh C. (1965).

" Tendons, Muscles and Fascia " .

Canine Surgery edited by Archibald , J.;

First Archibld edition ;

American Veterinary Publication INC.

Carnaghan , R.B.A. and Hanson , B.S. (1958)

" Rupture of the gastrocnemius Tendon in Fowls".

Brit .Vet.J.; 114 : 360

Quoted from Vet . Bull. (1959) ; 29:269

Carter, Sylvester J. and Mersheimer, Walter L. (1966)

" Deferred Primary Tendon repair "

Annals of Surgery ; 164 : 913 - 916.

DA Costa, John Chalmers (1908) .

" Modern surgery "

W.N. Saunders company , Philadelphia & London.

Entin, Martin A.(1965)

" Flexor Tendon Repair And Grafting in children ".

AM. J. Surg.; 109 : 287-293

Elynn, J. Edward (1965) .

" Healing of Tendon wounds ".

Am. J. Surg.; 109: 315-324

A.M

Griffiths, J.C. (1965)

" Tendon injuries around the ankle "

J. Bone Surg. ; 47- B : 686

Quoted from surg.Gynec . & obst .(1966) ;123:1180

Hernandez, Armando ; Velasco, Francisco ; Rivas, Arcella and
Preciado, Alicia (1967)

✓
" Preliminary report on early mobilization for
the rehabilitation of flexor tendons "

Plast. and Reconstr. Surg. ; 40:345 .

Quoted from surg . gynec. & Obst. (1968;126:946 .

Hickman, John (1964)

" Veterinary Orthopaedics "

Oliver & Boyd, Edinburgh and London .

Hipp, E. and Weigert, M. (1966) .

" Sub-cutaneous rupture of the Tibialis
Anterior tendon ."

Zschr. Orthop .; 201: 398

Quoted from surg.Gynec & obst.(1967);124:696

Hage, J. and Dupuis, C.C.(1965.)

✓
" The intriguing fate of Tendon grafts in
small childrens hands and their results "

Brit. J.Plast. Surg. 18 : 341.

Quoted from Surg.Gynec. & obst.(1966) ;122:1394

✓
Joshua, Joan. O.(1953) .

" Tendon repair in cats "

Vet. Rec. ; 65 : 174

Quoted from J.A.V.M.A.(1953);122:484

Langenskiold .A. (1967) .

" Chronic non specific Tenosynovitis of
the Tibialis Posterior Tendon ".

Acta . Orthop. scand.; 38: 301

Quoted from surg. Gynec .& Obst.(1968);126:946.

Lang,J.and .Viernstein, K.(1966)

" Degeneration, rupture and regeneration
of the Achilles Tendon " .

Zschr. Orthop. ; 101 : 160

Quoted from surg.Gynec.& Obst.(1967); 124:466.

Lewis, G.Kenneth and Manelish, Joseph(1965)

" Spontaneous Tendon Rupture."

Indust .M.; 34: 417

Quoted from Surg.Gynec.& Obst. (1965);121:1200

Lynn, Theodore A. (1966) .

" Repair of the torn achilles Tendon

using the plantaris tendon as a rein-
forcing membrane ." J.Bone.Surg;48-A:268

Quoted from Surg. Gynec.& obst.(1966);123:946

Melmed, B.P. (1965) .

" Spontaneous bilateral rupture of the Calcaneal tendon during steroid therapy ".

J. Bone Surg.; 47 -B : 104

Quoted from surg. Gynec.& obst .(1965);122:214

Millesi, H. (1965)

✓ " On the Technique of tendon grafting . "

Langenbecks Arch, Klin. Chir. ; 309 : 40

(Quoted from surg.Gynec.& Obst(1965) ; 126:1169

McKenzie, A.R. (1967).

" An Experimental Multiple.Barbed suture for the Long Flexor Tendons of the Palm and Finger ".

J.Bone Surg.49-B: 440

Quoted from Surg.Gynec.& Obst.(1968) ;126:1169

Moberg, Erik (1965)

✓ " Tendon Grafting and Tendon suture in Rheumatoid antheritis "

Am. J. Surg .; 109 : 375 - 376

Morcos, M.B. (1962)

" Tendon wound Healing under the influence of several drugs "

✓ Med.Veeartsenijschod Ghent ;5, No.6,PP.107.

Quoted from Vet . Bull.(1962) ; 32: 557

Mc Farlane, R.M. ; Lamon, R. and Jarvis, G. (1968)

✓
" Flexer Tendon injuries within the finger ; a study of the results of Tendon suture And Tendon Graft " .

J. Trauma ; 8 : 987

Quoted from Surg. Gynec.& obst (1969); 128: 920.

Miller, R.L. ; Paisley , P.B. and Pritchard , J.J. (1963)

" Tendon repair ."

J. Anat ; 97 : 304

Myers, Hu. C. , Myers, Robert. L. and Crawford, J. Richard (1964)

" " Tendon repair using cohesive steel reinforcement " .

Am. Surgeon . ; 30 : 668

Quoted from Surg. Gynec.& Obst. (1965), 120: 449.

Myers, Victor. S. and Lundvall, Richard .L. (1966)

" Corrective trimming for weak flexor Tendons in a colt ."

J.A.V.M.A.; 148: 1523 - 1524.

Morel- Fabio , D and Ducourtieux, J.L. (1964)

" Surgery of Flexor Tendons " .

J. Chir .; 88 : 389

Quoted from surg. Gynec.& obst (1965) ; 20: 1162

Nilsson, Gunnar (1969)

" Surgical treatment of chronic tendinitis
in the horse % .

J.A.V.M.A. , 155 : 920-.

Padgett , Earl. Calvin and Stephenson, Kathryn Lyle (1948)

" Plastic and Reconstructive Surgery ."

Published by Charles C, Thomas ; Spring field,
Illinois, U.S.A.

Beacock , Erle E . (1965) .

✓
" Biological principles in the healing of
long tendons ".

Jr. Surg. Clin. N. America , 45 : 461.

Quoted from surg.Gynec.& obst.(1965);121:1409.

Pulvertaft, R. Guy (1965) .

" Suture materials and Tendon Junctures ".

Am .J. Surg. ; 109 : 345 - 352.

Reed , W.O. (1962) .

" Bowed Tendons heal slowly in horses ".

J.A.V.M.A ; 141 : 1258

Quoted from J a A.V.M.A. (1966) ; 148:390

Robinson, R.C. (1968) .

" The use of sclerosing agents in Tendon
repair of Race horses ."

Aust. Vet. J. ; 44 : 200 - 202

Sealy, will Camp (1946) .

" Tendon injuries of the Hand ."

Surgical treatment of soft tissue edited
by Bancroft , Frederic W. and Humphreys
George H. ; J.B.Lippincott Company.

Schauwecker, F. ; Weller; S. and Lenz, B. (1967) .

" The pathogenesis of Achilles Tendon
Rupture"-. .

Dieut. Med. Wschr. ; 39 : 1758

Quoted from surg. Gynec. & obst.(1968);126/
:1169 .

Stenstrom , Sten (1967) .

" A new method for the distal unastomosis
in Flexor Tendon Grafting. "

Scand .J. Plastic & Reconstr. Surg.1:64

Quoted fromsurg.Gynec.& obst.(1968);126:946

Solonen, Kauko A (1967) .

" Experiences in reconstruction of Flexor tendons of the fingers ; Evaluation of the Series, Method, and Results ."

Ann . Chir.gyn. fen n ; 56: 180

Quoted from Surg. Gynes . & obst.(1968);126:/1170

Stuart , David (1965) .

" Duration of splinting after repair of Extensor tendons in the hand ."

J.Bone Surg. ; 47 B.:72

Quoted from Surg. Gynec . & Obst.(1966);122:213

Smith , James W. (1965) .

✓ " Blood supply of Tendons "

Am .J. Surg. , 109 : 272 - 276 .

Tubiana , Raoul (1965) .

✓ " Incision And Technics in Tendon Grafing"

Am J. Surg ; 109 : 339-345.

Williams . E.I. and Evans, E.I.Rees (1958) .

✓ " Tendons, severed , super-ficial and deep flexor:Successful treatment in a dairycow."
Vet Rec.; 65 : 189.