

STUDIES ON PATHOLOGY OF EXPERIMENTAL
VITAMIN A DEFICIENCY
IN CHICKS

BIHAR VETERINARY COLLEGE
PATNA.
Acc. No. 2165
Date... .. 23.8.63

P/160

T H E S I S

Submitted to the University of Magadh
in partial fulfilment of the requirements for the
Degree of M.Sc. (Veterinary), in the Faculty of Veterinary
science.

Bihaar Veterinary College,
October, 1962.

P. Das Gupta,
B.Sc., B.V.Sc. & A.H.

C O N T E N T S

ACKNOWLEDGEMENTS.

CHAPTER I.	PAGE.
INTRODUCTION.	1
CHAPTER II.	
REVIEW OF LITERATURE.	5
CHAPTER III.	
MATERIAL AND METHODS.	16
CHAPTER IV.	
RESULTS	28
BIOCHEMICAL STUDIES.	28
HAEMATOLOGICAL STUDIES.	30
CLINICAL SYMPTOMS.	39
PATHOLOGY.	42
CHAPTER V.	
DISCUSSION.	50
CHAPTER VI.	
SUMMARY AND CONCLUSION.	60
REFERENCES.	I
TABLES	8
FIGURES	24
GRAPHS	2

A C K N O W L E D G E M E N T S

The author is greatly indebted to Shri P. B. Kuppuswamy, B.A., G.M.V.C., B.V.Sc., P.G. (Newzealand), M.S. (Missouri), Professor and Head of the Department of Pathology and Bacteriology for suggesting the problem, constant encouragement, helpful advice and guidance.

I am also thankful to Shri S.A. Ahmad, B.Sc.(Ag.), M.R.C.V.S., Principal, Bihar Veterinary College, Patna for the facilities afforded to undertake this work.

My thanks are also due to Shri R. N. Singh, Assistant Professor of Statistics, for helping in statistical analysis of data.

I am also thankful to Shri R. Bhushan, the College Artist for his help in the photographs.

CHAPTER - I

I N T R O D U C T I O N

Vitamins are organic compounds which are required for the normal growth and maintenance of life of animals, including man who as a rule are unable to synthesize these compounds.

The first definite proof of the existence and specific physiological function of vitamin A as an accessory food factor was provided by McCollum and Davis (1915) and by Osborne and Mendel (1915).

Vitamin A occurs only in the lipids of animal origin and it has not been found in plant kingdom. The provitamins A however occur in plants together with chlorophyll. Traces of provitamins A have been found in fat depots of animals.

Fat helps in the absorption of vitamin A. It is better absorbed in unsaturated oil. Presence of bile acids and pancreatic lipase also helps in absorption. Mineral oil is not suitable for absorption.

The conversion of carotene into vitamin A is said to occur in the liver. Wiese, Mehl and Deuel (1947) have shown that in the rat ingested carotene

is converted to vitamin A in the intestinal wall. Recent studies in pig, calf, goat and chicken has also been reported similar conversion by Maynard and Loosli (1956). The intestinal mucosa may be only one of several places in the body where carotene is converted into vitamin A.

Provitamins and vitamin A are removed from the blood by the reticulo-endothelial system as stated by Ahmad (1934). It is stored in the liver in greatest concentration as has been shown by Guilbert and Hart (1934). Sen and Sharma (1936) found that the central portion of the liver contains more vitamin A than the peripheral portion. In liver it remains mainly in the Kupffer and epithelial cells in lipoid droplets.

Vitamin A is stored in the body mainly in oesterified form but some free vitamins are also present. The stored vitamin A oesters are derivatives of series of saturated and unsaturated fatty acids as stated by Gray, Hickman and Brown, (1940).

Vitamin A is essential in poultry for the support of life and growth as stated by Beach (1924) and Seifried (1938). It is also extremely important

at times of stress such as disease or poor nutrition. Mason and Ellison (1935) suggested that vitamin A plays an important part in the protein metabolism of the epithelial cells. Deficiency of this vitamin changes the normal epithelium to stratified keratinizing epithelium as stated by Wolbach and Howe (1925).

This metaplasia in epithelial cells of different organs subjected the animal to infection of respiratory, gastrointestinal and urogenital tract as stated by Seifried (1938), Scorgie (1938) and Seifried et al. (1942). There is also retardation of skeletal growth. Changes in the central nervous system are due to compression of C.N.S. by the retarded bone growth of the cranium and vertebra as observed by Wolbach et al. (1952).

Vitamin A deficiency is more common in poultry particularly in summer months (May & June) when there is acute shortage of green feed. Close confinement of poultry is also an important factor for the deficiency. Deficiency of vitamin A in the diet of poultry significantly increased susceptibility to infection with Ascaridia galli as observed by Pande et al. (1959). Vitamin A has been shown to

increase resistance against some bacterial and viral diseases of poultry as observed by Panda (1962). Increased susceptibility to various diseases and secondary bacterial infections occur due to alteration of mucous membranes.

So it is clear that lack of vitamin A in poultry feeding not only produces vitamin A deficiency but it also predisposes to many other parasitic, bacterial or viral infections.

India has about 100 million of poultry and diagnosis, prevention and control of diseases is essential for the development of poultry industry. One of the important causes of high mortality in young chicks is malnutrition and vitamin A plays an important part amongst the nutritional factors (Iyer, 1948).

It is, therefore, necessary to diagnose vitamin A deficiency in initial stages so that suitable curative and prophylactic measures could be adopted.

Studies have therefore been undertaken particularly to find out means of early diagnosis by haematological picture, clinical appearance, pathological lesion etc., so as to help the poultry owners for early detection of vitamin A deficiency cases.

CHAPTER - II

REVIEW OF LITERATURE.

G E N E R A L:

Wickle (1933), Chichester et.al. (1938) and Berri (1949) observed that in chicks mortality was high due to vitamin A deficiency. Orr et.al. (1934) indicated that the most important role of vitamin A in nutrition lied in its power of preventing the onset of pathological conditions which were the cause of loss of weight. Ackert et.al. (1927), Roach (1943), Pande and Krishnamurty (1959) & Deo and Srivastava (1962) observed that vitamin A deficient chickens were more susceptible to infestation by Ascaridia galli. Nieser (1956) recorded reduced quantities of DNA and RNA in a number of organs of young vitamin A deficient rats.

Seifried (1938) showed by experimental investigations that vitamin A deficiency in fowls favoured a high incidence of pox (90%). He also suggested the possibility that lesions in mucous membranes due to vitamin A deficiency might be accompanied by a change in the bacterial flora. Panda (1962) observed that higher vitamin A levels helped in reducing the severity of infection with

Infectious bronchitis virus. Chicks that were experimentally infected with Ranikhet disease suffered fewer deaths when treated with vitamin A. Mortality due to Pullorum disease and Fowl typhoid lowered when ample vitamin A was present.

C L I N I C A L S Y M P T O M S:

Cruickshank (1927), Seifried (1930) and Grasovsky (1932) recorded clinical symptoms due to vitamin A deficiency. There was staggering gait, general ruffled condition of the feathers accompanied by emaciation and weakness. Watery discharge from the nostrils was invariably present. Later this may get collected in the infraorbital sinuses and transforming into a caseous mass resulting in the swelling of the face. Emslie (1934), Taylor et.al. (1947) and Gibson (1960) recorded failure of growth at normal rate, incoordination of movements and drowsiness. In all the cases the birds became lethargic and weak. The conditions sometimes became so severe that the birds were unable to stand except momentarily.

Cruickshank (1927), Grasovsky (1932), Barron (1942), McDonald (1944), Iyer et.al. (1947), Iyer

Iyer (1948) and Hungerford (1961) noted reddening of the conjunctiva and profuse watery secretion. This was followed by a swelling of the eye, the serous discharge becoming thick and gradually transformed into a thick whitish cheesy deposit inside the eyelids and outside the eye ball. Cruickshank (1935) stated that all chicks do not exhibit xerophthalmia because they often die before the eyes become affected. Norris (1941), and McDonald (1944) described that margins of the eyelids became granular and if infection sets in, a sticky fluid was produced and the eyelids stick together. Jungherr (1945) indicated that presence of whitish flakes in the conjunctival sac was suggestive of vitamin A deficiency.

Grasovsky (1932) noted the deposition of a chalk like substance on the feathers below the vent. Barron (1942) marked caseous deposits in the bursa of fabricus.

M A C R O S C O P I C P A T H O L O G Y:

Beach (1924), Seifried (1930), Grasovsky (1932), Beri (1949), Wilson (1954), Gibson (1960) and Blount (1961) observed that the characteristic

symptoms of the disease were confined to the head and involve the nasal passage, mouth, pharynx, oesophagus and crop. There was collection of white caseous material in the mucous glands. On the surface of the mucous membranes they appeared as circular white pustular like caseous patches varying from 0.5 mm. - 2 mm. in diameter. Small pustules and ulcers may be covered by a thick exudate inside the mouth. Yellowish grey discrete necrotic lesions were also present in the pharynx and upper oesophagus. These pustules are generally raised above the surface of the mucous membranes and often showed a depression in the centre. Pustules of oesophagus and crop were more prominent than those in the mouth. Nodules in the oesophagus did not ulcerate as frequently as those in the mouth cavity.

Norris (1941) recorded that the secretions of the intestinal glands, tear glands and salivary glands become decreased.

Beach (1924), Seifried (1930) and Hungerford (1961) described that clinical symptoms and pathological lesions of vitamin A deficiency of the respiratory tract were variable and it was difficult to differentiate this condition from infectious coryza, virus diphtheria and infectious bronchitis. Exudate in vitamin A

by failure of endochondral bone growth. The effect upon epiphyseal cartilage was distinctive and specific and was a primary result of vitamin A deficiency in the sense that it was not secondary to inanition.

Hart et al. (1916) probably were the first to describe and demonstrate nerve lesions due to vitamin A deficiency. Hughes et al. (1929), Taylor et al. (1947), Wolbach and Bessy (1941) and Wolbach et al. (1952) stated that neurological disturbances of vitamin A deficiency in the chick were the result wholly of compression of C.N.S. produced by retardation of growth of vertebrae and bones of the cranium. The effect was virtually that of an overgrowth of C.N.S. with consequent mechanical injuries to the brain and spinal cord. Peripheral nerves also may show pathological alterations.

Woollam et al. (1956) showed that vitamin A deficiency resulted an increased cerebrospinal fluid pressure. Emslie (1934) observed blood uric acid was increased in high value.

H I S T O P A T H O L O G Y:

Mason and Ellison (1935) suggested that vitamin A plays a part in protein metabolism within

the epithelial cell. Cells deprived of vitamin A, the production of glycoprotein or mucin are retarded and albuminoids or keratin increased.

Seifried (1930) studied the lesions of the upper alimentary tract and marked proliferation and degeneration of the original epithelium. At the same time new stratified epithelium appeared beneath or in place of original epithelium. In the acini the high mucous secreting epithelium had begun to degenerate and atrophy and there had been a replacement by stratified keratinizing cells.

The histological picture showed that early infections of the excretory ducts of the glands were relatively common. These infections were manifested by necrosis of the epithelial lining of the duct and of the surrounding mucous membranes by cellular infiltrations. In the submucosa signs of infection such as perivascular and diffuse infiltrations were frequently seen.

The first lesion of respiratory tract was in the columnar ciliated epithelium which was characterised by atrophy of the cytoplasm and loss of the cilia. Along with this change, the nuclei often presented

more or less marked karyorrhexis. This atrophy and degenerating ciliated cells hanged like tufts on the basement membrane. While this process was going on there appeared as islands beneath the original epithelium new cylindrical or polygonal cells either singly or in pairs.

Principal tissue change was atrophy and degeneration of the lining mucous membrane epithelium as well as of the epithelium of the mucous membrane of glands. The process was accompanied by the replacement or substitution of the degenerating original epithelium of these parts by a squamous stratified keratinizing epithelium.

Respiratory tract was seriously damaged or even entirely destroyed by the degenerating of the ciliated cells at the surface and the lack of secretion with bacteriocidal properties. Secondary invasions were frequently found and various kinds of inflammatory changes were present.

Elvehjem et.al. (1932) recorded parenchymatous degeneration of kidney particularly the tubules and hyaline deposits in artery and glomeruli. The structure of the kidney was damaged sufficiently to prevent the normal elimination of uric acid.

Sheldon et al. (1956) studied the morphology of corneal epithelium by electron microscope in vitamin A deficiency and morphological abnormalities have been noted in the mitochondria in the intermediary keratinizing layer in rabbits.

Seifried et al. (1942) noted marked changes on the testes in the male vitamin A deficient bird. There was atrophy and degeneration. Degenerative changes also occurred in the oviducts of the female birds. These changes were due to lack of vitamin A. So vitamin A deficiency was sufficiently severe to produce sterility in fowls.

Wolbach et al. (1952) noted that all epiphyseal cartilage cell sequences were retarded, namely, multiplication growth and maturation. The tunneling of the epiphyseal cartilage was irregular often forked or branched and less extensive. The zone of proliferating cartilage cells were less clearly demarcated and cells in mitosis were absent. The intercellular matrix gradually increased and there was formed a broad zone of moderately enlarged cells in noncalcified matrix. Cells of mature size surrounded by calcified matrix constitute a narrow and irregular zone in the diaphyseal side where tunneling was present.

Rigdon (1952) observed in ducks significant pathological changes within the C.N.S. namely haemorrhages and necrosis of the gray and white matter, degeneration in the fibre tract and nerve cells. The nerve cells frequently were shrunken and dark staining and nuclei were invisible. A clear space surrounded many of these pyknotic nerve cells. Fragmented nerve cells were also present in many cases.

C L I N I C A L P A T H O L O G Y :

The literature reveals very meagre information about the blood picture of the chickens suffering from vitamin A deficiency.

Cook (1937) has studied the normal values for erythrocytes, haemoglobin, clotting time and differential counts in growing chicks to determine what normal variations occur in these elements. He noticed slight anaemia on a diet somewhat deficient in vitamins. Emmel (1940) showed that red cells were not remarkably affected in dogs and rabbits in avitaminosis A. Kehar et. al. (1956) studied the blood of lambs of vitamin A deficient diet. The red cell count, haemoglobin value, packed cell volume and percentage of lymphocyte

decreased remarkably. But there was increase in the percentage of polymorphs. Mahadevan et.al. (1962) examined the calves associated with hypovitaminosis A and found total erythrocytic count slightly low in the affected calves.

3. Experimental

Different workers recommended different basal vitamin A deficient diets which are of course fundamentally similar.

Ferreira et.al. (1952) recommended a diet deficient in vitamin A which contained the following constituents.

Wheat flour	100
Barley flour	20
Castor	20
Yeast	5
Ground bone	2
Sodium chloride	1
Vitamin C	1

CHAPTER - III.

MATERIALS AND METHODS.

A. Experimental Birds:-

All experiments were carried out with White Leghorn chicks obtained from Central Poultry Farm, Patna. Only day old chicks were taken, reared in electrically heated brooder and fed with standard chick mash and water ad libitum.

B. Experimental Feed:-

Different workers recommended different basal vitamin A deficient diets which are of course fundamentally similar.

Ferrando et al. (1958) recommended a diet deficient in vitamin A which contained the following constituents.

	<u>Percentage.</u>
Maidar flour -	15
Barley flour -	55
Casein -	20
Yeast -	5
Ground bone -	2
Sodium chloride -	1
Calcium carbonate -	2

Hill et al. (1961) recommended the following basal vitamin A deficient diet.

		<u>Percentage.</u>
Glucose	-	42.6
Ground wheat	-	10.0
Soyabean meal (50% protein)	-	35.0
Ether extracted fish meal	-	2.5
Dried yeast	-	2.5
Dried whole whey	-	2.5
Dicalcium phosphate	-	2.0
Limestone	-	1.5
Salt	-	0.25
Dl-methionine	-	0.2
Hydrogenated shortening	-	1.0

Vitamins and minerals added per Kg. diet:-

Dipotassium hydrogen phosphate	-	3.5gm.
Magnesium sulphate	-	1.2 gm.
Manganese sulphate	-	0.15gm.
Ferrous sulphate	-	0.28gm.
Copper sulphate	-	7.8 mg.
Sodium iodide	-	1.3 mg.

Calcium pantothenate	-	10 mg.
Thiamine	-	3 mg.
Riboflavin	-	5 mg.
Pyridoxine	-	5 mg.
Niacin	-	26 mg.
Biotin	-	0.1 mg.
Folacin	-	1 mg.
Menadione	-	1 mg.
Choline chloride	-	1 gm.
D ₃	-	400 I.C.U.
Alpha tocopherol	-	20 I.U.
B ₁₂	-	0.01 mg.

Deo et al. (1962) computed the vitamin
A deficient ration as follows:-

		<u>Parts.</u>
Ground wheat	-	50
Ground chunni	-	20
Ground oats	-	10
Ground-nut cake	-	19
Salt	-	1
Meat offals	-	Mixed with wet mash.
Limestone	-	Mixed with dry mash ad lib.

Deficient diet for experimental birds was prepared as recommended by Hill et al. (1961) with some alterations.

Modified basal vitamin A deficient diet:

		<u>Percentage.</u>
Sucrose	-	10.0
Wheat flour	-	42.0
Groundnut cake	-	35.0
Ether extracted meat meal	-	3.0
Dried yeast	-	5.0
Dicalcium phosphate	-	2.0
Limestone	-	1.50
Salt	-	0.25
DL-methionine	-	0.25
Dalda ?	-	1.0

Minerals and vitamins added per Kg. of diet as recommended by Hill et al. (1961) .

Meat was ether extracted in continuous ether extraction apparatus for sixteen hours to make it vitamin A free and then washed thoroughly in running water.

C. Pre-experimental Period:-

The birds were kept under observation for fifteen days. During this period the faeces of all the chicks were examined daily by direct, floatation and sedimentation methods for Coccidial oocysts, helminthic ova etc. Temperature of all the birds were recorded and blood smears examined stained by Giemsa for protozoan parasites etc. Birds, only showing normal temperature and free from parasitic infestation were selected for the experiment.

D. Experimental Period:-

After fifteen days the chicks were divided in two groups, one control and another deficient according to their body weight in such a manner so as to ensure that the average initial weight was same in both the groups.

Thirty birds were taken in the deficient group and given the deficient diet and water ad libitum. Twentyfive birds were selected for the control group which was housed seperately but given same diets with excessive vitamin A supplied was in the form of codliver oil, vitamin A capsule and green grass.

The weight of individual bird was recorded in both the groups every week through out the experimental period. Temperature was also recorded.

Four birds in the experimental group died during the second week period and the deaths were found to be due to heat stroke as established by post-mortem examination.

Vitamin A content of livers in both the groups of birds were estimated every week by killing some of the birds.

The haematological studies of twenty birds of the deficient group were made after one month from the commencement of the experiment. By this time the birds showed clinical symptoms which were recorded under results. The haematological studies of twelve control birds were also made simultaneously i.e. one month after the commencement of the experiment. The above haematological studies were completed in a period of one week.

Again haematological studies of the remaining ten birds of the deficient group were recorded just after one and half months after the commencement of

the experiment. It may be mentioned that the number of birds became reduced to ten only as some of the birds died due to deficiency or killed before one and half months period for vitamin A estimation of liver. The haematological pictures of the remaining twelve control birds were also recorded after one and half months from the onset of experimental period. The haematological works were completed in a period of one week as done previously.

All the birds of the deficient group died within tenth week after the commencement of the experiment.

E. Vitamin A Estimation:-

Vitamin A was determined by its reaction with antimony trichloride which produces a fleeting blue pigment of unknown composition. This is the Carr-Price reaction Carr and Price (1926).

Procedure:

One gm. of liver was extracted with chloroform. One ml. of chloroform (chloroform dried over anhydrous Na_2SO_4) was transferred to the tube of the Fishers clinical electrophotometer

using a second ml. of chloroform to clean it out. One drop of acetic anhydride was added to take up any water. From a test tube rapidly added 8.0 ml. of antimony trichloride (20% solution in chloroform) and shaken vigourously and the tube was placed in the electrophotometer. The reading was noted within 3 - 10 seconds using a filter at 650 μ . It was repeated using 0, 20, 40, 80, 120, 160, 200 I.U. vitamin A standard per tube to get a standard curve. The amount of vitamin A in the liver was determined by plotting the curve.

Reagent Blank:- Antimony trichloride solution with one drop acetic anhydride.

F. Haematology:-

The blood was collected from wing vein. A mixture of 1.2 gms. of ammonium oxalate and 0.8 gm. of potassium oxalate dissolved in distilled water was used as anticoagulant in the proportion of 0.1 ml. per 1.0 ml. of blood as recommended by Heller and Paul (1934). The anticoagulant was evaporated to dryness in an oven at 60°C. Blood smears were prepared directly from unoxalated blood for differential count.

(a) Blood smears:

Uniformly thin smears were prepared and stained by Wright's stain. The number of leucocytes counted in each examination were 200.

(b) Haemoglobin determination:

Haemoglobin was estimated by Sahli- Haden haemoglobinometer.

(c) Total erythrocytic count:

Blain (1928) showed some practical difficulty in counting leucocytes of poultry as the treatment of erythrocytes with diluting fluid containing acetic acid which liberated their nuclei and which are seems to be small lymphocytes. Blain utilised two solution, Sol-I and Sol-II. Kyes (1929) used 2% solution of osmic acid. Forkner (1929) used a diluting fluid containing neutral red in distilled water. Wiseman (1931) suggested a diluting fluid contains phloxine. Toisson's fluid has been employed by several investigators. Recently Nambiar et al. (1962) stated that Randolph's fluid was found to be superior to the Wiseman's fluid for leucocytic counts.

Erythrocytes were counted directly in the counting chamber. Wiseman's diluting fluid which contains Phloxine - 50 mg, Neutral formalin - 5 cc. and Ringer's solution - 95 cc has been used as it has lowest coefficient of variation in erythrocyte counts and is to be regarded as the most consistent in results (Olson, 1937). The filled pipette was allowed twentyfour hours refrigeration for maximum staining as recommended by Olson (1937).

(d) Total leucocytic count:

Wiseman's diluting fluid has been used and allowed twentyfour hours refrigeration as stated by Olson (1937). Total heterophils and eosinophils on the entire ruled area of the counting chamber (9 sq. mm.) were counted. This total was used for final calculations as follows (Olson, 1937).

$$\frac{10}{9} \left(\begin{array}{l} \text{Number of heterophils and} \\ \text{eosinophils counted in} \\ \text{chamber.} \end{array} \right) 200$$

$$\left(\frac{100}{\text{Total percentage of heterophils}} \right) \\ \left(\text{and eosinophils in smear.} \right)$$

(e) Corpuscular volume and erythrocytic sedimentation rate:

Clean Wintrobe haematocrit tubes of 11 cm.



length and 2.5 mm. bore and graduated with a centimeter and millimeter scale were used. One such tube filled with blood up to the mark " 10 "cm. with loading pipette and allowed to stand for one hour. The erythrocyte sedimentation rate was recorded directly from the tube in millimeter per hour Wintrobe (1942).

The tube was then centrifuged for twenty to thirty minutes till constant reading was obtained at a speed of 3000 rounds per minute. The corpuscular volume was directly read from the tube.

There is some effect of climate and time of collection of blood on the number of erythrocytes in fowls. Olson (1937) suggested a seasonal variation in red cell count, with values higher in the winter. Domm and Tabber (1946) observed a diurnal variation in erythrocytes, with high values at midnight and the lowest values at noon.

So the temperature was noted through out the experimental period and blood was collected always in the morning.

G, Histopathology:-

The organs were collected from the dead or killed bird and preserved in 10% Formal saline. The organs preserved were eye, pharynx, oesophagus, nasalseptum, trachea, intestine, heart, lungs, spleen, liver, kidney, brain, spinal cord and bone.

Sections were cut with a Spencers rotary microtome at 4 microns to 5 microns in cases of all the organs except the brain and spinal cord. The tissue of the central nervous system were cut at 6 microns to 7 microns as recommended by Culling (1957). Bones were decalcified in the 5% aqueous nitric acid. Sections were stained with Harris's alum haematoxylin and Eosin (Lillie, 1948).

CHAPTER - IV.

R E S U L T S.

BIOCHEMICAL STUDIES:-

TABLE I

Showing average vitamin A content per gm. of liver
in the control and the deficiency group.

Week	Control group		Deficiency group	
	Vitamin A I. U.	No. of birds examined.	Vitamin A I. U.	No. of birds examined.
1	135	2	135	2
2	140	1	65	4
3	185	2	28	1
4	200	1	8	2
5	225	2	Nil	8
6	225	1	"	2
7	240	1	"	3
8	246	2	"	4
9	250	1	"	2
10	250	1	"	1

It would appear from the Table I that in the first week the average vitamin A content of liver was 135 I.U. per gm. in both the groups. In the second

week the average vitamin A content in the deficiency group decreased to 65 I.U. per gm. while the average vitamin A content of liver of the control group was 140 I.U. per gm. In the third week the average vitamin A content of liver diminished to 28 I.U. per gm. and in the fourth week only 8 I.U. per gm. was present in the deficiency group. The average vitamin A content of liver was 185 I.U. and 200 I.U. per gm. in the third and fourth week respectively in the control group. From the fifth week onwards no vitamin A was detected in the deficient group. On the other hand, vitamin A content of liver in the control group gradually increased to 250 I.U. per gm. at the end of the experimental period.

STATISTICAL BUREAU

II

Group after one month from the

Differential count									
10	11	12	13	14	15	16	17	18	19
30	63	32	1	1	8				
30	62	31	1	1	4				
31	61	32	1	1	4				
31	60	32	2	1	5				
30	60	31	2	1	6				
31	60	32	3	1	4				
31	59	36	1	1	3				
30	55	38	2	1	4				
30	60	35	1	1	3				
31	61	32	1	1	5				
31	61	33	2	2	4				
31	62	36	1	1	4				
30	60	33	1	1	4				
30	60	33	1	1	4				

The haematological work was undertaken in the month of May and June. The temperature varied at that time from 31°C - 41°C maximum and 19°C - 26°C minimum with an average of 36.6°C and 24.3°C respectively at Patna.

Results of the haematological studies in the deficient group and the control group both one month and one and half months from the commencement of the experiment are incorporated in Tables II-V.

It would appear from Tables II and III that after one month from the commencement of the experiment there were decrease of 1.6 gm.% in haemoglobin, 2.8% in packed cell volume, 0.7 million per cmm. in R.B.C. and 2.5% in M.C.H.C. in the deficient group than the control group. There were also increase of 27.9 c.u in M.C.V. and 5 micromicrograms in M.C.H. in the deficient group. Differential count revealed 3.3% reduction in Lymphocytes and 3.5% increase in heterophiles than the control group.

After one and half months from the commencement of the experiment as shown in Tables IV and V, there were also average decrease of 2.1 gm.% in haemoglobin, 4.5% in packed cell volume, 0.9 million per cmm. in

R.B.C. and 2.7% in M.C.H.C. in the deficient group. than the control group. There were average increase of 31.6 c.u. in M.C.V. and 5.6 micromicrograms in M.C.H. Differential count also revealed 3% increase in heterophiles and 2.9% reduction in lymphocytes than the control group.

In both the groups, one month and one and half months from the commencement of the experiment there were no marked variation in the erythrocyte sedimentation rate and total leucocytes. The eosinophiles, basophiles and monocytes almost remained constant.

Tables VI and VII would show that the changes in the haemoglobin, total erythrocytes, packed cell volume, lymphocytes, mean corpuscular haemoglobin concentration which were found to be lower in the deficient group than the control both one month and one and half months from the commencement of the experiment are statistically significant. That is the case with the heterophiles, mean corpuscular volume and mean corpuscular haemoglobin which were found to be higher in the deficiency group.

The alterations in the erythrocytes sedimentation rate, total leucocytes and the percentage of eosinophiles, basophiles and monocytes are insignificant.

CLINICAL SYMPTOMS:-

The clinical symptoms appeared after one month from the commencement of the experiment. Growth became stunted from the third week of the experiment (Fig.1). From this time there was regular decrease in growth rate of the deficient group as compared to control group as shown in Table VIII.

TABLE VIII

Showing average weight of the control and the deficient group and their difference in ounces.

Week	Control group oz.	Deficient group oz.	Difference oz.
1	3.4	3.4	-
2	3.8	3.8	-
3	4.2	3.9	0.3
4	4.8	4.2	0.6
5	6.2	4.9	1.3
6	8.8	6.6	2.2
7	11.6	8.1	3.5
8	14.0	8.6	5.4
9	16.0	9.0	7.0
10	18.2	10.0	8.2
Average	9.10	6.25	2.85

The average weight of both the groups at the commencement of the experiment was 3.4 ounces. At the end of the experimental period the difference of weight between the experimental group and the control group was significantly high as shown in Table VIII, where it will be seen that while the average weight of the control group was 9.40 ounces, the average weight of the deficient group was 6.25 ounces.

The feathers became ruffled (Fig.2) and general drowsiness was present. There were incoordination of movement and staggering gait (Fig.3). The birds were hunched up.

No deviation of temperature from the normal limit could be detected except in three birds where the temperature was slightly higher than the normal and this does not appear to be significant. The growth rate of both the groups in every week was represented in Graph A.

The birds did not show inclination to move though in general they were not indifferent in feeding and drinking. But due to partial paralysis affecting the leg, they could not move properly for

feeding and drinking (Fig. 4). Leg weakness was found to set in after one month from the commencement of the experiment. Paralysis of leg appeared in the sixth week in all the birds except in two where it appeared on seventh week of the experimental period (Fig.5).

Infraorbital fossa was slightly swollen (Fig.6). Conjunctiva was congested in some of the birds and excessive lachrymation was also present. There was distinct white spot on the cornea in three birds after one and half months from the commencement of the experiment (Fig.7). Cheesy deposits were present inside the eyelids.

Nasal discharge was present which at first was watery and gradually became thicker in consistency.

Face appeared swollen. Distinct cheesy deposits were noticed inside the mouth. Deposition of whitish material was present near the cloaca which may be due to excessive uric acid in the system.

In general there was reduced skeletal growth. Comb, shank and beak which were distinctly yellow in colour became pale and ultimately almost white.










Fig. 7.

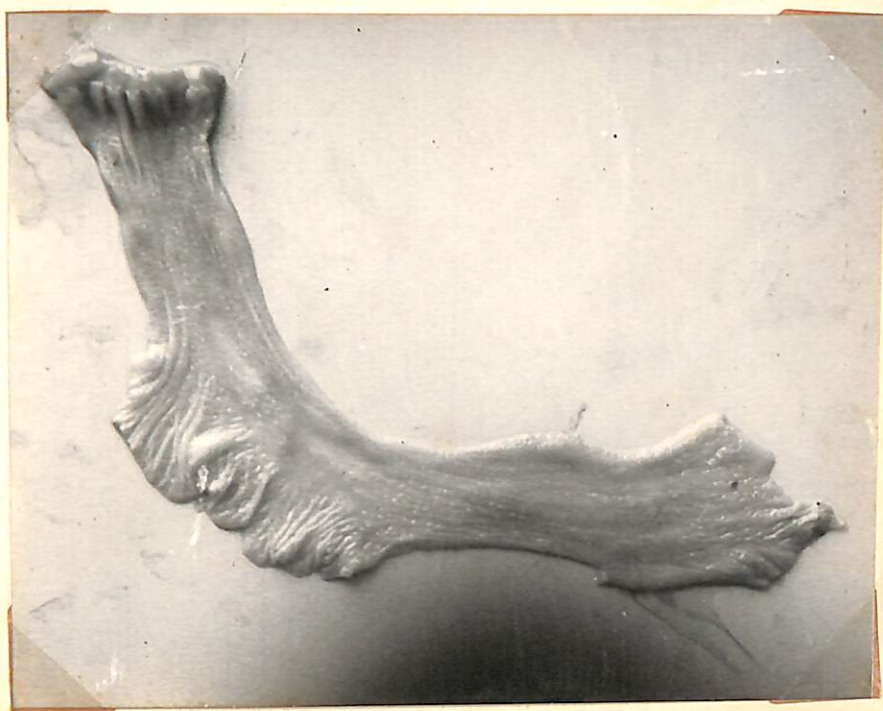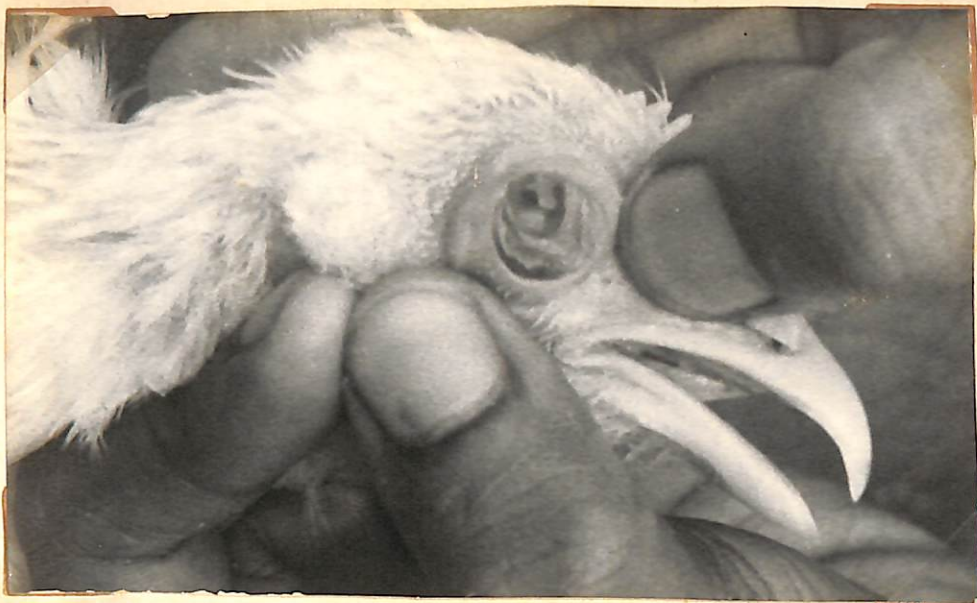Color showing distinct white

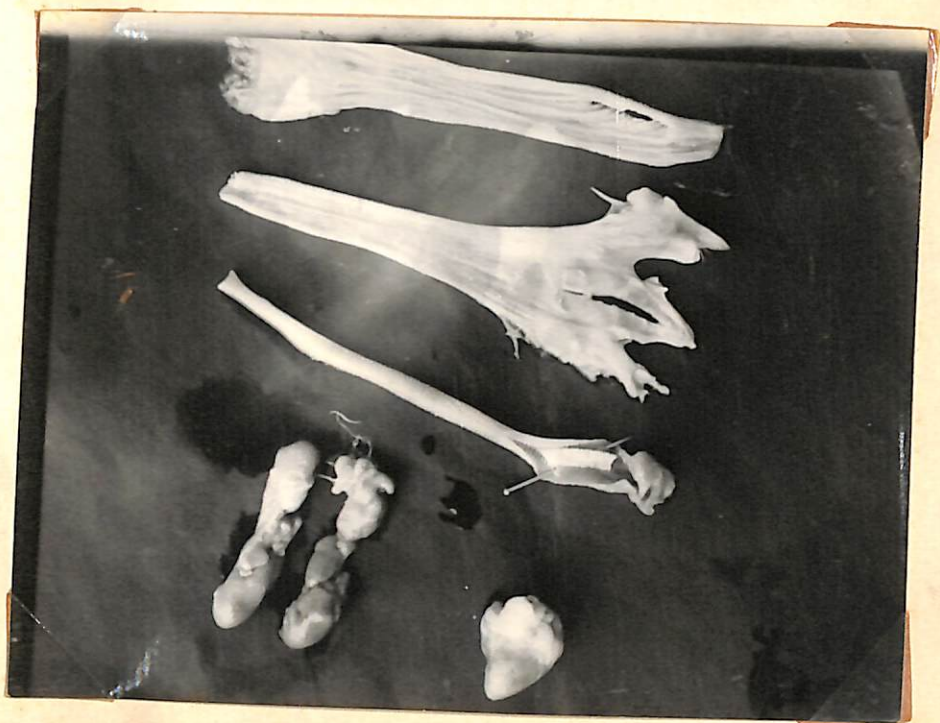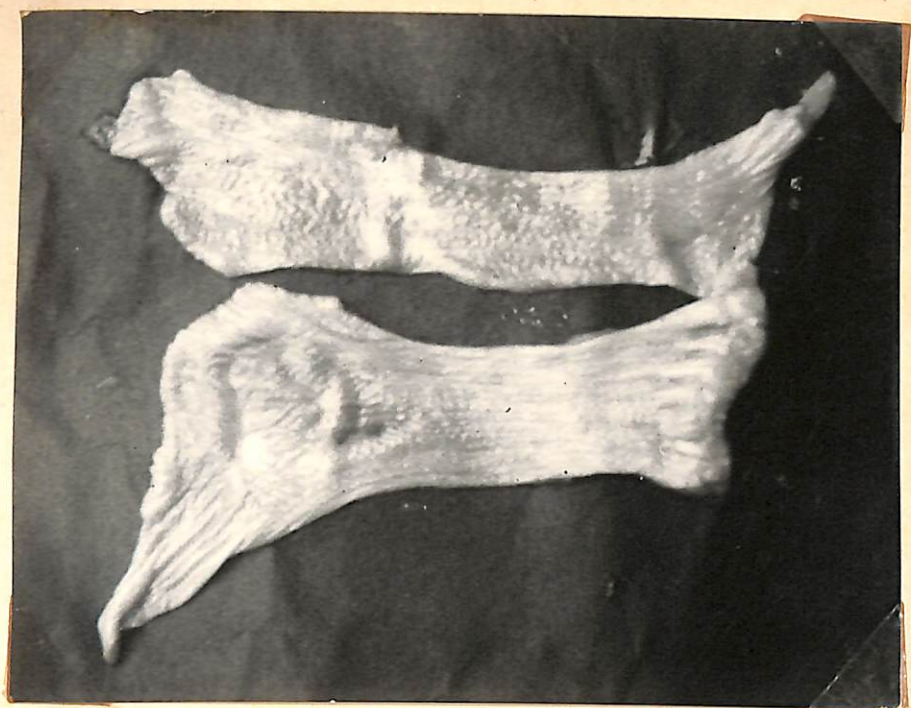spot on the corner.

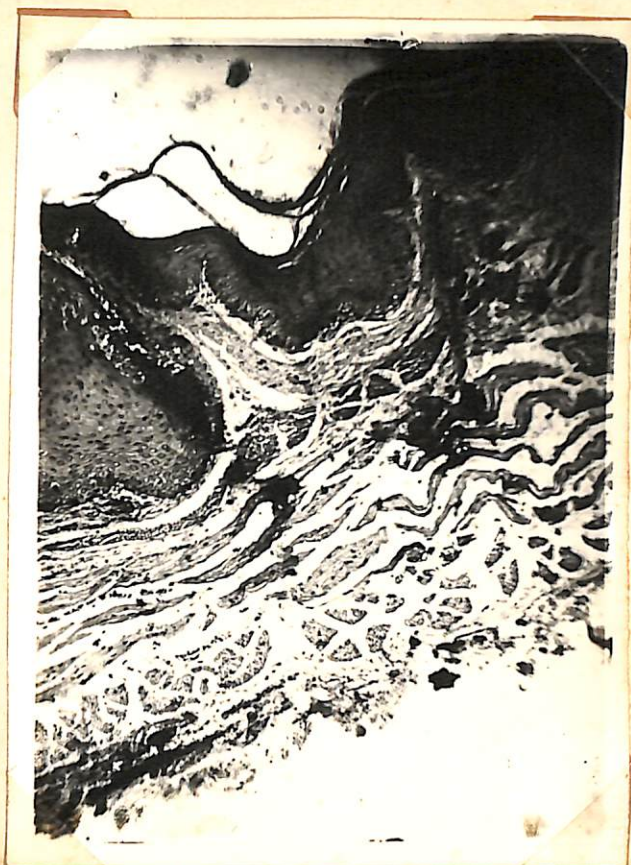Fig. 8.

showing pustules in the pharynx,

oesophagus and crop.







PATHOLOGY

MACROSCOPIC PATHOLOGY:-

The birds were slightly anaemic. There were cheesy deposits inside the mouth in all the birds being numerous near the roof of the mouth. Some necrotic tissues were also present.

Pustules of various size were present in the mouth, pharynx, oesophagus and crop (Fig.8). These pustules were whitish in colour and numerous in the oesophagus than that of the mouth. These pustules were raised above the mucous membranes and some of them were ulcerated (Fig. 9). Ulceration and necrotic tissue were more numerous in the mouth. In some cases desquamation of the epithelium took place. These changes were quite constant and found in all the birds.

In the intestine no gross lesion was present except slight congestion in some of the cases. There were no changes generally in proventriculus and gizzard except in one case there was desquamation of epithelium of gizzard. Congestion was more common near the cloacal region. Undigested food

was present in the intestine of few birds. Whitish nodules in the intestine were very rare and present only in two cases.

Exudate was present in nasal passage which was not watery but sticky in consistency. In some of the birds they formed a false membrane in the nasal passage.

In trachea mucus was present in some of the birds. But slight congestion and desquamation of epithelium were the constant features (Fig.10). Mucus was present also in the bronchioles. Lungs were congested and easy to cut.

Heart was slightly pale and flabby. The distribution of fat in the heart decreased considerably (Fig.11). Hydropericardium was present only in two birds. Nearly 5 ml. of fluid was removed from the pericardial sac. The fluid was serous in character. Deposition of urates was also present on the pericardium.

Spleen was seen to be slightly smaller than normal and brownish in colour.

Liver was slightly congested and smaller than normal. Some whitish spots were present in the liver of seven birds. Friability of the liver was slightly increased.

Kidneys were pale and enlarged. Some whitish streaks were present on the kidney and these were found to be due to the deposition of excessive amount of urates (Fig.10). The ureters were also distended and filled up with urates. These kidney lesions were recorded in all the birds.

Cheesy deposits were present inside the eyelids. Whitish spots of various sizes were present over the cornea in three birds only.

There was no gross lesion in the brain and spinal cord except slight depression on the cerebellum in four cases due to the disproportionate growth between the brain and the bone.

There was no gross lesion in the bone except these were smaller in size than that of the control group.

HISTOPATHOLOGY

Oesophagus:-

Degeneration and proliferation of the original epithelium was present. The stratified squamous epithelium was transformed into keratinized epithelium. Continuity of epithelium was not present in all the cases and in seven birds desquamation of epithelium was present (Fig.12). Oesophageal glands began to degenerate and in some cases there had been replacement of epithelium in the acini by stratified keratinizing cells. Cellular infiltration was also present in the submucosa and beneath the epithelium in some cases.

Pharynx and Base of Tongue:-

Changes were similar as seen in oesophagus. Metaplasia of the stratified squamous layer and degeneration of glands were present. Inflammatory changes were absent. Break of continuity of epithelial layer was seen.

Intestine:-

Slight congestion and degeneration of the epithelial layer and leucocytic infiltration in the villi were common changes (Fig.13).

Trachea :-

Atrophy and degeneration of columnar cells were frequently seen. The normal cilia of the ciliated columnar lining had been lost. The nucleus of the cell became hyperchromic and marked karyorrhexis was also present. The epithelium of the mucous membrane gland was degenerated. Leucocytic infiltration was present. Desquamation of the epithelium was present in seven birds (Fig. 14).

Lungs :-

Congestion and haemorrhages were common. Haemorrhage was present in the alveoli and the interstitial tissue (Fig.15). Erythrocytes were present in the alveoli. Emphysema was also present in some cases.

Exudate was present in the alveoli and bronchioles. Degeneration of the epithelial cells of the bronchioles were common.

Heart :-

Nucleus became hyperchromic and fragmentation of heart muscles were present in some birds. Cloudy swelling and slight fatty changes were constant feature. There was infiltration of mononuclear cells in the myocardium. Heavy leucocytic infiltration was present in the epipericardium due to the inflammatory changes (Fig. 16). Some of the blood vessels were dilated and contained few erythrocytes.

Inter Nasal Septum:-

Metaplasia of the epithelium was constant feature. Desquamation of the epithelium and beneath the epithelium slight inflammatory changes were also present (Fig. 17).

Spleen:-

Slight degeneration of the lymphocytes were seen.

Lymphocytes

Liver :-

The hepatic parenchymal cells were pleomorphic and had vesicular but hyperchromic nuclei with prominent nucleoli. Some of the parenchymatous cells were completely necrosed which was of coagulative type and converting them into eosinophilic masses (Fig.18). Inflammatory cells were not common. Cloudy swelling, fatty degeneration and individualisation of liver cells were common. Blood vessels were dilated and sinusoids contained abnormal number of erythrocytes indicating tendency of haemorrhage. Haemorrhages were prominent in five birds (Fig.19).

Kidney:-

Kidney lesion was almost similar in all the cases. Degeneration of the tubule was a constant feature. Nuclei of the cells have undergone various degenerative changes such as pyknosis, karyorrhexis and karyolysis. Some of the epithelial cells of the tubules were desquamated and some of the tubules were completely necrosed (Fig.20). Cellularity of the glomeruli increased giving a swollen appearance. Isolated foci of small haemorrhages were also present in the tubules.

Cornea :-

To what type?

Superficial epithelium had undergone metaplasia. Degeneration of the epithelial cells were present. There was no evidence of inflammatory changes.

Spinal cord :-

Degenerative changes were present in the gray matter of the spinal cord. Some of the neurons became hyperchromic and nucleoli were not visible (Fig.21). The lesion was not uniform in all the cases. Some clear areas were present in the gray matter where nerve cells were present previously.

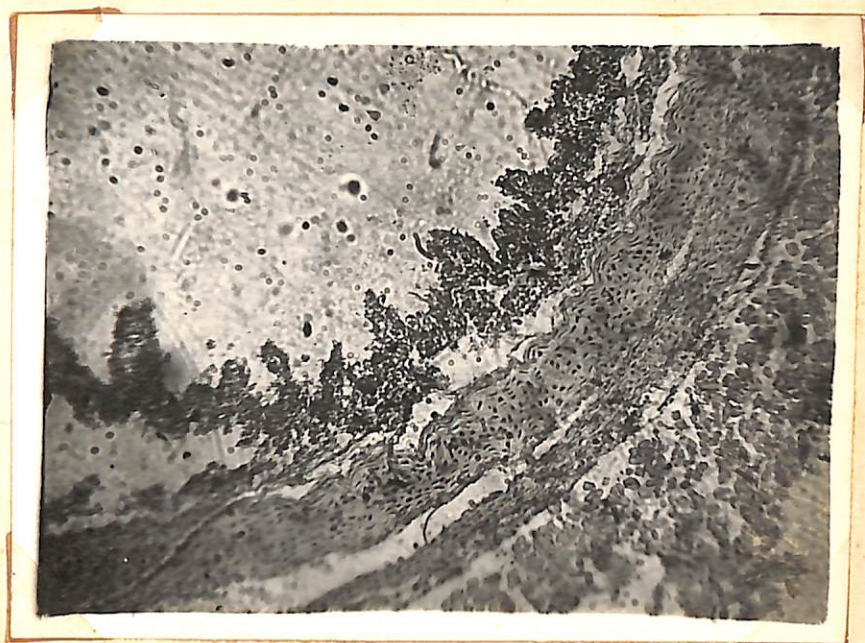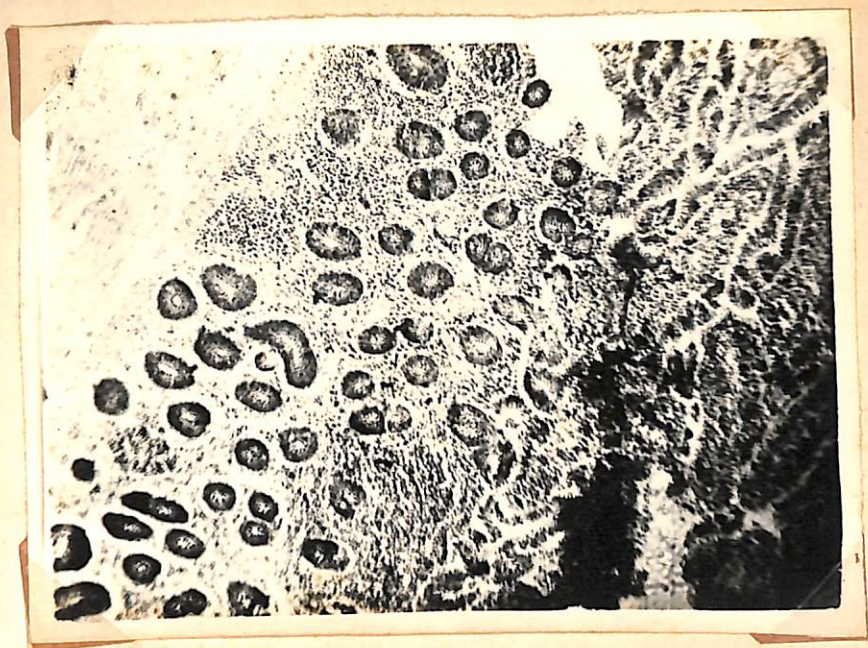Brain :-

Degeneration and shrinkage of neurons were present (Fig.22). Some of the neurons became hyperchromic and clear vacuoles were present around the degenerative neurons (Fig.23). Congestion of cerebral vessel was also present in some cases.

Bone :-

Part 1

The zone of proliferating cartilage cells were less remarkably demarcated and cells in division were absent. There was lack of calcified matrix (Fig.24).



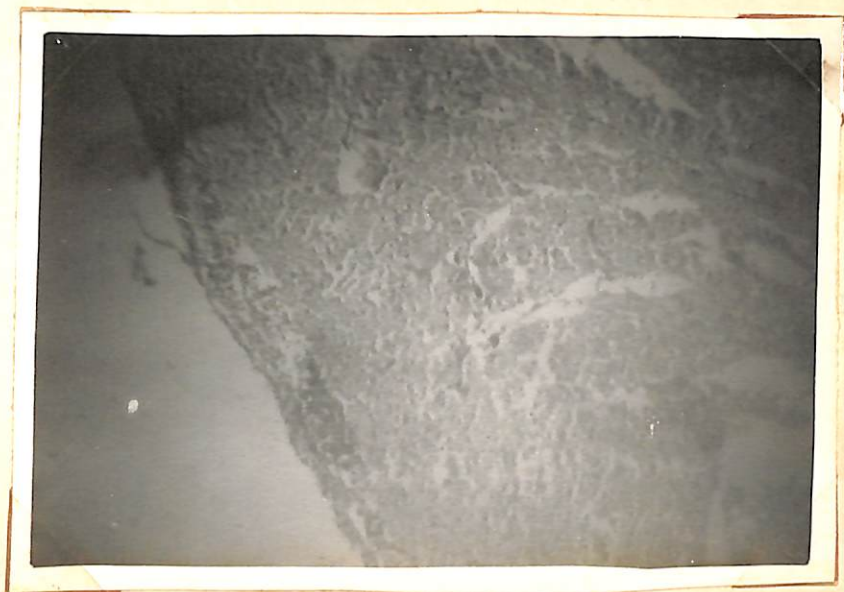
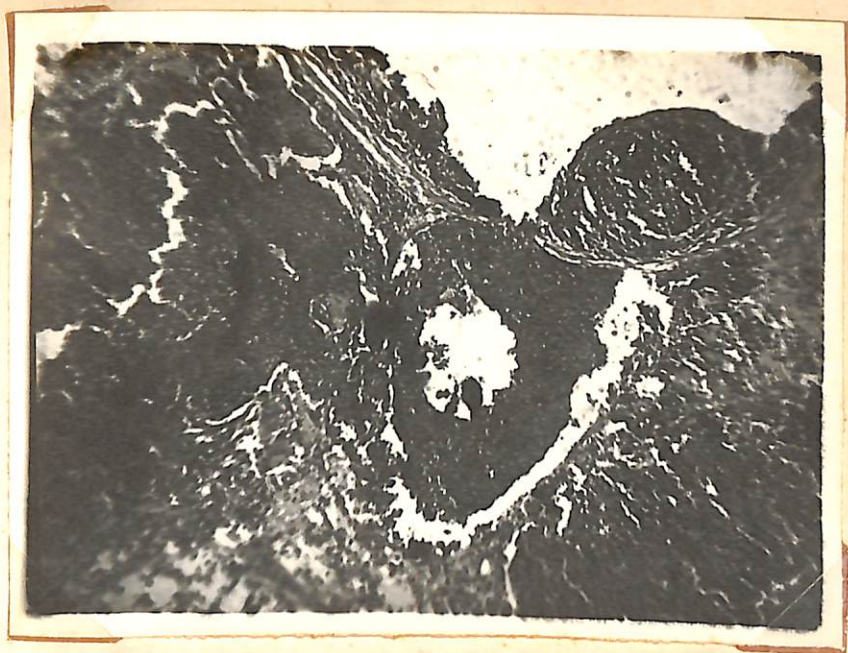

Fig. 17.


Section of the renal region stained
with Eosin X 400 to show nuclei in
the epithelium.

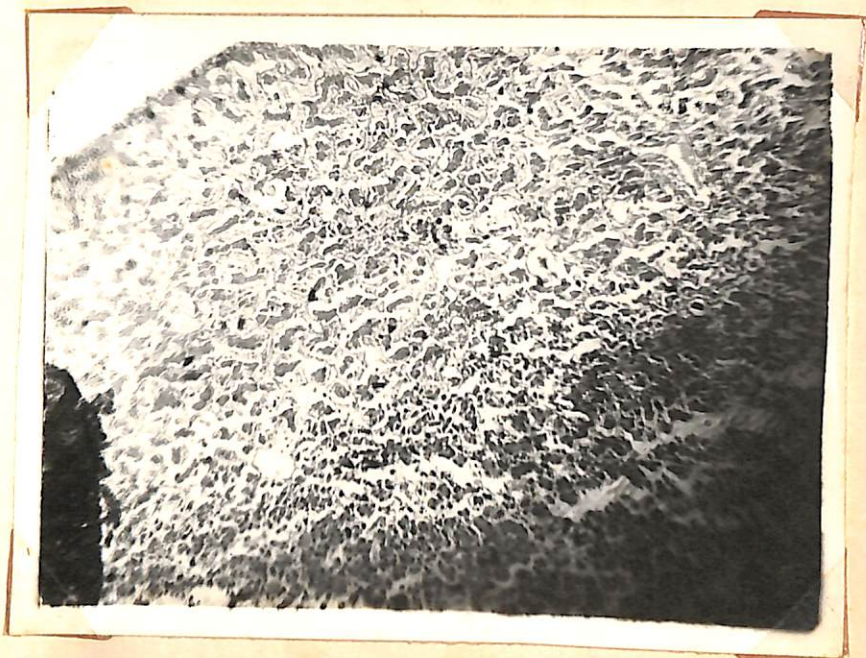

Fig. 18.

Liver section stained with Eosin X 100
to show nucleus of the liver cells.
Nucleus of some of the cells are
hyperchromatic.







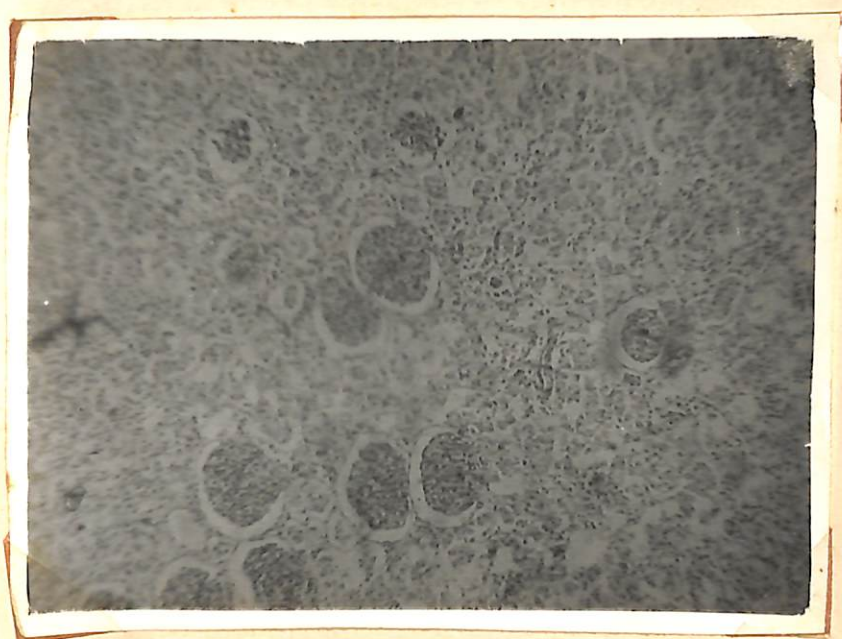
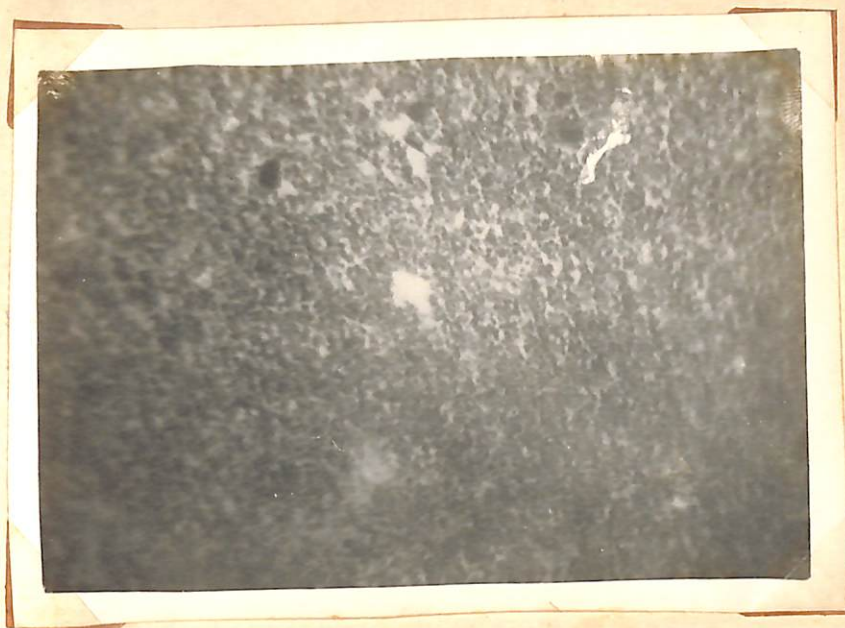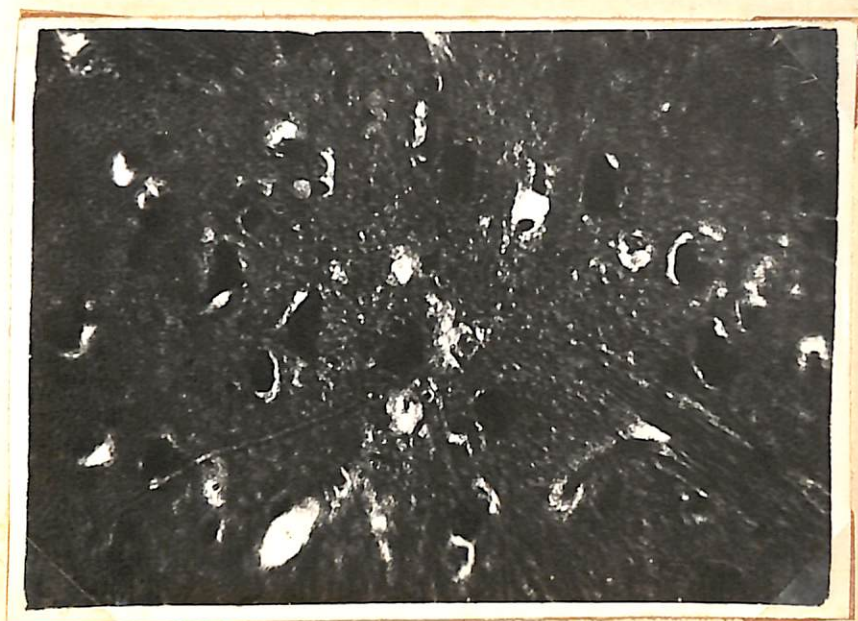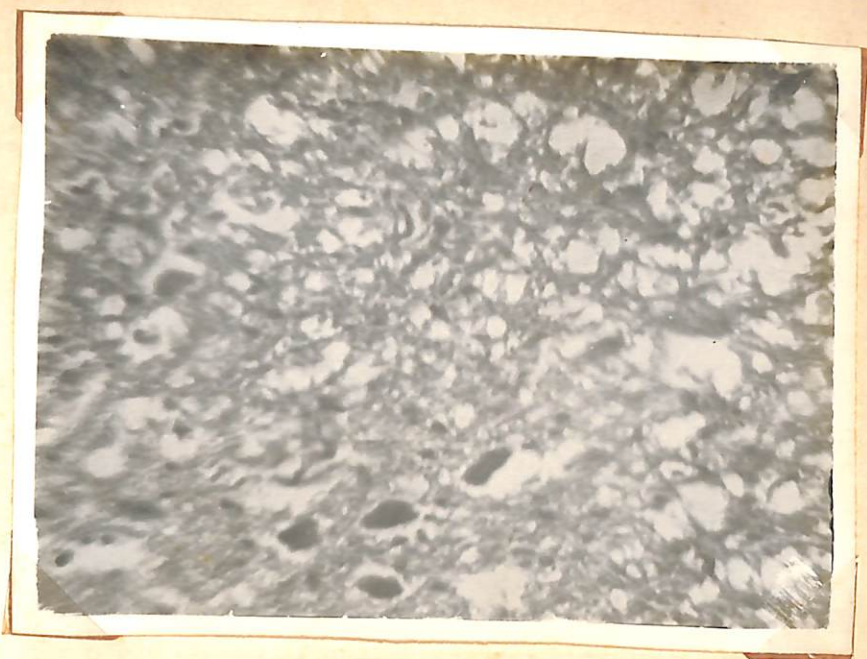


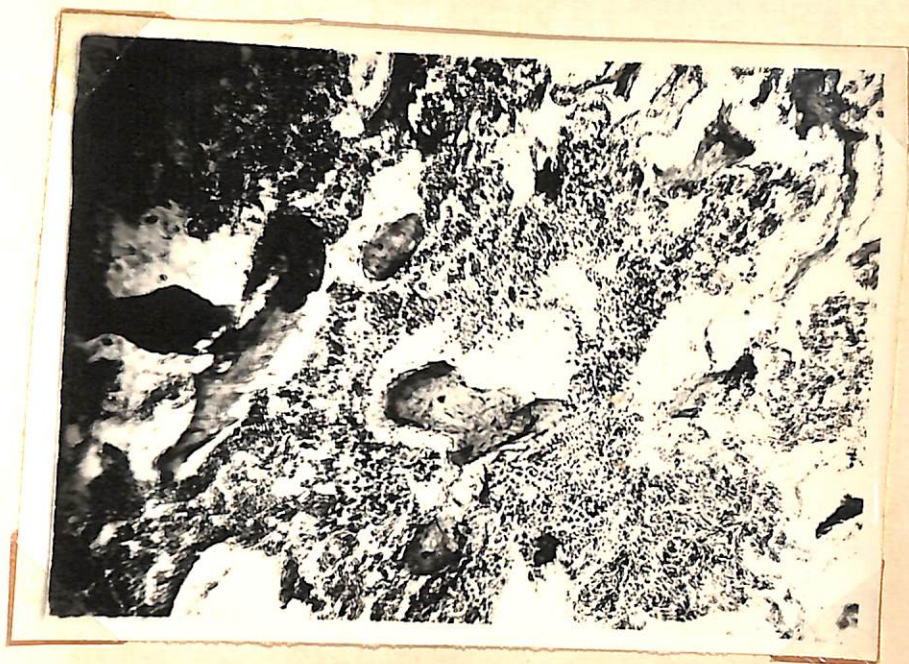
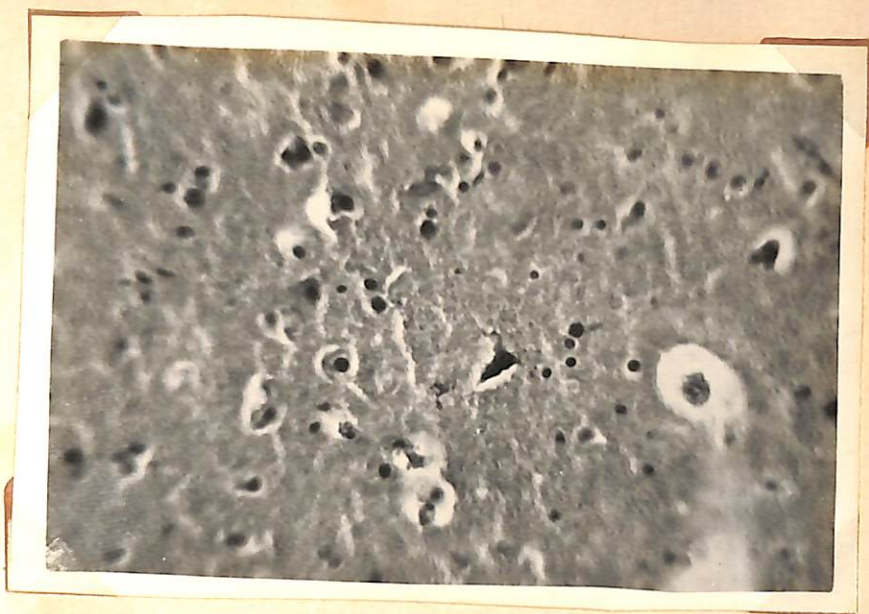Fig. 21.

Section of spinal cord stained with
Eosin x 400 to show hyperchromatic
neurons. Neurons are also not visible.

Fig. 22.

Section of spinal cord stained with Eosin x 400
to show hyperchromatic and hyperplastic
neurons.





CHAPTER - V

D I S C U S S I O N

In nutritional experiments it is preferable to use a synthetic ration as the constituents are known. The ration used in this experiment was deficient in vitamin A only but quite adequate in respect of other nutritional requirements as evident by the regular growth of the control group of chicks where adequate vitamin A was only supplemented to the ration.

The liver vitamin A content at the commencement of the experiment was 135 I.U. per gm. of liver. In fourth week average vitamin A content of liver of deficient group was 8 I.U. per gm., whereas in control group 200 I.U. per gm. of liver. From fifth week onwards no vitamin A was detected in the liver of deficient group but in control group 225 I.U. - 250 I.U. of vitamin A per gm. was present as will be seen in Graph B.

It is shown in the Graph A that there was regular increase in the growth rate of the control group whereas the growth rate of the deficient group

decreased gradually as compared to control. Initial average weight of both the groups was 3.4 ounces. In the third week the average weight of the control group and the deficient group were 4.2 ounces and 3.9 ounces respectively and so there was an average difference of 0.3 ounce.

At the end of the experimental period in tenth week from the commencement of the experiment the average weight of the deficient group was 10 ounces but in the control group it was 18.2 ounces as shown in Table VIII and the difference being 8.2 ounces which is very significant. This growth rate in the deficient group cannot be due to any other factor except vitamin A deficiency. Beach (1924), Seifried (1930) and Cruickshank (1935) have also observed similar decreased growth rate. Increased formation of albuminoids and keratin in the epithelial cells associated with vitamin A deficiency as mentioned by Mason and Ellison (1935) probably disturbed the utilization of the nutrients resulting decreased growth rate. Retarded bone growth was the other factor for the poor growth rate in the deficient group. This is in accordance with the findings of Wolbach et al. (1952) and Rigdon (1952).

Paralysis of leg was a constant feature in every deficient bird. This condition was not observed in the control group. Paralysis of leg appeared in all the deficient birds between sixth and seventh week after the commencement of the experiment. This was due to the degenerative changes within the central nervous system. There are two views regarding the neurological manifestation of vitamin A deficiency. Hughes et al. (1929) considered that a degenerative change occurs in the central nervous system and peripheral nerves whereas Wolbach et al. (1942) believed that the lesion in the nervous system result from a mechanical distortion produced by a decreased rate of growth of the vertebra resulting in pressure on the spinal nerves. Here also evidence of depressions on cerebral hemispheres and cerebellum due to bone were present in some cases which agrees with the findings of Wolbach et al. (1942).

The clinical symptoms appeared after one month from the commencement of the experiment which agrees with the findings of Paul et al. (1960) who showed that vitamin A deficiency in chicks developed between the fourth and sixth week when day old chicks were subjected

to vitamin A free diet. The clinical symptoms such as ruffled feather, staggering gait, drowsiness and incoordination of movements were present as observed by Emslie (1934). Excessive lachrymation and white spots on the cornea were also present as reported by Grasovsky (1932), Barron (1942), Jungherr (1945) and Iyer et al. (1947).

In the oesophagus, pharynx and mouth distinct nodules as mentioned by Beach (1924) and Seifried (1930) were recorded. It was due to metaplasia and proliferation of epithelial cells in the absence of vitamin A. This widespread squamous metaplasia increased the vulnerability of the epithelial cells to secondary bacterial infection. Necrosis of the epithelial cells in the mouth were probably due to the secondary bacterial infection.

It is perhaps due to the loss of cilia of the epithelium of trachea and bronchioles and metaplasia of the epithelium, the resistance of the birds became lowered considerably and respiratory symptoms were common in all the birds as marked by watery discharge from nostrils. Findings of Seifried (1930), Grasovsky (1932) and Hungerford (1961) are also in agreement in

in liver. But pustules were absent in the oesophagus. No other lesion was seen in other organs.

The birds were completely depleted from vitamin A in fifth week as evidenced by estimation of vitamin A content of liver. Paralysis of leg was seen only in the sixth week.

After one month from the commencement of the experiment when vitamin A content of liver was 8 I.U. per gm. nodules were seen in the pharynx and near the crop region only. Nasal discharge and slight lachrymation were present. Urates in the kidney and uraters were present. Slight haemorrhage and exudate in lungs, degeneration of tubules, infiltration in pericardium, cloudy swelling of myocardium and liver and keratinization of oesophageal epithelium were present. But lesion in the central nervous system were not prominent and only few neurons were found to be pyknotic. Bone changes were also not well marked.

But after one and half months after the commencement of the experiment where there was no vitamin A content of liver the birds were unable to move due to complete paralysis of leg. Corneal opacity

In the cornea, degeneration and metaplasia of the epithelium were recorded. Xerophthalmia which was regarded as the definite sign of avitaminosis A was not the constant feature in chicks as they died before the onset of Xerophthalmia. This findings is in agreement with what is stated by Cruickshank (1935).

The neurological changes were due to reduced growth of bone as stated by previous workers. Macroscopic examinations have yielded objective evidence of compression of brain and spinal cord as a result of retarded bone growth. Retarded bone growth was due to the lack of multiplication, growth and maturatation of epiphyseal cartilage as described by Wolbach et al. (1952).

*Effect of
vit. A on
osteoblasts*

The clinical symptoms appeared after one month from the commencement of the experiment when the vitamin A content was 8 I.U. per gm. of liver. In the third week when the vitamin A content of liver was 28 I.U. per gm., there was no clinical symptoms but on post-mortem examination presence of slight tubular degeneration in the kidney and metaplasia in epithelium of pharynx were noticed. In the fourth week tubular degeneration of kidney was more severe and there was marked haemorrhage

which was not present during earlier period i.e., before the sixth week period also appeared during this period in three birds. Hydropericardium was also recorded in two birds. Degree of necrosis in the liver, kidney, haemorrhage and congestion in the lungs were more severe than the previous period. Spleen also showed degenerative changes. Nodules were present through out the oesophagus from pharyngeal region to crop region whereas in the earlier period the lesions were confined to crop and pharynx as pointed out earlier. Desquamation of the epithelium of the oesophagus and trachea were also recorded in this period. Distinct pyknosis of the neurons in the brain and spinal cord were more common with congestion in brain. Zone of proliferating cartilage was found to be irregular showing deficient bone formation.

As detailed blood picture of chicken suffering from vitamin A deficiency is very meagre, the results obtained here could only be compared with that available for other animals species by Kehar et al. (1956) in lamb, Cook (1937) in poultry and Mahadevan et al. (1962) in calves.

Haematological diagnosis in the anaemias depends greatly upon number, volume and size of red cells with

haemoglobin content. In anaemia the mean corpuscular haemoglobin concentration may raise or decrease or remain within normal limit. There was increase of mean corpuscular haemoglobin and mean corpuscular volume with slight decreased of mean corpuscular haemoglobin concentration which are indication of macrocytic anaemia. Mean corpuscular volume by itself is a reliable indicator of macrocytosis except for the relatively rare phenomenon of spherocytosis. Here there were increase in 31.6 c. μ . and 5.6 micromicrograms of Mean corpuscular volume and mean corpuscular haemoglobin respectively and decrease in 2.7% of mean corpuscular haemoglobin concentration in the deficient group after one and half months from the commencement of the experiment.

This type of anaemia may be associated with spure, pregnancy, tropical malnutrition and in condition in which there is failure to elaborate, absorb, utilize or store the haemopoietic principle.

So alteration of the epithelium of the alimentary system and damage of the parenchymatous organs upset the utilization and absorption of nutrients due to which there may be anaemia. Presence of immature red cells in unusual number is an indication of anaemia which may be due to disturbance in haemopoietic system.

Increased percentage of heterophiles may be due to slight infection with secondary bacteria as the epithelial tissue undergoes alteration which lowered down the resistance of the birds. This lymphopenia is a relative phenomenon than an absolute one. This is due to increase in the percentage of heterophiles. Slight leucopenia may be due to malnutrition, cachexia and debility.

The results agree with the findings of Kehar et al. (1956) in lambs and only in respect of erythrocytes with Cook (1937) in poultry and Mahadevan et al. (1962) in calves. It was felt from the observations that blood picture of poultry along with clinical symptoms would be valuable adjunct in arriving at a correct diagnosis.

CHAPTER - VI

SUMMARY AND CONCLUSION.

Laboratory reared fiftyfive two weeks old chicks were taken and divided into two groups, thirty in the experimental group and twentyfive in the control one and average initial weight of both the groups were similar.

Both the groups were given basal modified vitamin A deficient diet. The control group, however received excessive amount of vitamin A in addition to deficient diet.

Weight of birds in both the groups were taken every week and liver vitamin A content was determined by electrophotometer in every week in both the groups by killing some of the birds.

After one month from the commencement of the experiment birds began to show clinical symptoms such as staggering gait, stunted growth, ruffled feather, discharge from nostril, lachrymation and paralysis of legs.

Haematological studies carried out in both the groups after one month and one and half months from the commencement of the experiment. It revealed decrease in haemoglobin, total erythrocytes, packed cell volume as compared to control. The differential count showed increase in heterophiles and decrease in lymphocytes. There was, however, no variation in the percentage of monocytes, eosinophiles and basophiles.

Histopathological studies revealed metaplasia in the alimentary tract and degenerative changes in the liver, kidney, heart, lungs, brain, spinal cord and bone. The bones of the birds of deficient group appeared smaller in size. In epiphyseal cartilage, cell growth and maturation were found to have slowed down.

From the experiment it appears possible to diagnose the vitamin A deficiency of poultry by the characteristic symptoms such as leg weakness, paralysis of leg, lachrymation, deposition of urates near the vent and arrested growth. Marked anaemia though present in other poultry diseases, also helps in reaching a correct diagnosis along with the clinical symptoms.

Autopsy findings such as characteristic nodules formed as a result of metaplasia in the alimentary tract particularly in the oesophagus, pharynx and crop, desquamation of the epithelium in the oesophagus and trachea, heavy deposition of urates in the kidney and ureters could be considered confirmatory findings for vitamin A deficiency. Histopathological studies of the lesions would greatly facilitate in the diagnosis. Histopathological lesions of brain and spinal cord and bone would also throw much light in arriving at vitamin A deficiency.

R E F E R E N C E S

- Ackert, J.E., Fisher, M.L.
and Zimmerman, N.B. (1927)
- Ackert, J.E., Mc Ilvaine,
M.F. and Crawford, N. (1931)
- Ahmad, B. (1934)
- Ascarelli, I. and Senger,
M. (1962)
- Beach, J.R. (1924)
- Blain, D. (1928)
- Barron, S.N. (1942)
- Beri, S.P. (1949)
- Biester, H.E. and Schwarte,
L.H. (1957)
- Blount, W.P. (1961)
- Beaverh, D. (1961)
- Bose, S. (1962)
- Carr, F.H. and Price,
E.A. (1926)
- Cruickshank, E.M., Hart, E.B.
and Halpin, J.G. (1927)
- Cruickshank, E.M. (1935)
- Cook, S.F. (1937)
- Chichester, D.F., Russel, W.C.
and Hudson, C.B. (1938)
- Coffin, D.L. (1953)
- J. Parasit., 13, 219.
- Amer. J. Hyg., 13, 320.
- Cite Rosenberg (1945)
- Jour. Sci. Food. Agri., 13, 332.
- Cit. Biester and Schwarte (1957)
- Cit. Olson (1935)
- Vet. Rec., 54, 29.
- Ind. Poult. Gazt., 33, 8.
- Diseases of Poultry, Ames, Iowa,
The Iowa State College Press,
3rd Edi. Rev. Rep.
- Vet. Rec., 73, 1458.
- Amer. J. Path., 38, 335.
- Indian Farm., 11, 41.
- Biochem. J., 20, 498.
- Poult. Sci., 7, 9.
- Cit. Biester and Schwarte (1957)
- Poult. Sci., 16, 291.
- Ibid., 17, 505.
- Manual of Veterinary Clinical
Pathology, Comstock Publishing
Associates, Ithaca, New York.

- Culling, C.F.A. (1957) Hand Book of Histopathological Technique, Butterworth & Co (Publishers) Ltd., London.
- Domm, L.V. and Taber, E. (1946) Cit. Sturkie, P.D. (1954)
- Deo, P.G. and Srivastava, H.D. (1962) Indian J.V.Sci., 32, 54.
- Elvehjem, C.A. and Neu, V.F. (1932) Jour. Biol. Chem., 97, 71.
- Emslie, A.R.G. (1934) Imp. Bur. Anim. Nut. Tech. Com. No. 5. ~~Ann~~
- Emmel, M.W. (1940) Abst. Indian J. Vet. Sci., 5, 404.
- Forkner, C.E. (1929) J. Amer. Vet. Med. Asso., 27, 145.
- Follis, S.R. (1948) Jour. Exp. Med., 1, 121.
- Ferrando, R. and Vullierme, N. (1958) The Pathology of Nutritional Disease, Charles C Thomas, Illinois.
- Grasovsky, V.S. (1932) Rec. Med. Vet., 134, 665.
- Guilbert, H.R. and Hart, G.H. (1934) Abst., Nut. Abst., 29, 802.
- Gray, E.L., Hickman, K.C.D. and Brown, E.F. (1940) The Vet. Jour., 88, 118.
- Gibson, W.W.C. (1960) J. Nut., 8, 25.
- Hart, E.B., Miller, W.S. and Mc Collum, E.V. (1916) Ibid., 19, 39.
- Hughes, J.S., Lienhardt, H.F. and Aubel, C.E. (1929) Vet. Rec., 72, 971.
- Jour. Biol. Chem., 25, 239.
- J. Nut., 2, 183.

- Heller, V.G. and Paul, H. (1934) Cit. Schalm, O.W. (1961)
- Hill, F.W., Scott, M.L., Norris, L.C. and Heusen, G.F. (1961) Poult. Sci., 40, 1245.
- Hungerford, T.G. (1961) Aust.Vet.Jour., 37, 93.
- Hawk, P.B., Oser, B.L. and Summerson, W.H. (1954) Practical Physiological Chemistry, Mc Graw - Hill Book Company Inc. 13th Ed.
- Iyer, S.G. and Mukherjee, R. (1947) Indian Poult. Gazt., 31, 22.
- Iyer, S.G. (1948) Indian Farm., 9, 335.
- Jungherr, E. (1945) Poult. Sci., 24, 112.
- Kyes, P. (1929) Cit. Olson (1935)
- Kehar, N.D., Sawhney, P.C. and Bahl, A.N. (1956) Proc. 43rd. Indian Sci. Congr., Sec-IX, 357.
- Lindley, C.E., Brugman, H.H., Cunha, T.J. and Warwick, E.J. (1949) J. Anim. Sci., 8, 590.
- Lillie, R.D. (1948) Histopathological Technique, Philadelphia, The Blackiston Company.
- Mc Collum, E.V. and Davis, M. (1915) J. Biol. Chem., 23, 181.
- Mason, K.E. and Ellison, E.T. (1935) J. Nut., 9, 735.
- McDonald, A.J. (1944) Indian Poult. Gazt., 27, 11.
- Maynard, L.A. and Loosli, J.K. (1956) Animal Nutrition, McGraw-Hill Book Company, Inc., New York. 4th Ed.
- Mahadevan, V., Basudevan, B. and Dutt., B. (1962) Indian Vet.J., 39, 315.

McCuNu, E.L., Savage, J.E.
and O'Dell, B.L. (1962)

Norris, L.C. (1941)

Niesar, K.H. (1955)

Nambiar, K.T.K. and
Govindan, K.N. (1962)

Osborne, T.B. and Mendel,
L.B. (1915)

Orr, J.B. and Richards,
M.B. (1934)

Olson, C. (Jr.). (1935)

Olson, C. (1937)

Pande, P.G. and
Krishnamurty, D. (1959)

Paul, A.K., Chand, R. and
Chakraborty, B.C. (1960)

Panda, B. (1962)

Russel, W.C. and Morris,
M.L. (1939)

Roach, R.W. (1943)

Rosenberg, H.R. (1945)

Rigdon, R.H. (1952)

Seifried, O. (1930)a

----- (1930)b

Sen, K.C. and Sharma, G.K.
(1936)

Seifried, O. (1938)

Poult. Sci., 41, 265.

J. Am. Vet. Med. Ass., 98, 200.

Cit. Annl. Rev. Biochem., 25, 500.

Indian Vet. J., 39, 442.

J. Biol. Chem., 20, 379.

Biochem. J., 28, 1259.

J. Am. Vet. Med. Ass., 39, 474.

Cornell. Vet., 27, 235.

Poult. Sci., 38, 13.

Proc. Indian Sci. Cong., Sec. II,
571.

Indian Vet. J., 39, 325.

J. Am. Vet. Med. Ass., 95, 316.

Vet. Rec., 55, 265.

Chemistry and Physiology of
vitamins, Inter Science Publishers,
Inc. New York, Rev. Rep.

Arch. Path., 53, 238.

Jour. Exp. Med., 52, 519.

Ibid., 52, 533.

Indian J. Vet. Sci., 6, 128.

Berl. Munch. tierarztl. Wschr.,
Nov. 25th, 720.

Abst., Vet. Bull., 10, 49.

Seifried, O. (1939)

Proc. Seventh World Poultry
Congr., 291.

Abst., Vet. Bull., 10, 864.

----- and
Koehler, E. (1942)

Z. Infektkr. Haustiere., 59, 32.

Abst., Ibid., 17, 329.

Scorgie, N.J. (1938)

Vet. Rec., 50, 775.

Sturkie, P.D. (1954)

Avian Physiology.
Comstock Publishing Associates,
Ithaca, New York.

Sheldon, H. and
Zetterquist, H. (1956)

Cit. Annl. Rev. Biochem., 26, 280.

Taylor, M.W. and Russel,
C.W. (1947)

Poult. Sci., 26, 234.

Wolbach, S.B. and Howe,
P.R. (1925)

Jour. Exp. Med., 42, 753.

Wiseman, B.K. (1931)

Cit. Olson (1935)

Wickle, H.L. (1933)

Indian J. Vet. Sci., 83, 635.

Wolbach, S.B. and Bessy,
O.A. (1941)

Arch. Path., 32, 689.

----- (1942)

Physiol. Rev., 22, 233.

Wolbach, S.B. and Hegsted,
D.M. (1952)

Arch. Path., 54, 13.

Wintrobe, M.M. (1942)

Clinical Haematology, Lea and
Febiger, Philadelphia. 1st Ed.