

ANATOMY OF FEMALE REPRODUCTIVE ORGANS IN DOMESTIC ANIMALS

Prof G N PUROHIT

Head, Department of Veterinary Gynecology and
Obstetrics, College of Veterinary and Animal
Science, Rajasthan University of Veterinary and
Animal Sciences, Bikaner, Rajasthan, India

REPRODUCTIVE ORGANS

– GENERATIVE ORGANS (OVARIES)

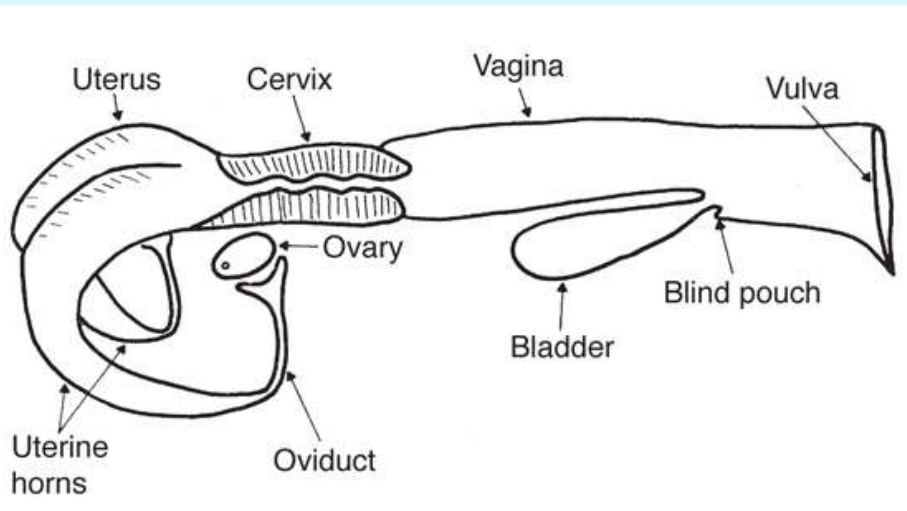
– TUBULAR GENITALIA – OVIDUCTS

- UTERINE HORNS

- CERVIX

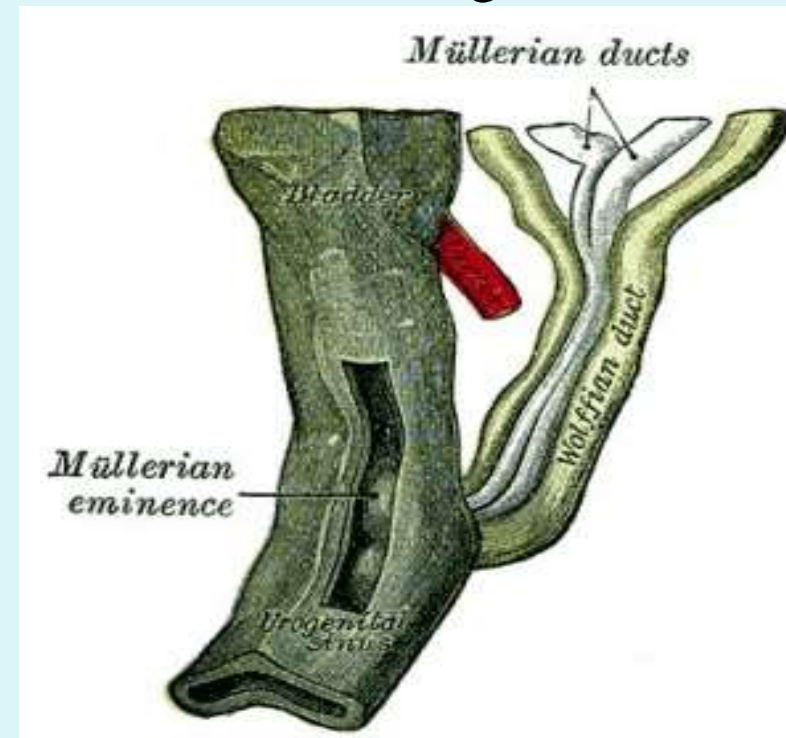
- VAGINA

- EXTERNAL GENITALS



Embryonic Origin

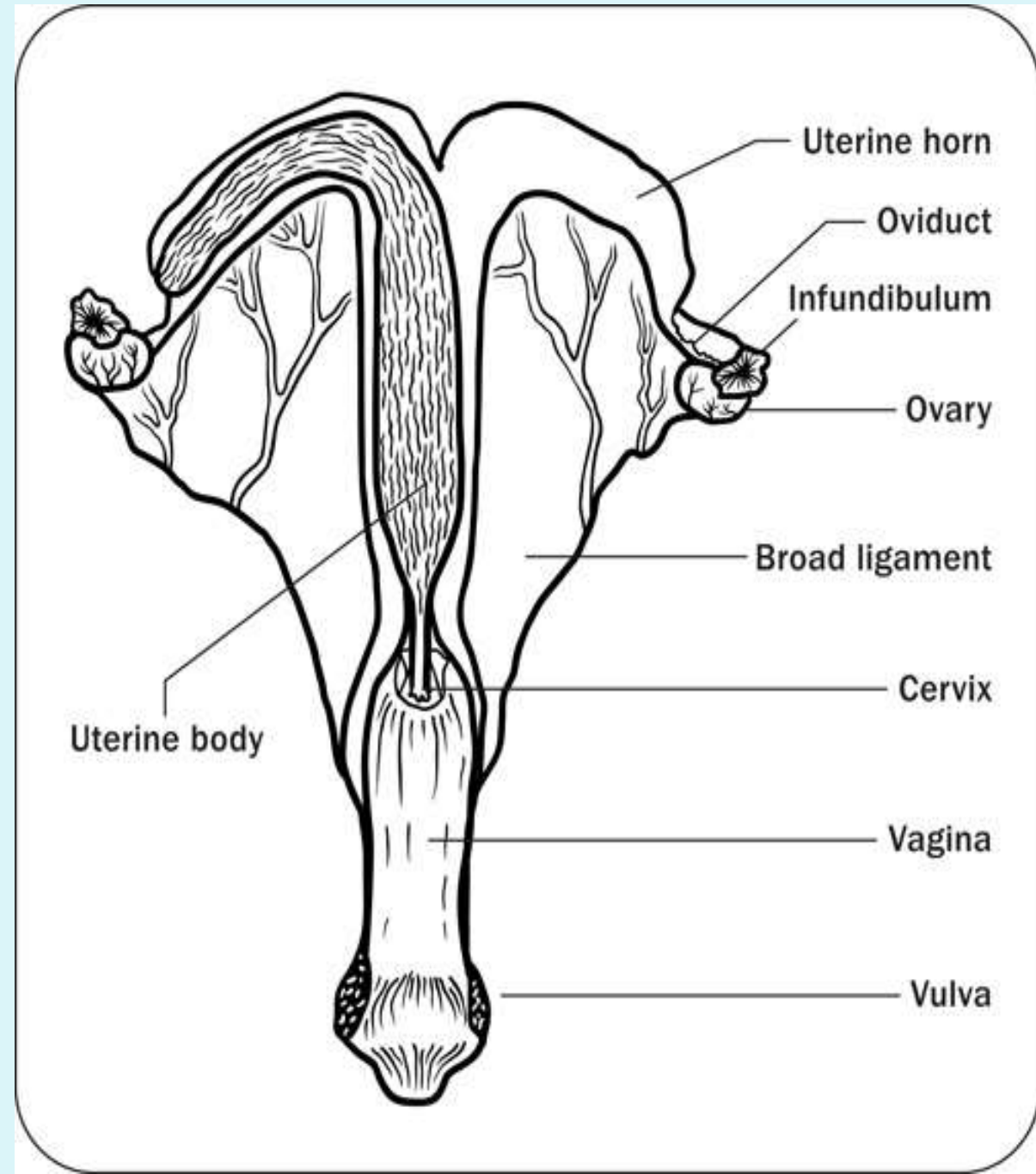
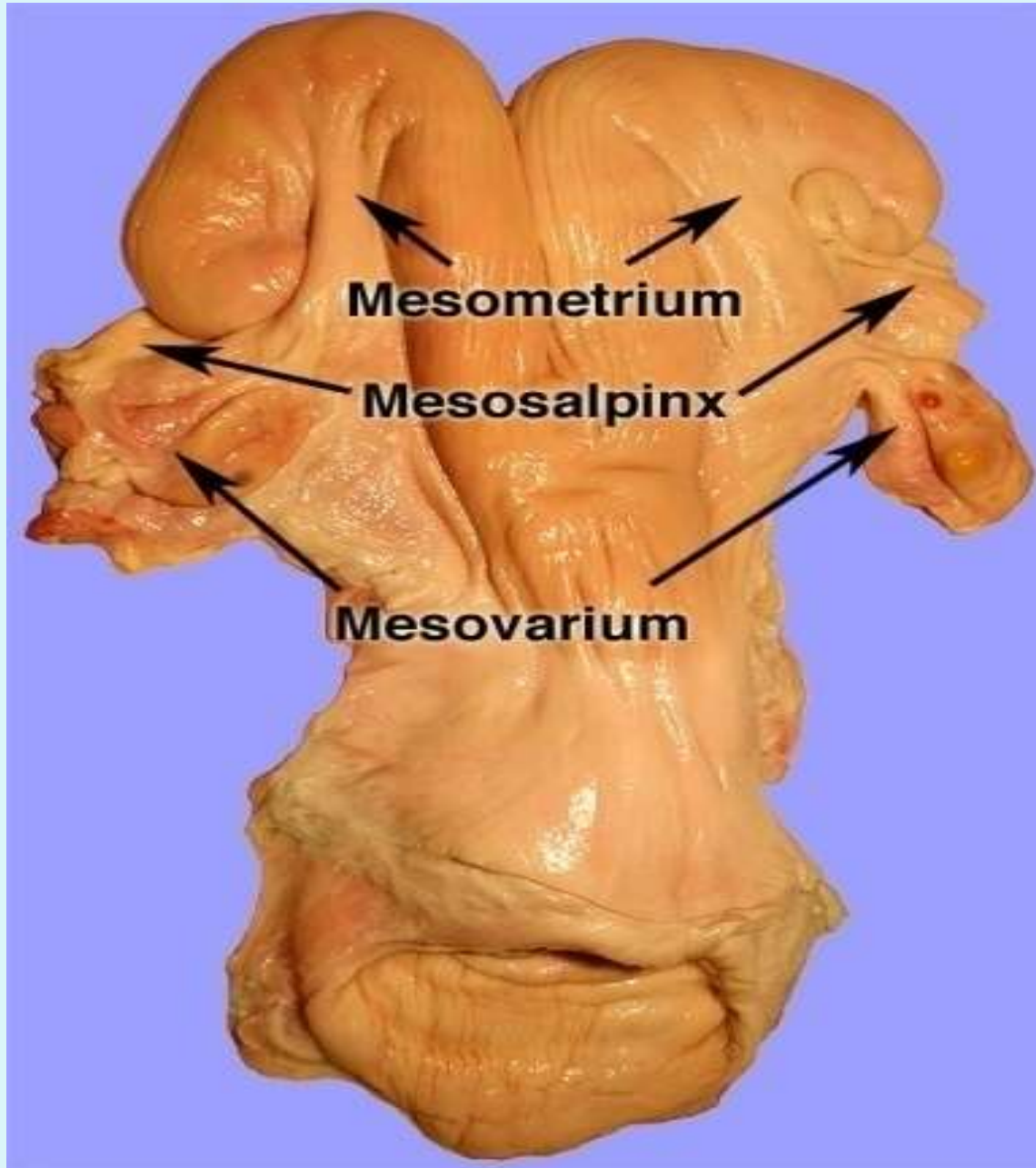
- The male and female reproductive systems develop initially embryonically "indifferent", it is the product of the Y chromosome SRY gene that makes the "difference".
- The paired **mesonephric ducts** (Wolffian ducts) and **paramesonephric ducts** (Müllerian ducts) contribute the majority of male and female internal genital tract respectively.
- The ovaries, oviducts, uterus, cervix and the cranial portion of vagina arise from the primitive Müllerian or the Paramesonephric ducts
- The vulva, vestibule and the caudal portion of the vagina develop from the urogenital sinus.



- Female reproductive tracts of various farm animals are similar to the cow, but differ primarily in the shape of the different structures like uterus, cervix, ovaries etc.

Attachments

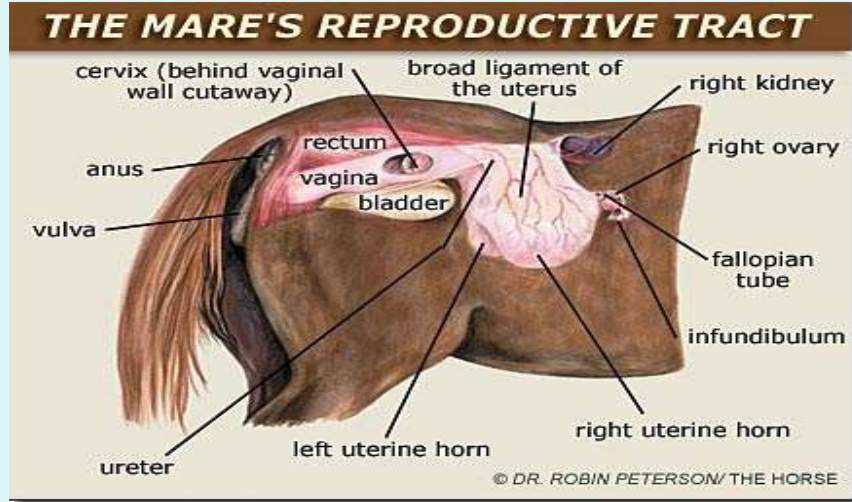
- The genital tract is held in place on one side by the muscles and ligaments of vagina, vestibule and vulva (constrictor vestibuli, constrictor vulvae etc,) and suspended in the pelvic cavity by the broad ligament.
- **Broad ligament** The broad ligament is the suspensory connective tissue attachment that originates from the peritoneum (containing blood vessels, lymphatic's and nerves) that hold the uterus, ovaries and oviduct. Parts of the broad ligament attached to the ovaries, oviduct and uterus are called meso-ovarium, mesosalpinx and mesometrium respectively.



Broad ligament

- **Structural characteristics**
- **Meso-ovarium** Houses vascular supply, lymphatic's, and nerves to ovary. Forms hilus or attachment to ovary
- **Mesosalpinx** Thin tissue that supports the oviduct and helps orient infundibulum around ovary to direct oocytes into oviduct. In the bitch, the mesosalpinx encloses the ovary forming a bursa around the ovary.
- **Mesometrium** The largest part of the broad ligament that supports the uterine horns and (or) uterine body. It is continuous with the dorsal peritoneum and hangs from the dorsal body wall.

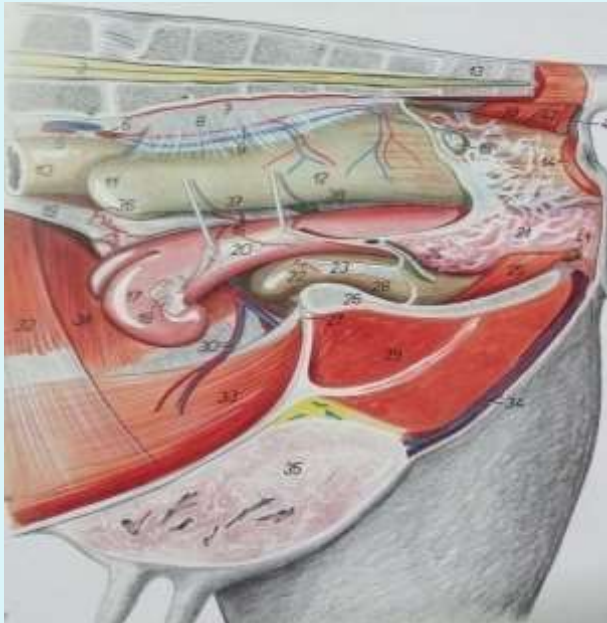
Mesometrium attaches



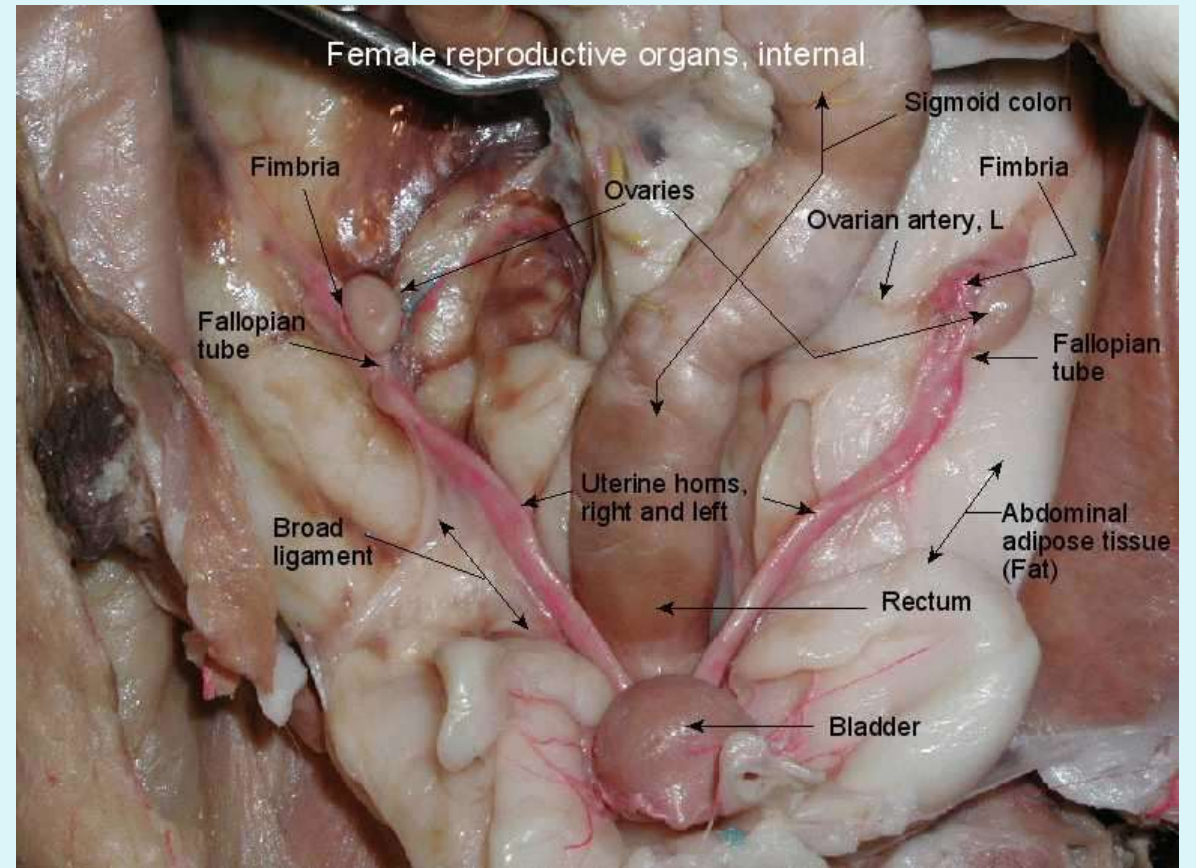
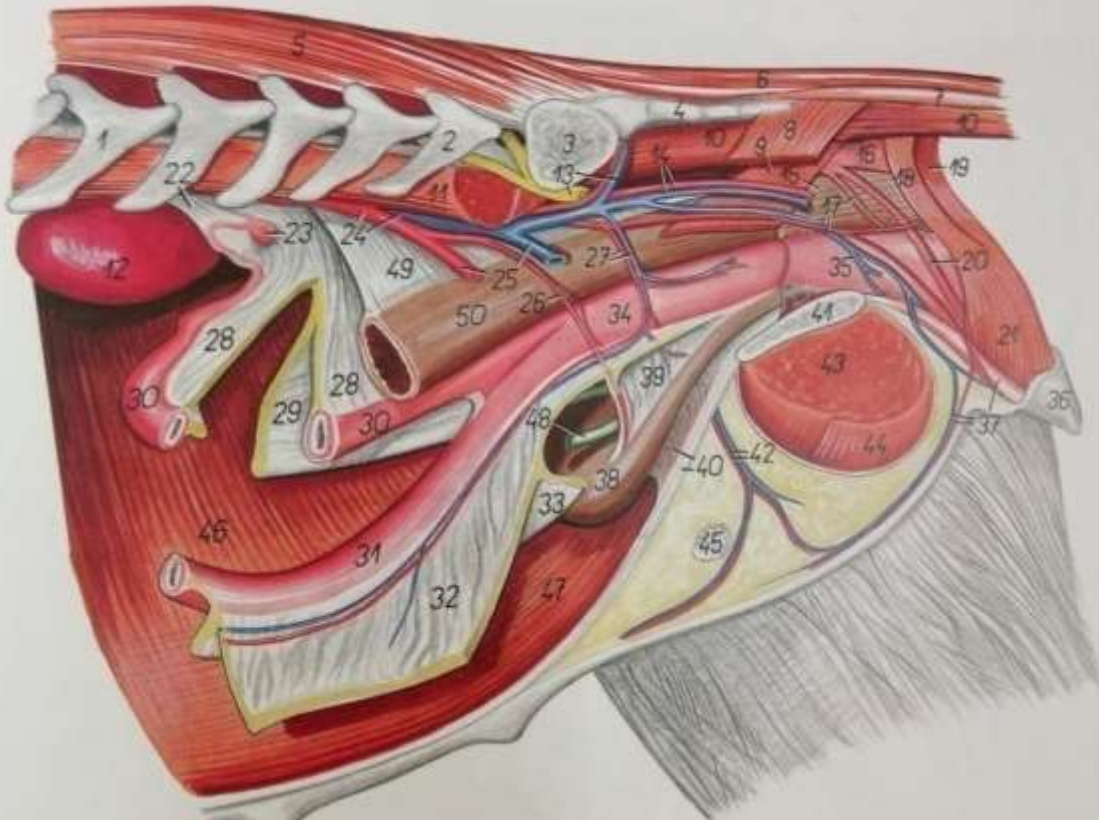
→ dorsal surface of the uterine horns
in mare therefore in the mare the free (unattached) surface of the uterus is ventral to the broad ligament whereas in cattle the free surface is dorsal to the broad ligament

→ ventrolateral surface in cow and sheep.

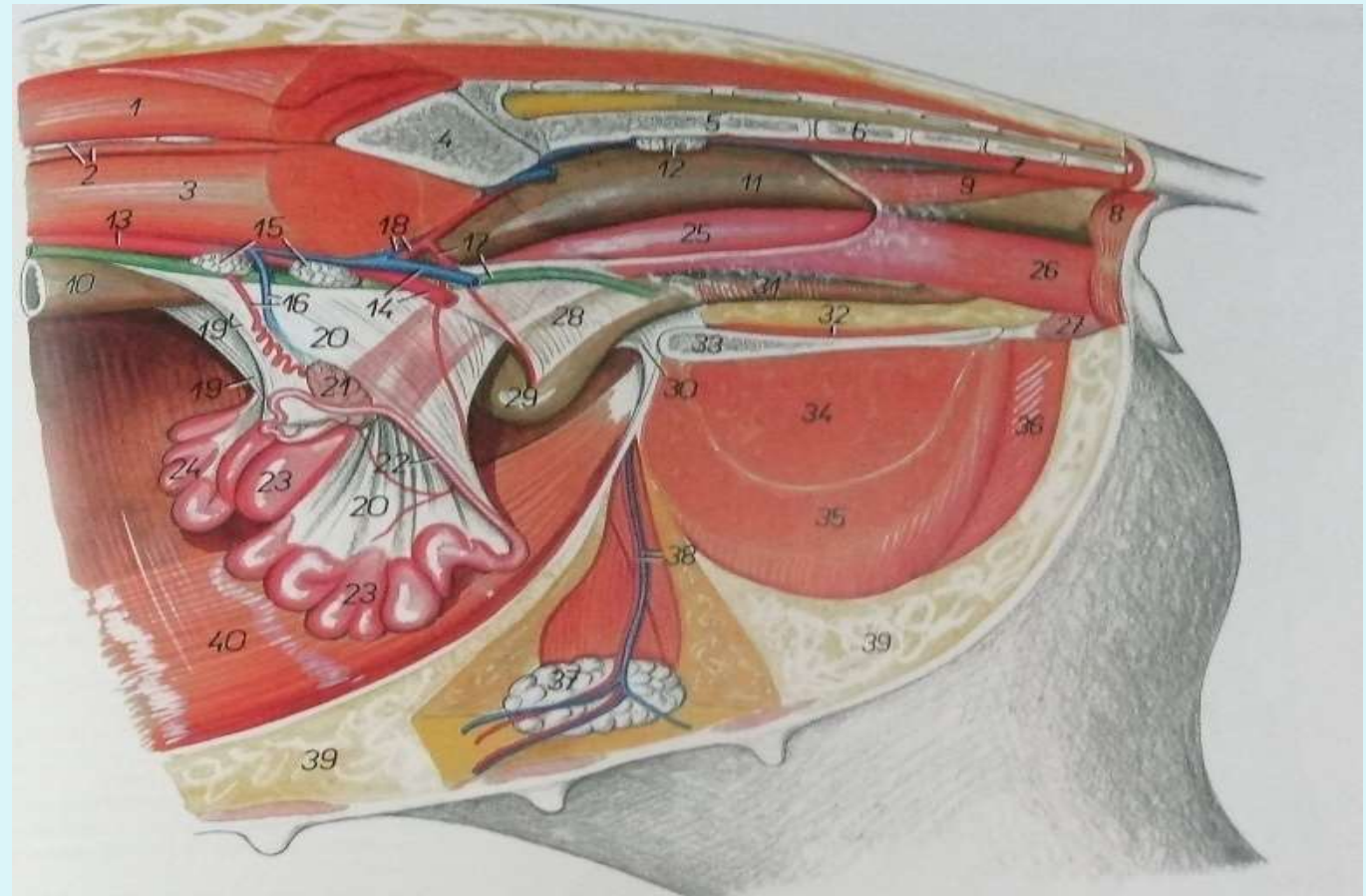
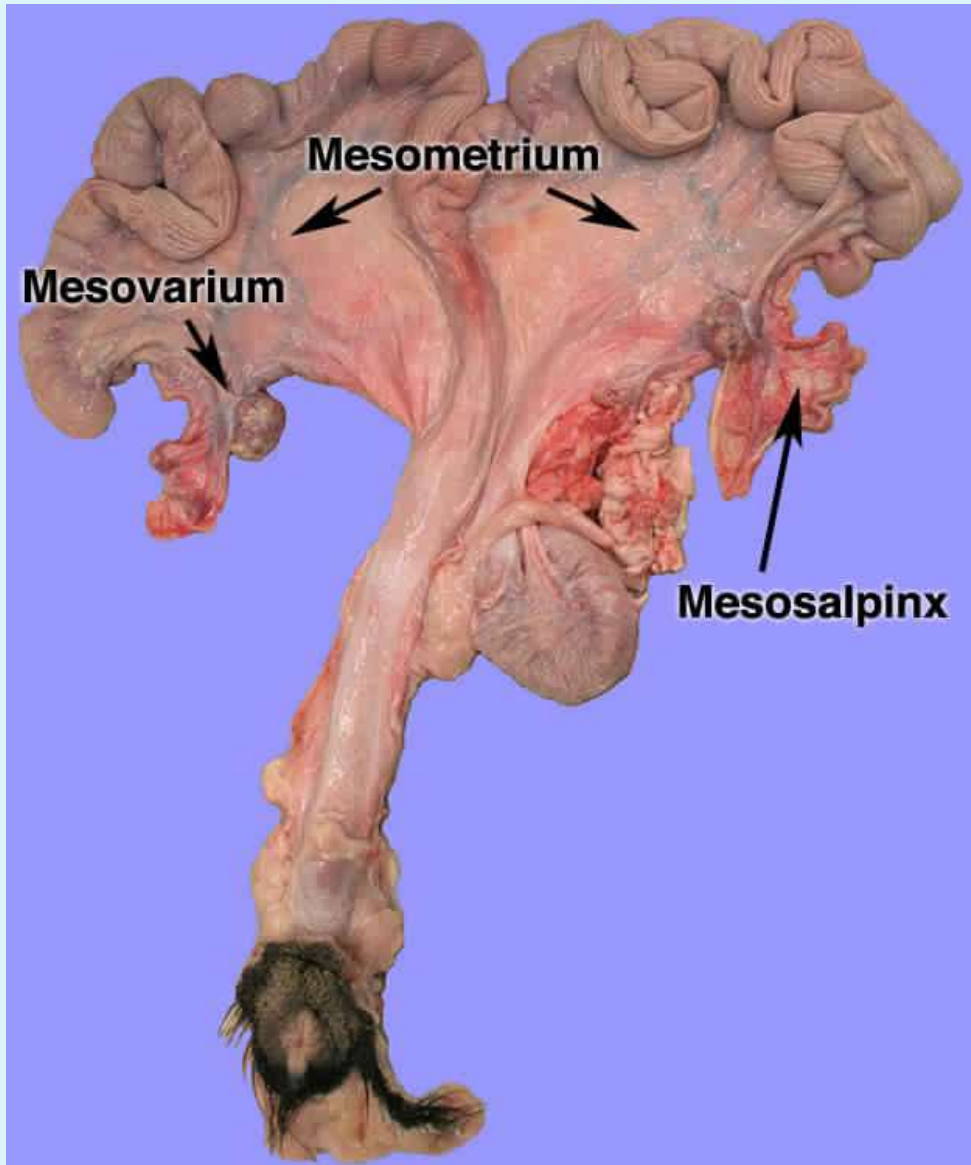
→ Bitch mesometrium has fat and rest on the coils of jejunum and there are round ligaments additionally.



In the bitch the ovarian attachments include the proper and suspensory ligaments (which originate from the last rib).



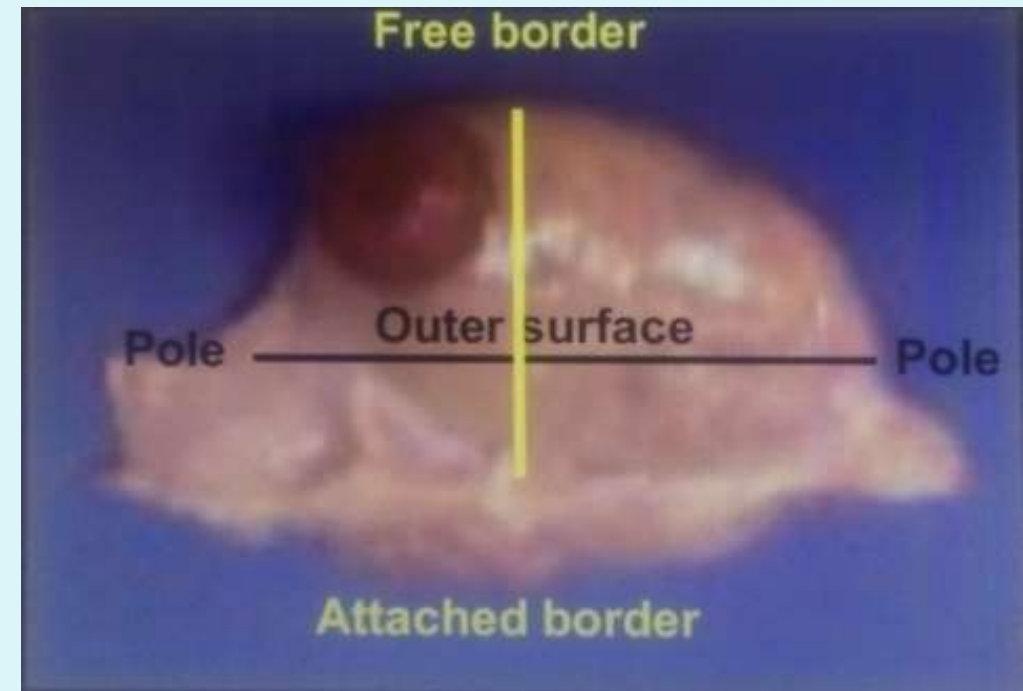
Broad ligaments of the sow



Generative organs

- **The Ovaries are the generative organs**
- **Almond-shaped in most species - Bean-shaped in horse – Mulberry-shaped in the sow**

Ovaries are the primary reproductive organs performing both exocrine and endocrine functions. Each ovary has two surfaces (medial and lateral) 2 borders (attached and free border) and 2 poles (uterine and tubal) The ovary consists of the cortex (outer layer) and medulla (inner layer). The ovaries are attached by the broad ligament and the proper ligaments



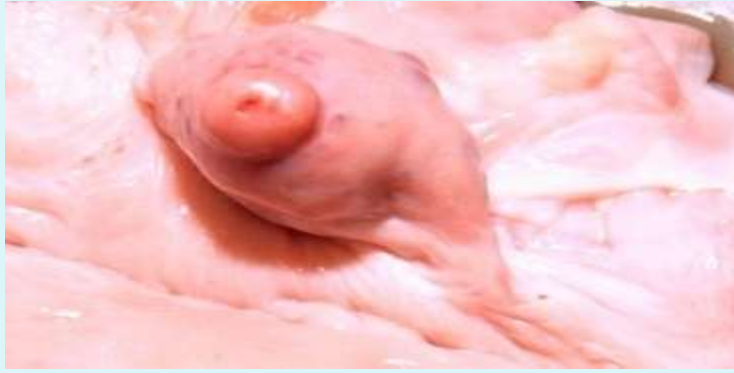Ovarian migration during development

- In the **dog and cat**, ovaries do not migrate in development. They remain in the dorsal part of the abdomen, caudal to the kidneys at the tip of the uterine horns.
- In other domestic species, the ovaries migrate during development.
- The greatest degree of migration occurs in **ruminants**. Here, the ovaries come to lie close to the ventral abdominal wall, cranial to the pelvic inlet.
- In the **pig**, they descend to the middle of the abdomen.

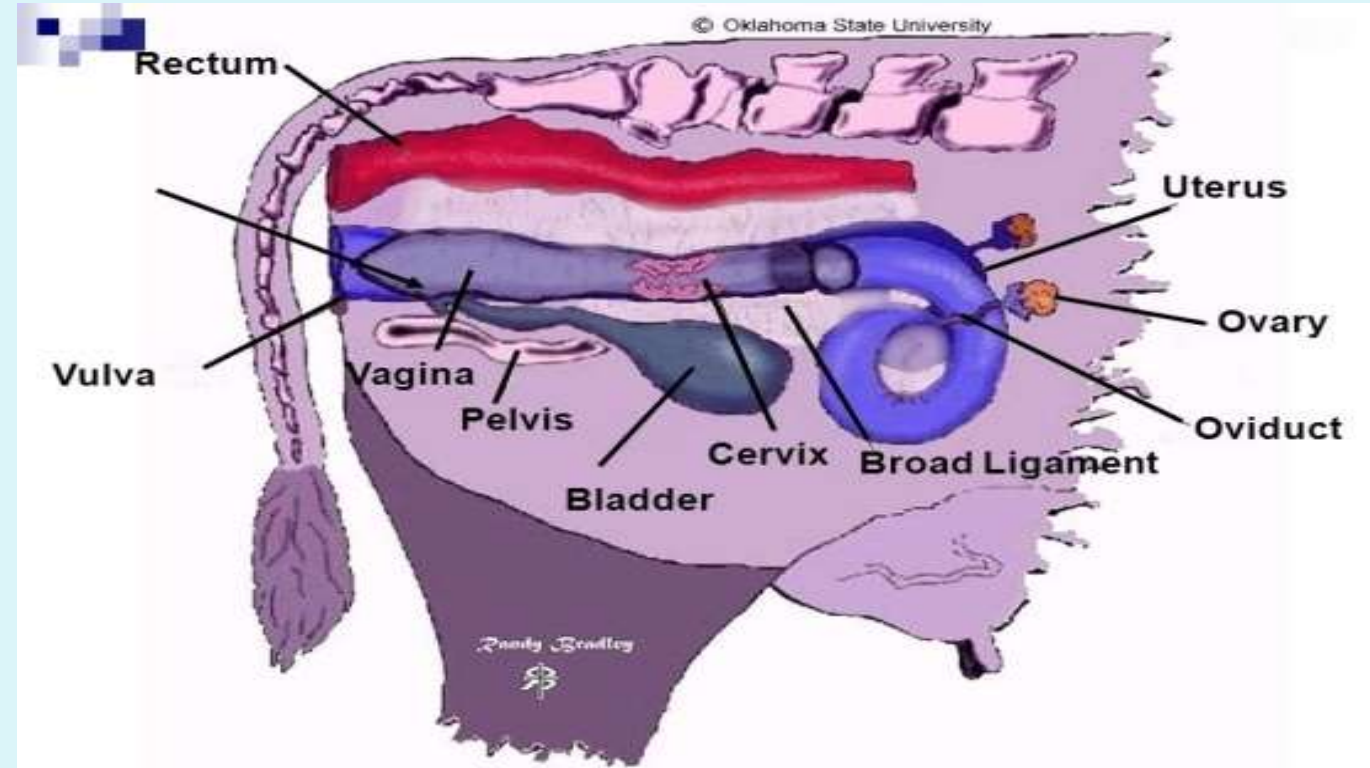
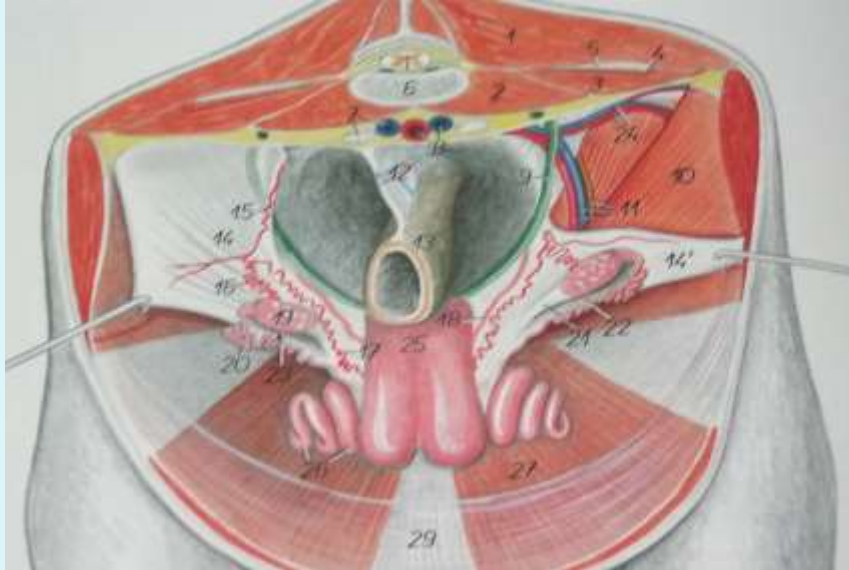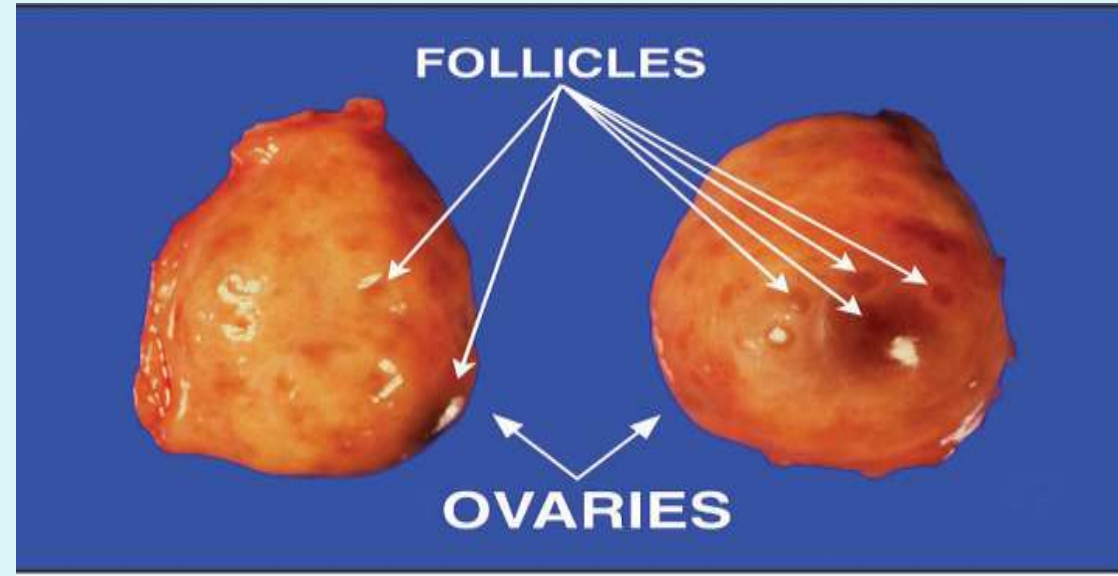
Ovarian location and layers

- The ovaries consist of a stroma or network of connective tissue and blood vessels surrounded by a covering of peritoneum except at the attached border or **hilus** where the vessels or nerves enter.
- The ovary is an ovoid structure in the cow that can be divided into the outer **cortex** and the inner **medulla**.
- In the mature mare, these areas are reversed. The cortical tissue in this case remains on the surface only in the **ovulation fossa** that is the location of all ovulations.
- The bovine ovaries are located on the cranial border of the broad ligament. They lie on both sides of the uterine horns parallel to the cervix over the pelvic floor. In some older cows they may have a abdominal location. They are round to almond shaped. Ovaries of sheep, goat and buffalo are similar except with differences in size

- The right ovary is slightly larger than the left in cattle since the right ovary is physiologically more active.
- The location of the ovaries becomes abdominal during pregnancy.
- The pocket formed by the utero-ovarian ligament and mesovarium is called the ovarian bursa.



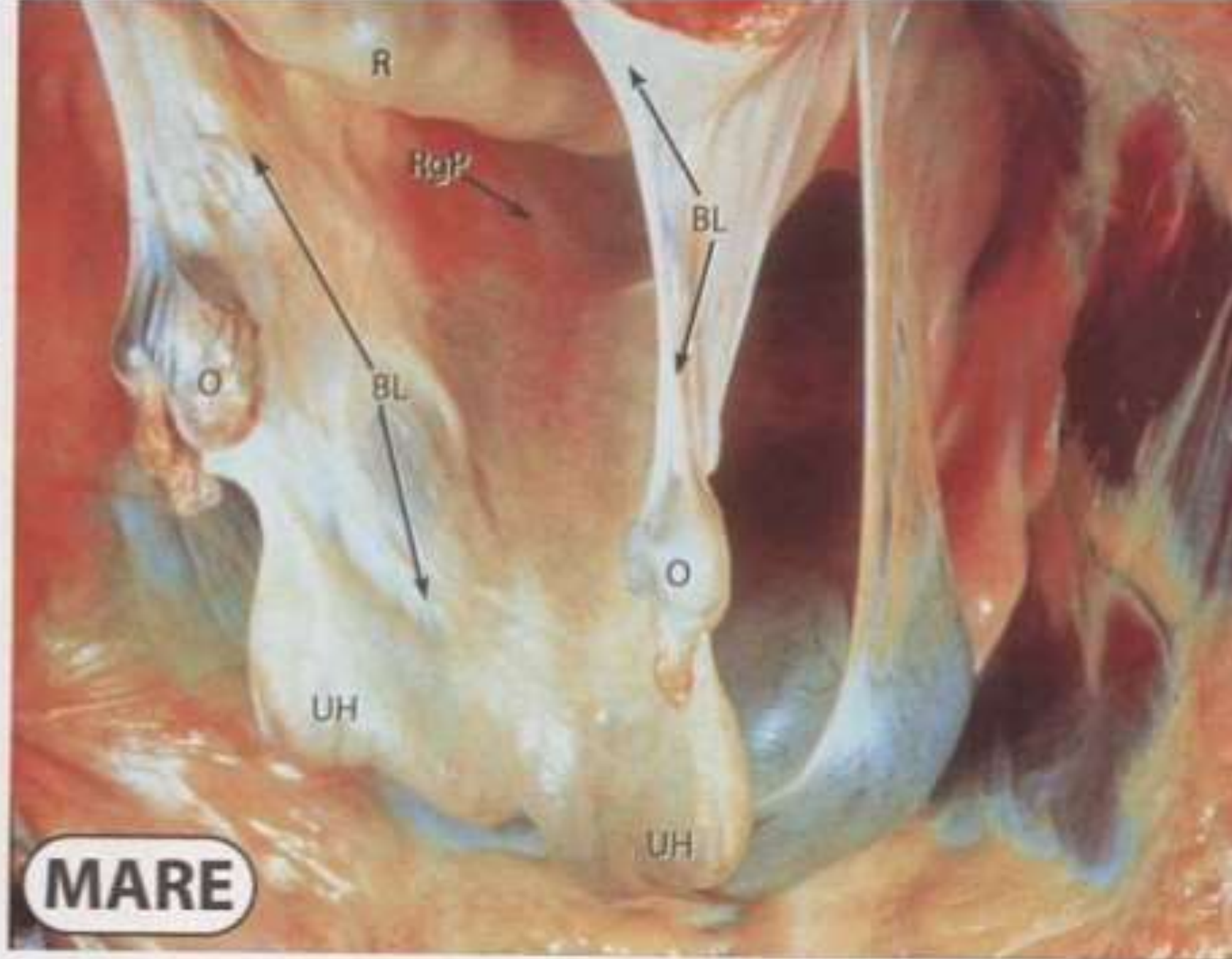
Bovine

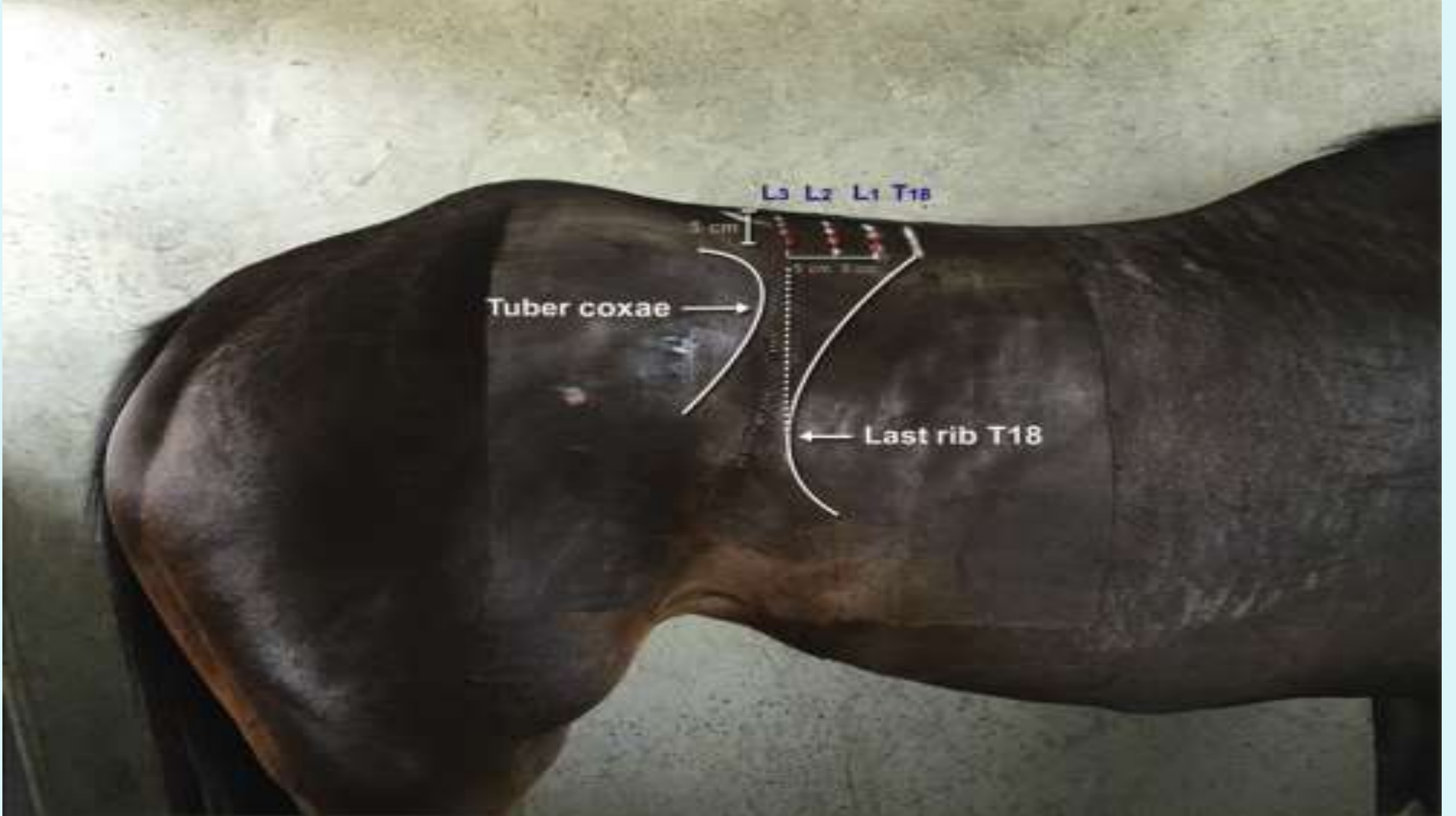


Mare

- In the mare the ovaries are located in the sublumbar area (ventral to the fourth or fifth lumbar vertebra) craniolateral to the iliac wings and several centimeters behind the kidneys.
- The ovaries of the mare are kidney shaped and the surface is smooth.
- The ovaries are suspended in the abdominal cavity by the mesovarium of the broad ligament.
- Follicles can be identified by transrectal palpation, but Corpora Lutea cannot. Identification of Corpora Lutea requires ultrasonography

- BL = Broad Ligament
- CX = Cervix
- IcL = Intercornual Ligament
(out of view.)
- O = Ovary
- OD = Oviduct
- R = Rectum
- RgP = Rectogenital Pouch
- UH = Uterine Horn





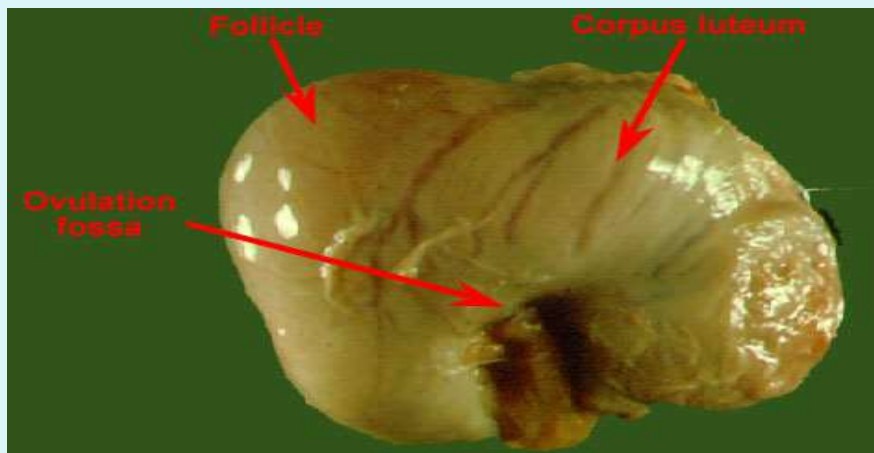
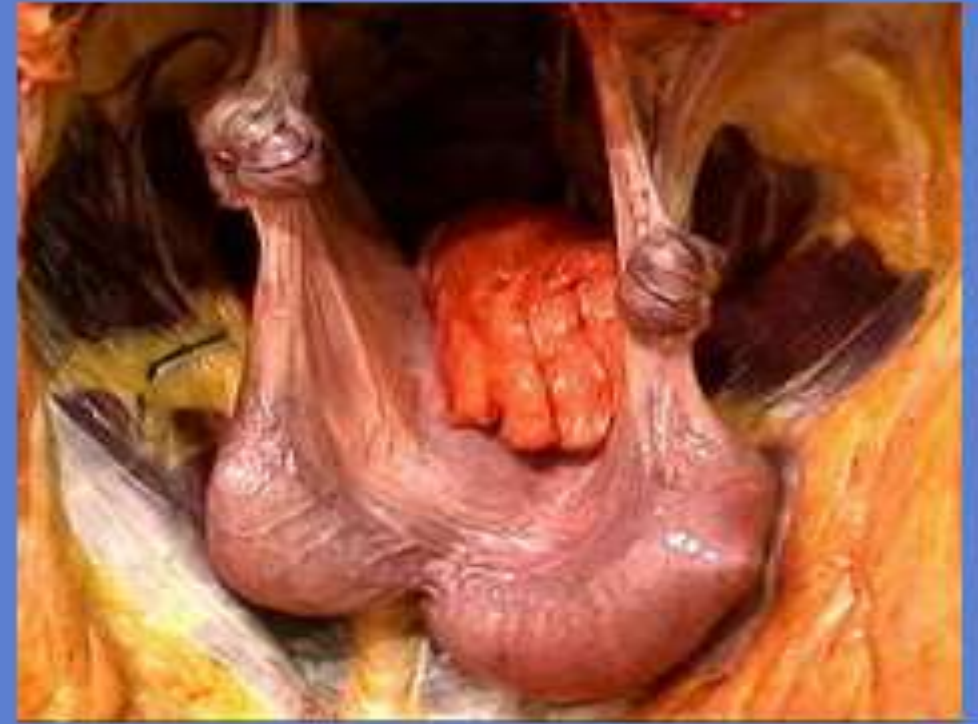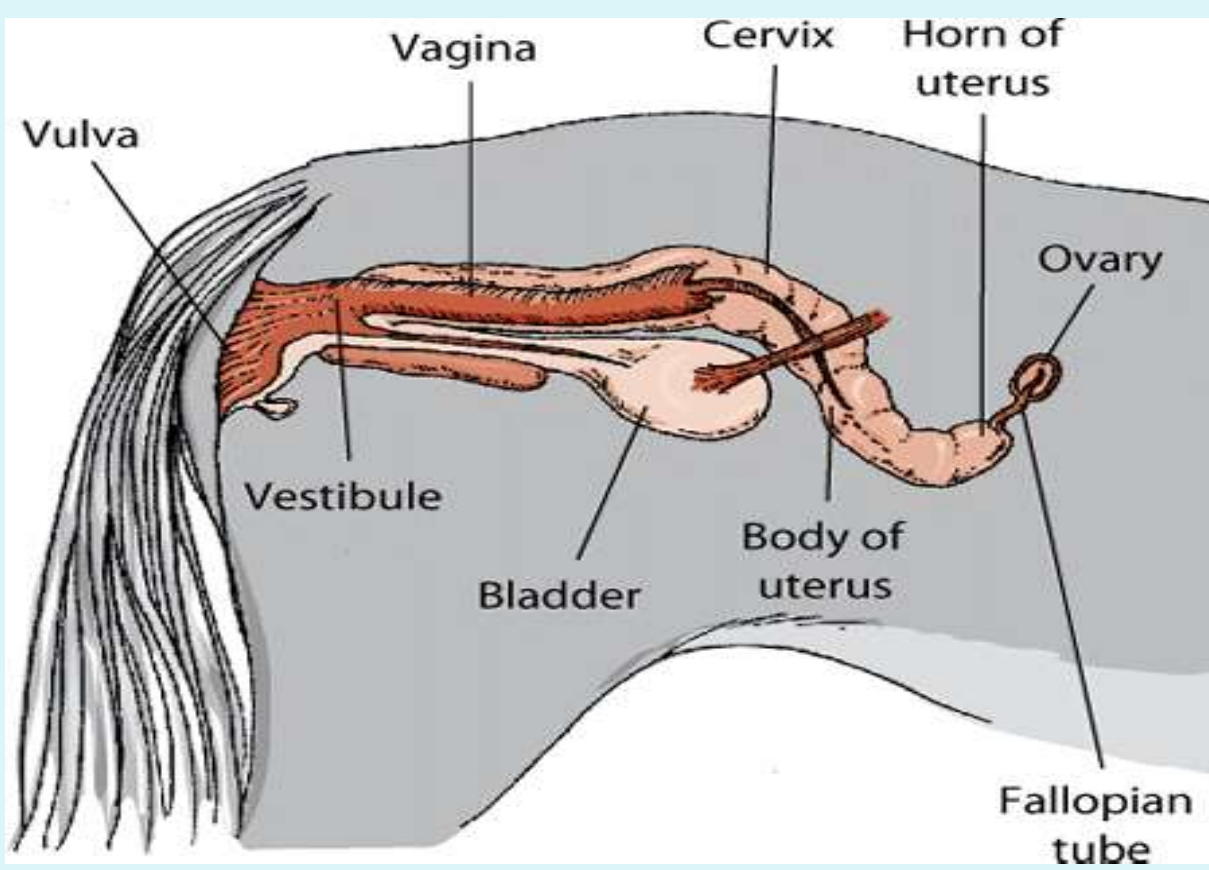
L3 L2 L1 T18

3 cm

5 cm 3 cm

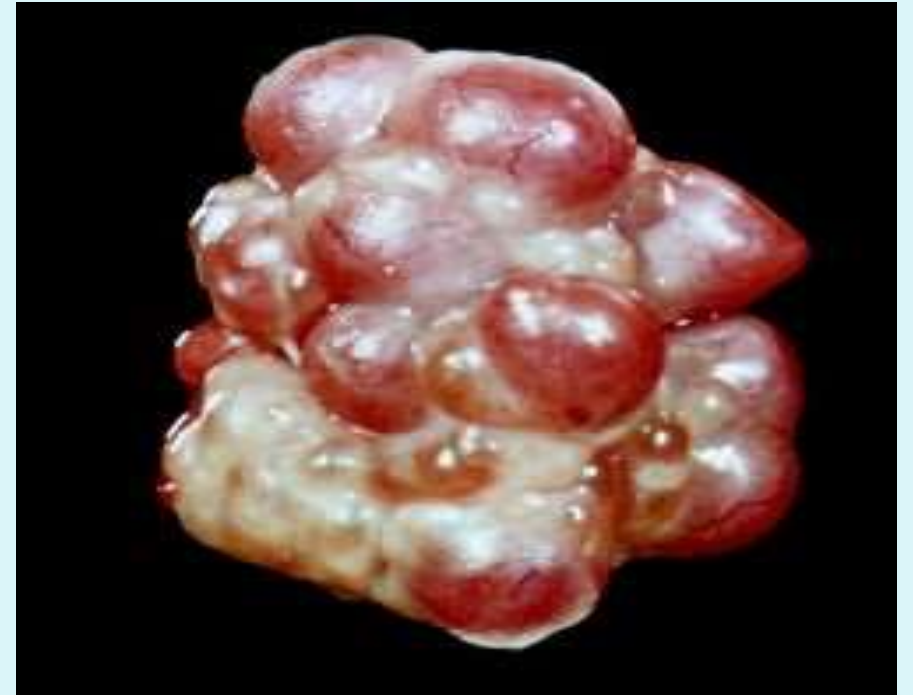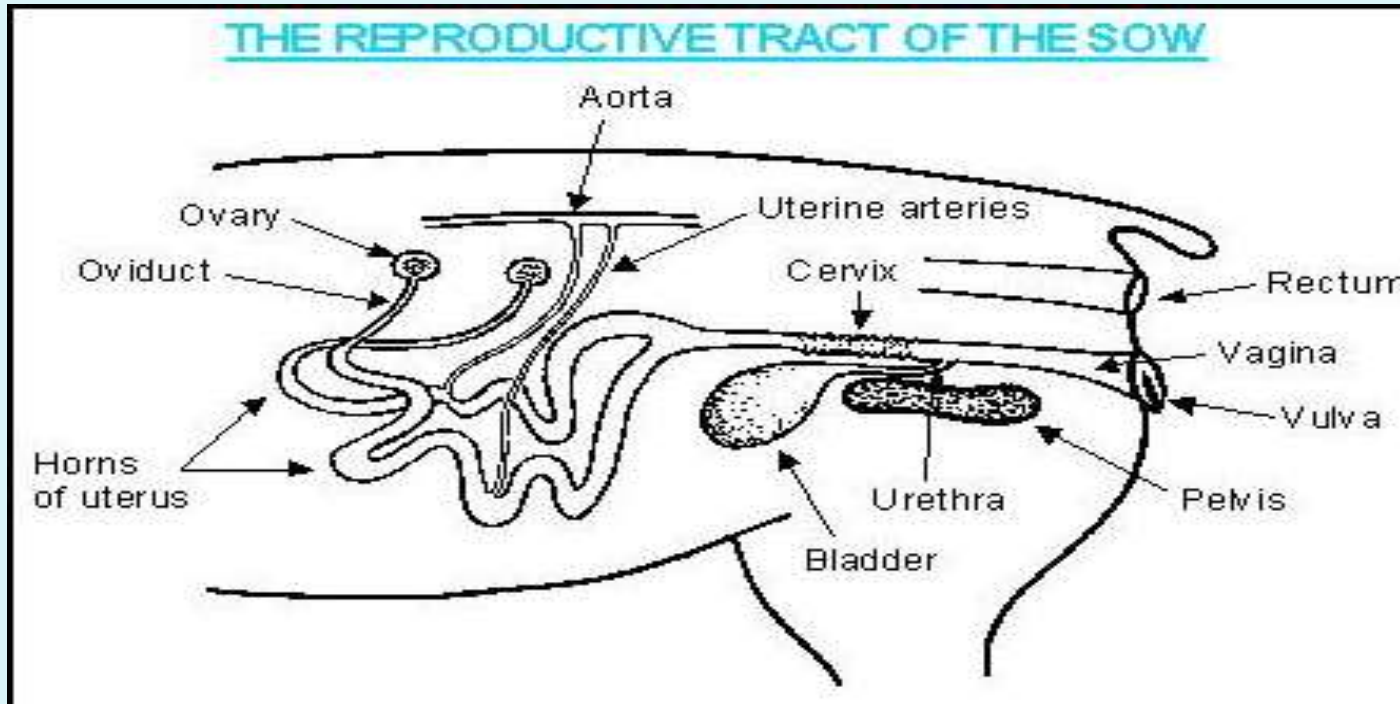
Tuber coxae

Last rib T18



Sow

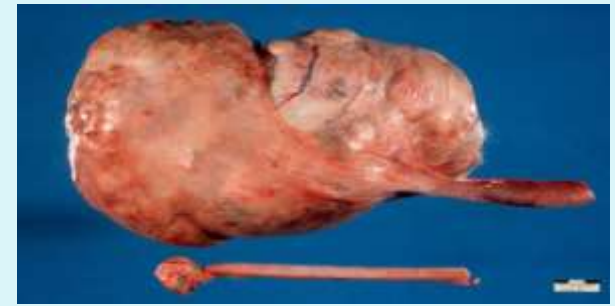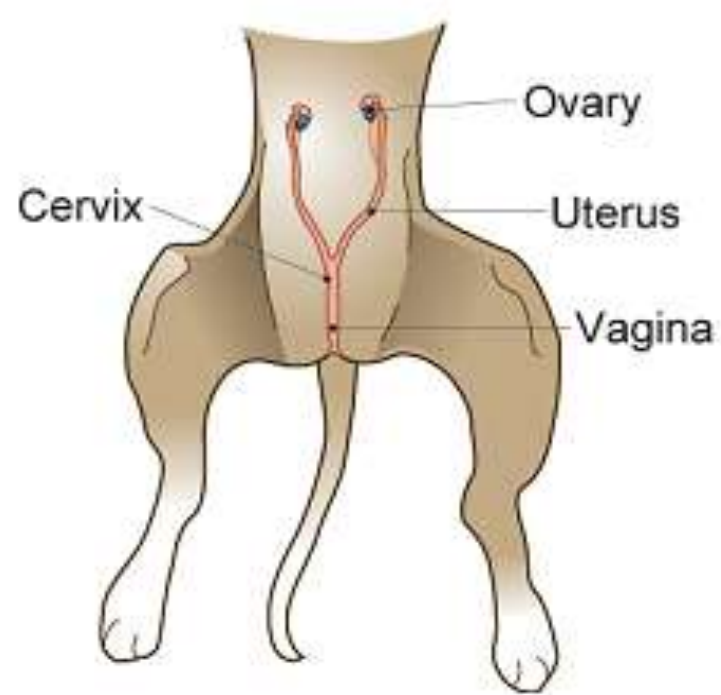
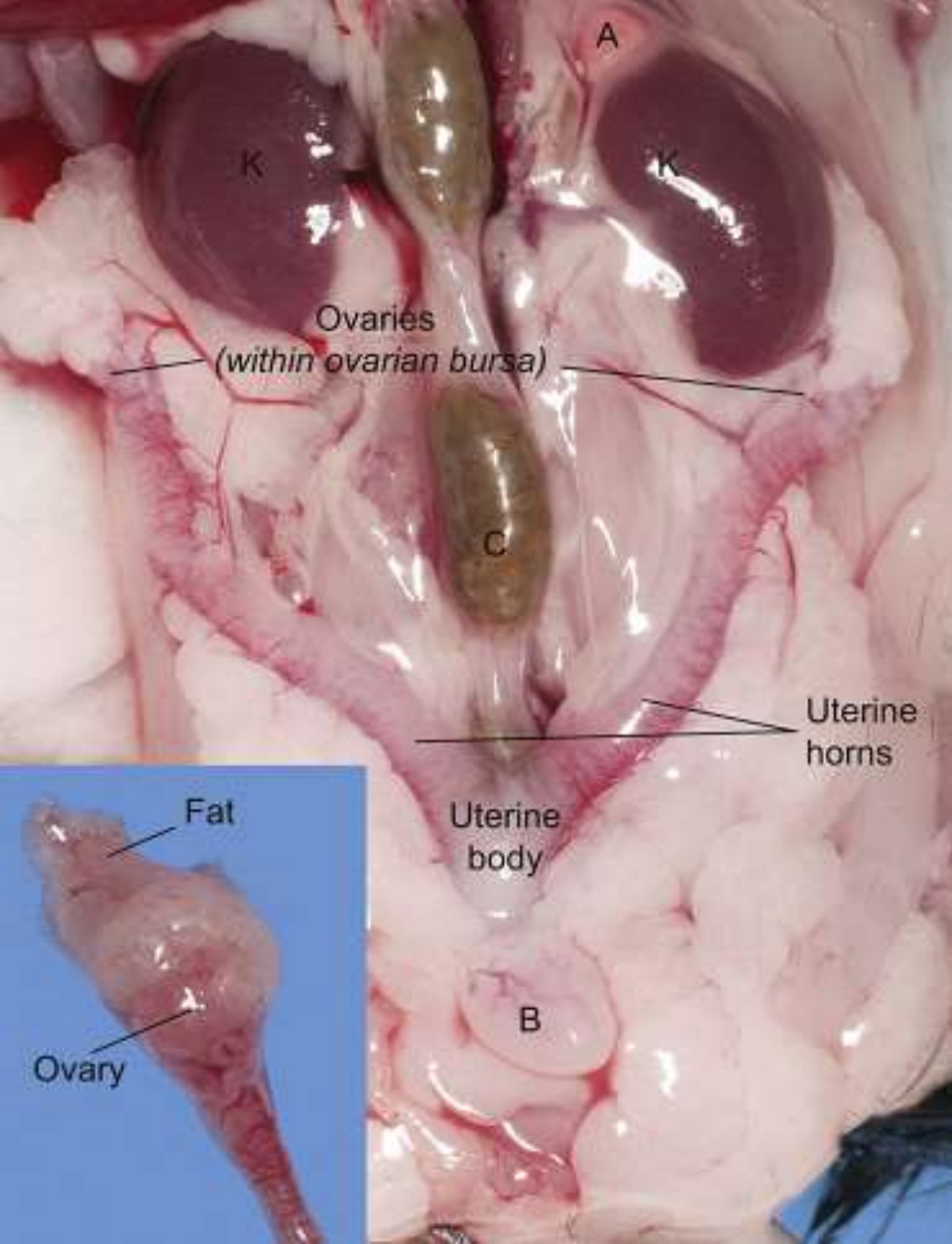
- In the sow the ovaries are located behind the kidneys near the lateral margins of the pelvic inlet.



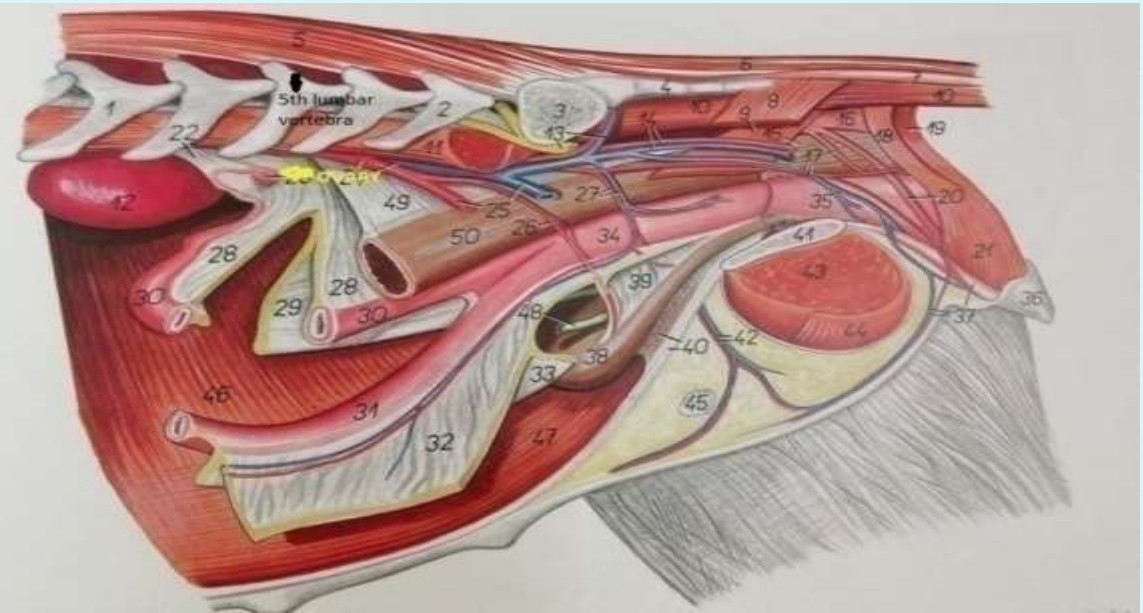
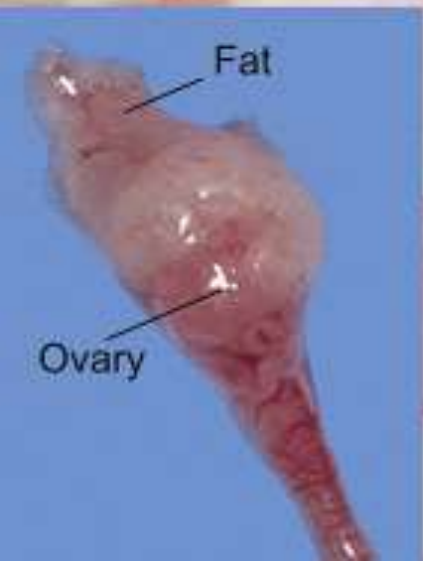Bitch

- In the bitch the ovaries are located 1-3 cm behind the caudal pole of kidneys opposite 3rd lumbar vertebra between the last rib and crest of ileum.
- They are concealed in a bursa with a 0.6-2.0 cm slit. Ovaries are elongated and flat.
- The ovary is attached cranially to the diaphragm in the region of the last rib by suspensory ligament and the uterine end is attached by a very short proper ligament to the tip of the uterine horn

In a sexually mature, 11.4-kg dog, the left ovary is located approximately 12 cm caudal to the middle of the 13th rib and 1 to 3 cm caudal to the corresponding kidney. The right ovary is located approximately 10 cm caudal to the last rib of the right side.



Reproductive Anatomy



1Cm

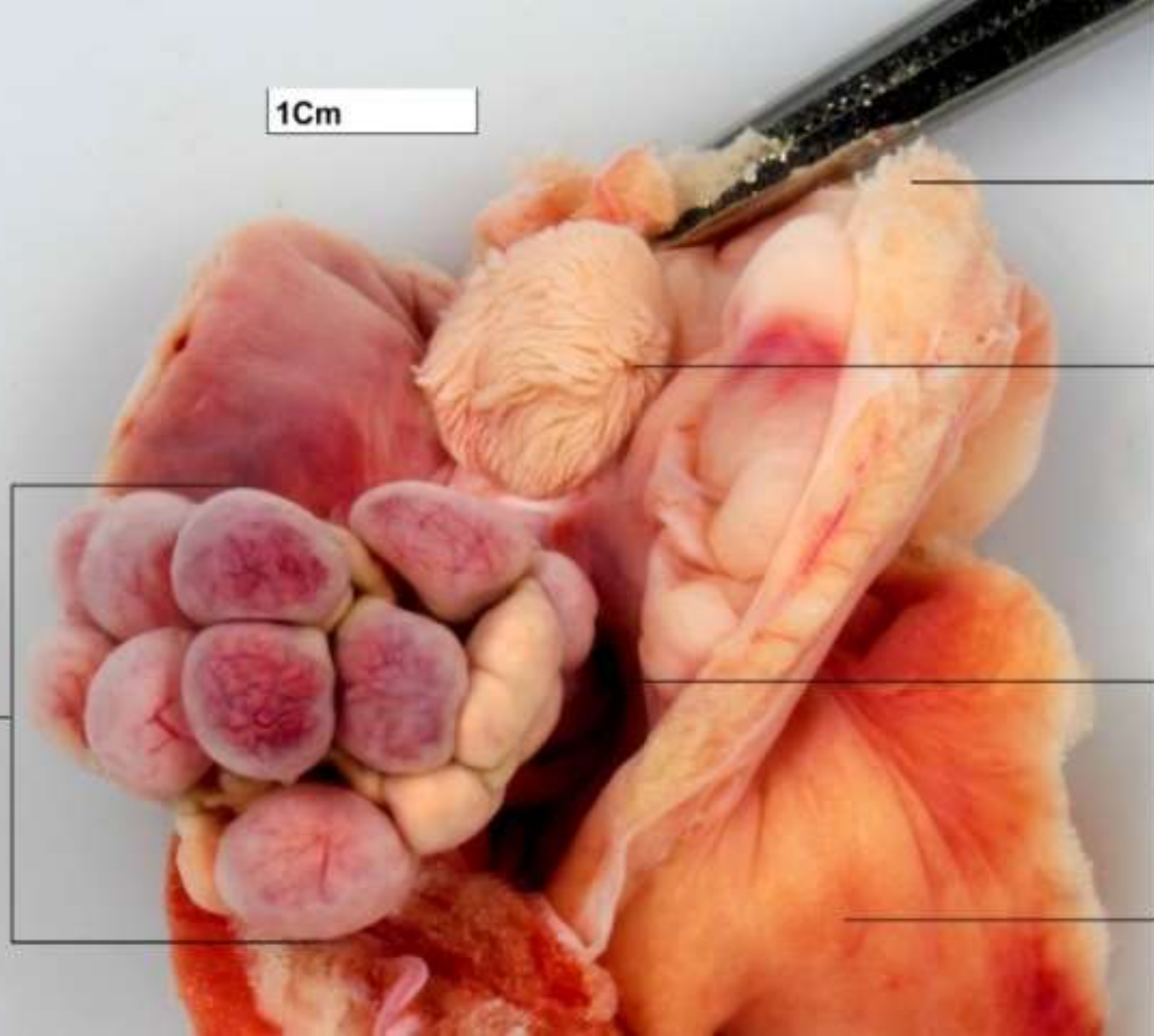
Cut margin
of bursa (opened
to expose ovary

Ostium of
infundibulum,
surrounded
by folds of the
infundibulum

Interior of
the ovarian
bursa

Left uterine horn

Left ovary
containing
10
corpora lutea



Structure of ovary: The ovary is composed of 4 layers

- a. Epithelium – surface layer
- b. Tunica albuginea – connective tissue covering the entire ovary
- c. Cortex – beneath tunica albuginea
 - i. contains follicles in various stages of development
- d. Medulla – loose connective tissue, blood vessels, lymphatics, and nerves

- The surface of the ovary is covered by a low cuboidal epithelium, the **germinal epithelium**.
- In spite of its name, this epithelium is not involved in the production of germ cells and thus the term **surface epithelium** appears to be more appropriate.

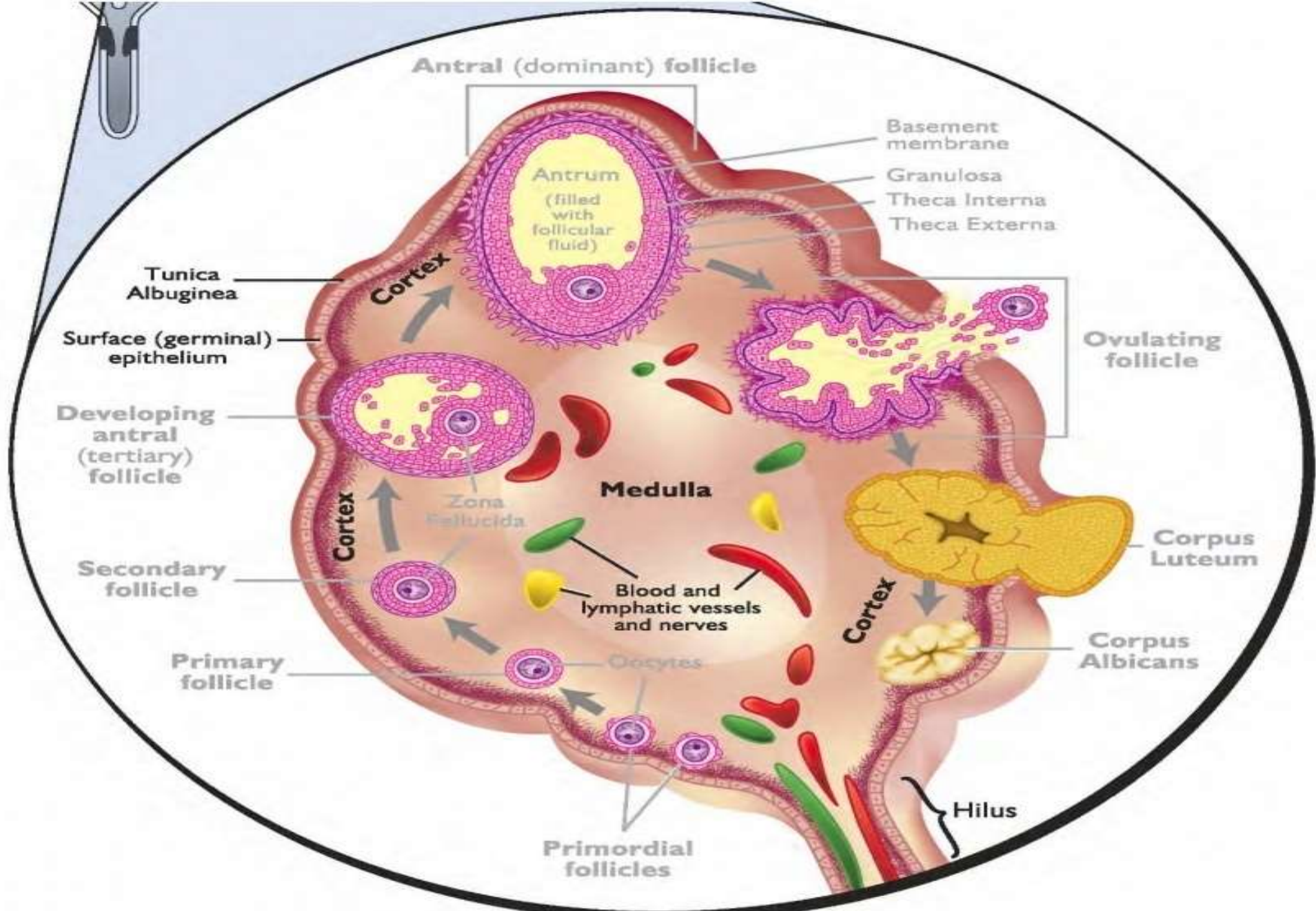
Immediately beneath the **surface epithelium** is a layer of connective tissue called the **tunica albuginea**.

Ovarian Structures

- **Cortex** --- In this zone are ovarian follicles in various stages of development and corpora lutea are located (parenchyma). These structures are embedded in a loose connective tissue the **stroma**.

The **canine ovary** has narrow channels lined by cuboidal epithelium that may be continuous with the surface epithelium. These structures are called **cortical tubules**.

Medulla --- This zone contains connective tissue and blood vessels. It is continuous with the mesovarium.



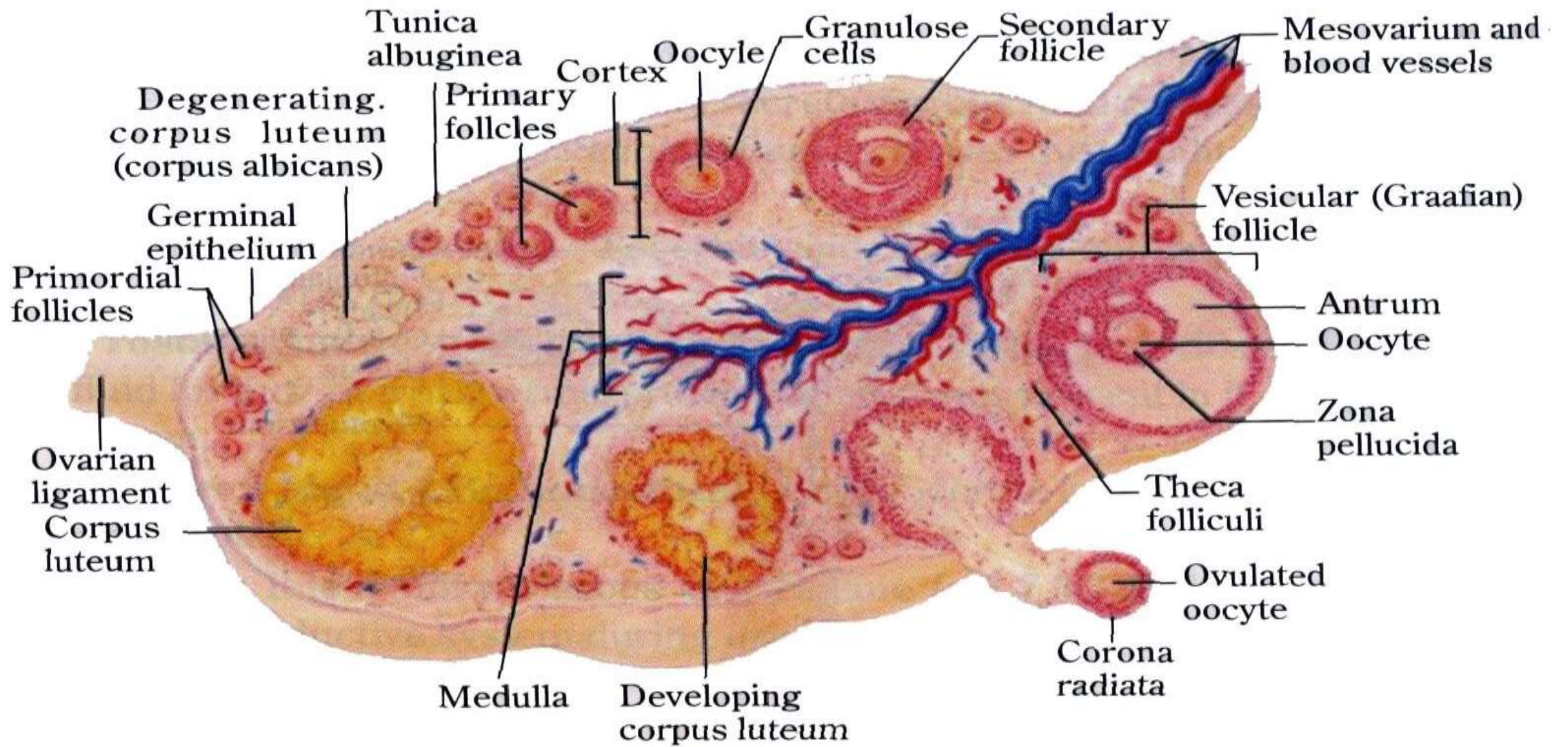


Fig. 15.4 T. S. of ovary

Mare ovary

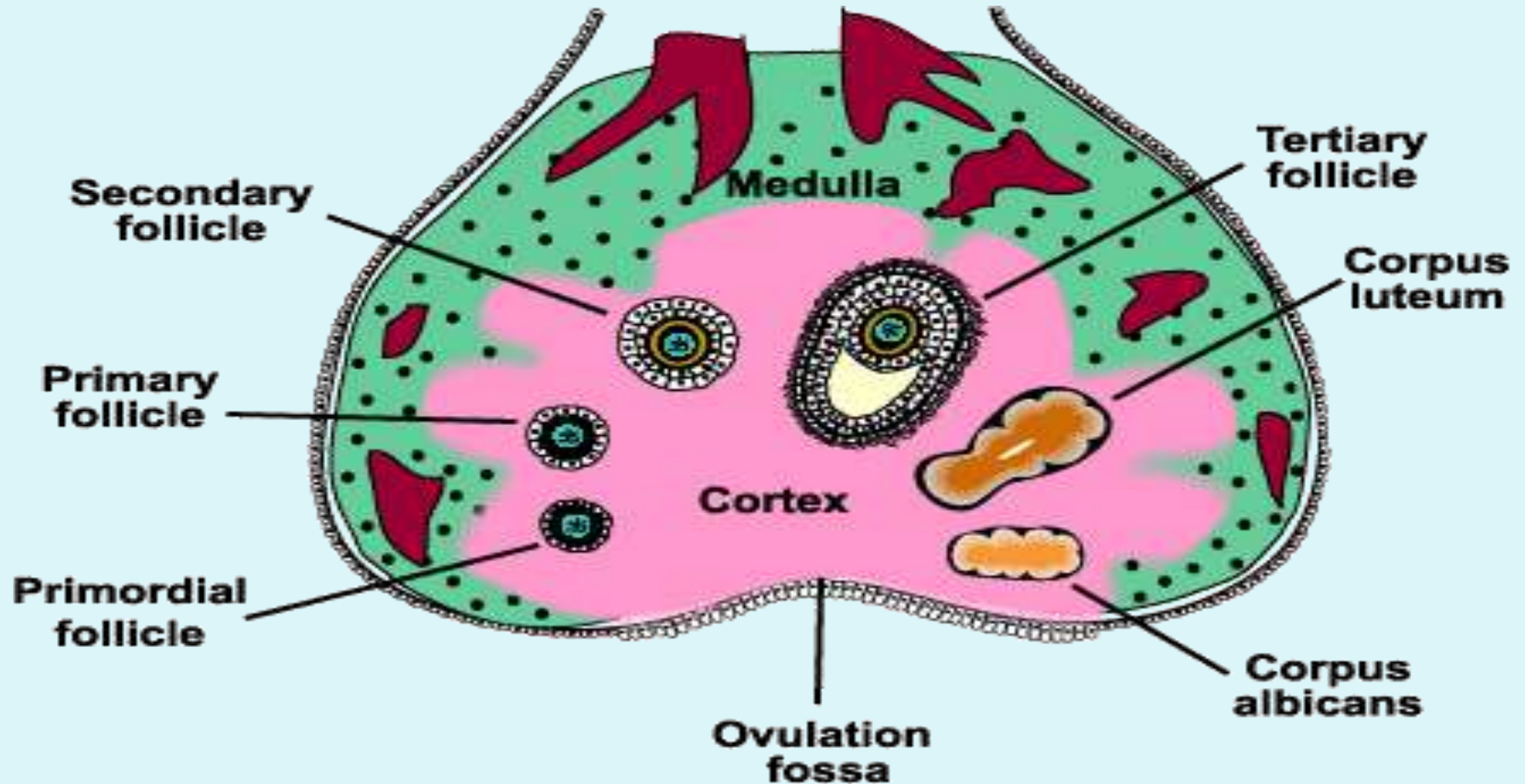
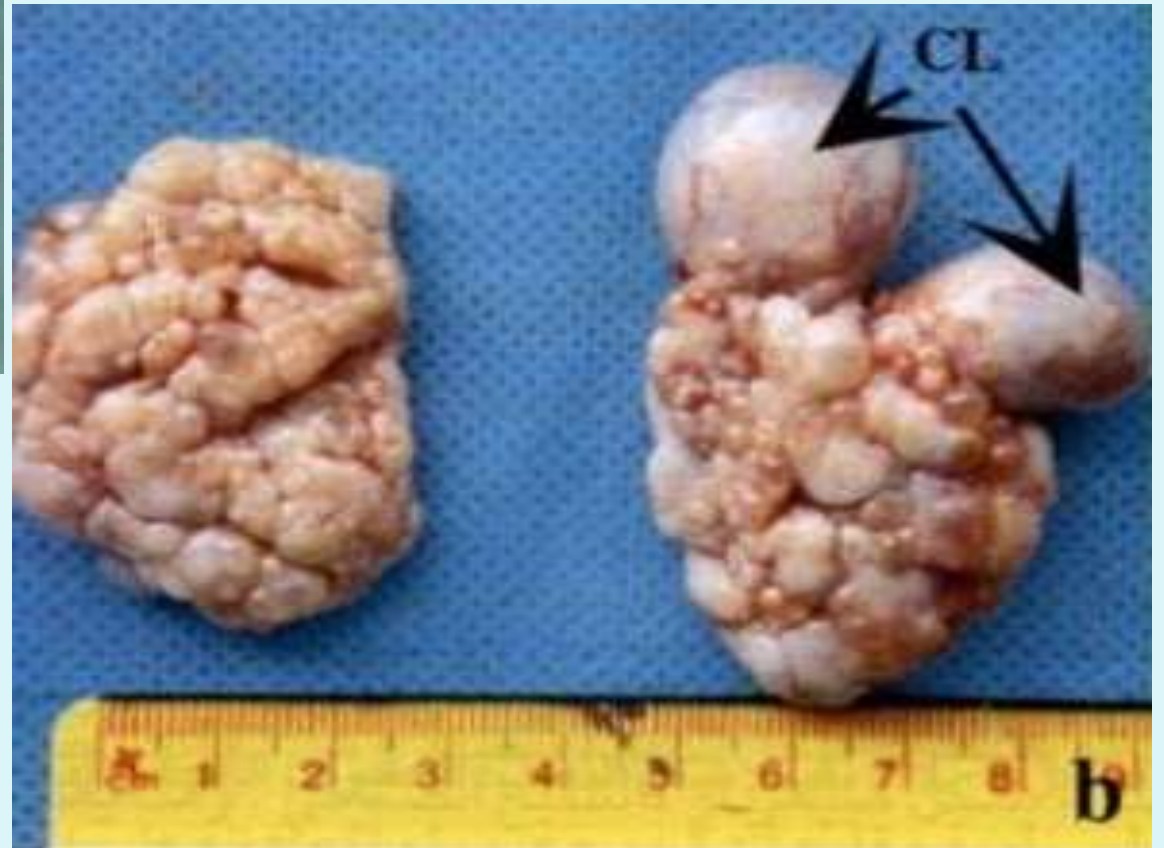
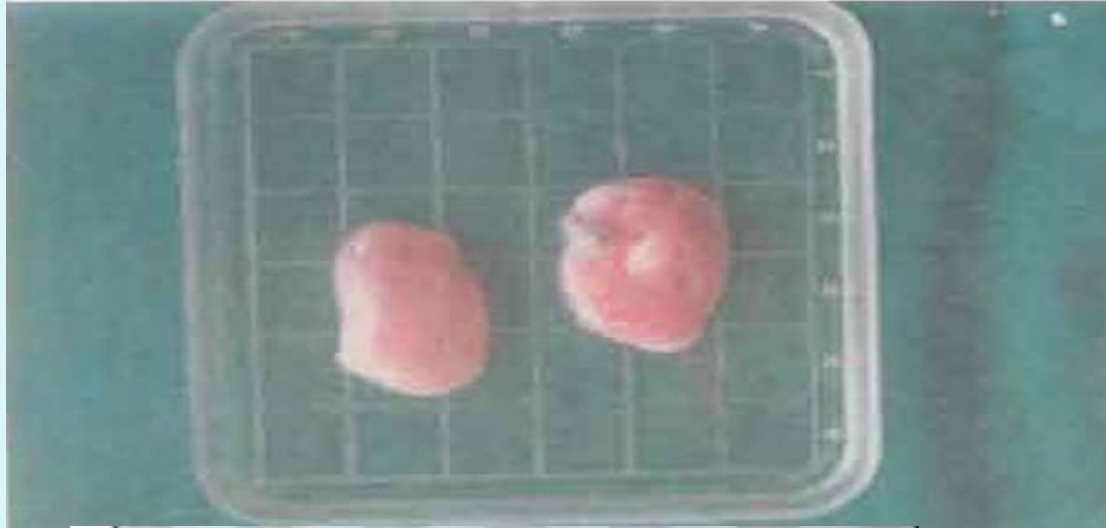
Table 1. Ovarian dimensions in domestic animals

	Cow	Mare	Ewe/ goat	Sow	Bitch	Buffalo	Camel
Length	1.3-1.5 cm	4-8 cm	1.25 cm		1.5-2.5 cm	2.27 cm	2.5-6 cm
Width	1.3-3.2 cm	3-6 cm	0.5-0.7 cm		0.7-1.25 cm	1.08 cm	2,2 cm
Thickness	0.6-1.9 cm	3-5 cm			0.5-0.75 cm	1.56 cm	1 cm
Weight	5-15 gm	40-80 gm	3-4 gm	3.5-10 gm	0.3 gm	3.83 g	2-5 -4.0 g
Follicle	1-2 cm	3.5-6.0 cm	0.5-0.7 cm	7-8 mm		7-14 mm	15-30mm
CL	1.0-3.2 cm	0.5-0.75 cm	0.5-1.5 cm	12-15 mm		1.40 cm	4-12 mm
Shape	Oval or almond	Bean	Almond	Mulberry	Oval	Oval	Oval, flattened

In the **camel** the ovaries are dorsoventrally flattened located on the pelvic floor and contain hemorrhagic follicles.



Vasculature of the ovary.

The ovarian artery (a branch of the Aorta) and ovarian branches of the **uterine artery** form anastomoses in the mesovarium and the broad ligament.

From this arterial plexus ~10 coiled Helicine arteries enter the hilus of the ovary.

Smaller branches form a plexus at the cortico-medullary junction, giving rise to straight Cortical arterioles, which radiate into the cortex.

Here they branch and anastomose to form vascular arcades, which give rise to a rich capillary network around follicles.

Venous Drainage

Venous drainage follows the course of the arterial system.

Medullary veins are large and tortuous.

The Ovarian Artery is closely associated with the Uterine Vein.

This is important for the transfer of luteolytic $\text{PGF}_{2\alpha}$ from the Uterus to the Ovary.

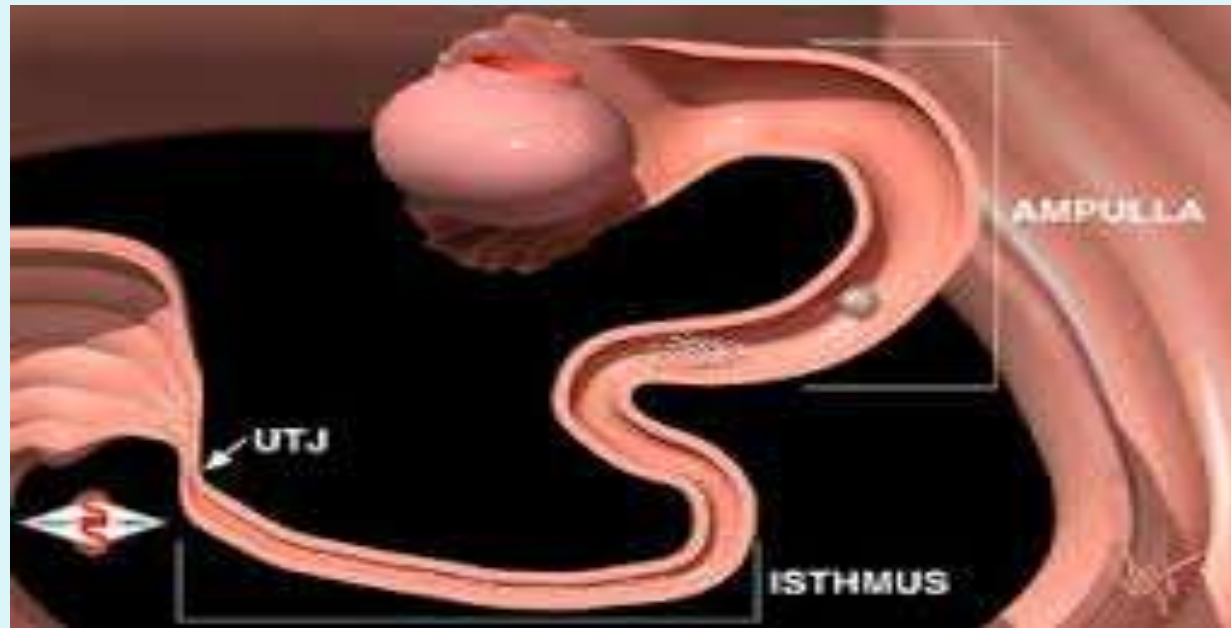
Innervation.

Sympathetic fibres of the autonomic nervous system supply blood vessels and terminate on smooth muscle cells in the stroma around follicles.

May play a role in follicular maturation and ovulation, but the main control is via the endocrine system.

The oviduct (Fallopian tube)

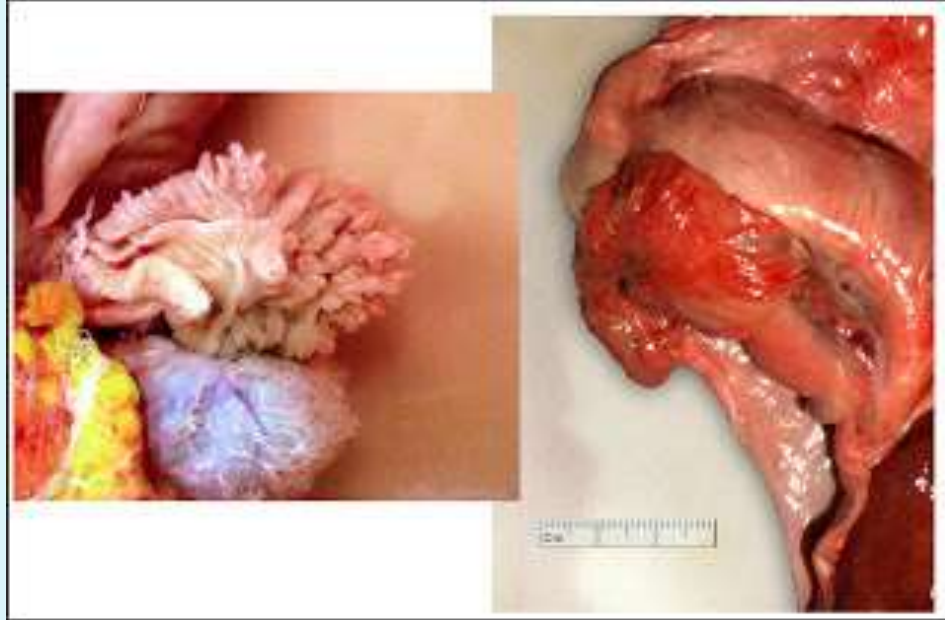
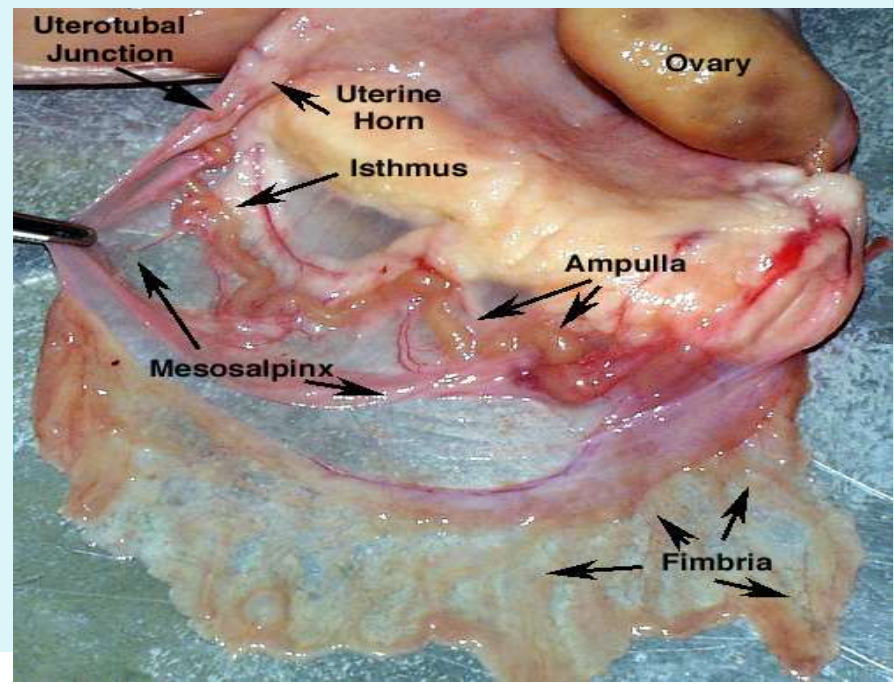
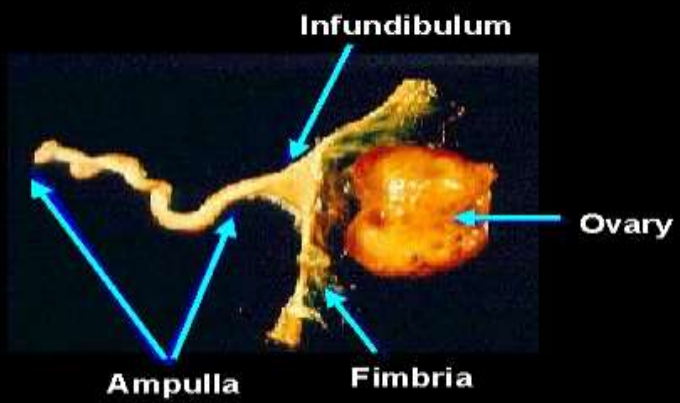
- The oviduct can be divided into four functional segments: the finger like fimbriae; the funnel shaped abdominal opening near the ovary-the infundibulum; the more distal dilated ampulla; and the narrow proximal portion of the oviduct connecting the oviduct with the uterine horn- the isthmus.



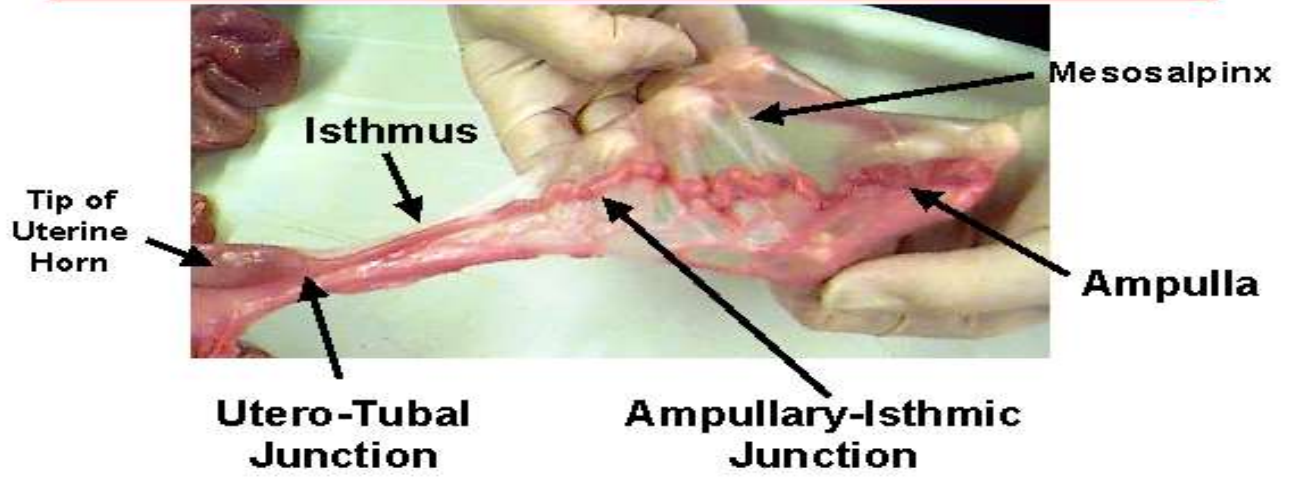
Oviductal Dimensions

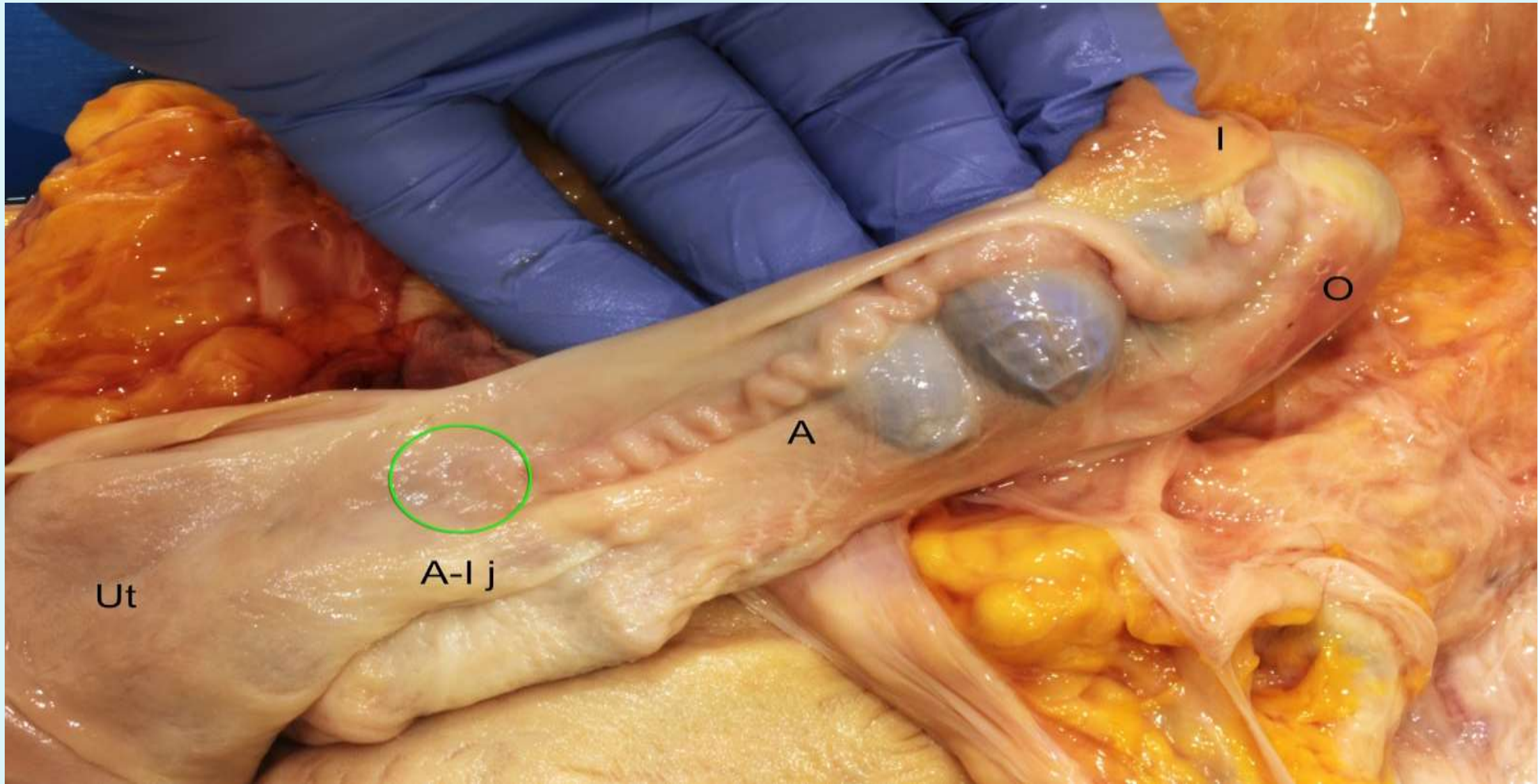
- The oviduct is 20-30 cm long and has a diameter of 1-3 mm in the **mare and cow**.
- The oviduct of the **sow** is 15-30 cm long and that of the bitch and cat is 4-7 cm.
- The uterine end of the oviduct in the **dog and mare** opens into the uterine lumen through a small slit on a mound or **papilla**

Bovine Oviduct

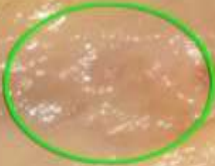

Utero-Tubal Junction





Ut



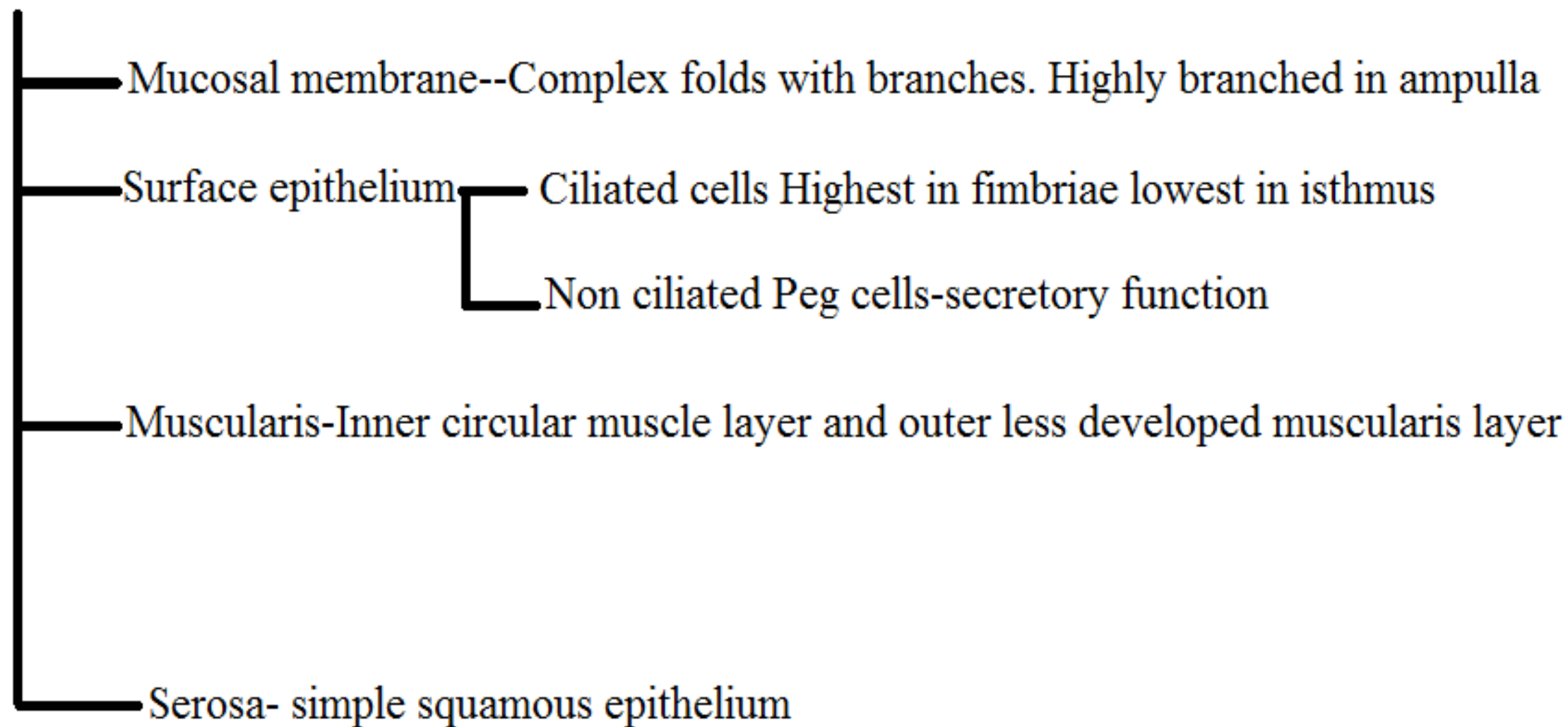
A-I j

A

I

O

Histological structures of oviduct



- The oviductal mucosa is made up of primary, secondary and tertiary folds. The mucosa consists of one layer of columnar epithelial cells which are either ciliated or non-ciliated. The ciliated cells of the oviduct mucosa have slender motile cilia (kinocilia) that extend into the lumen.
- Has both circular and longitudinal muscles which also aid in transport of oocytes and spermatozoa

Functions of the oviduct

Receiving the ovum → Fimbriae

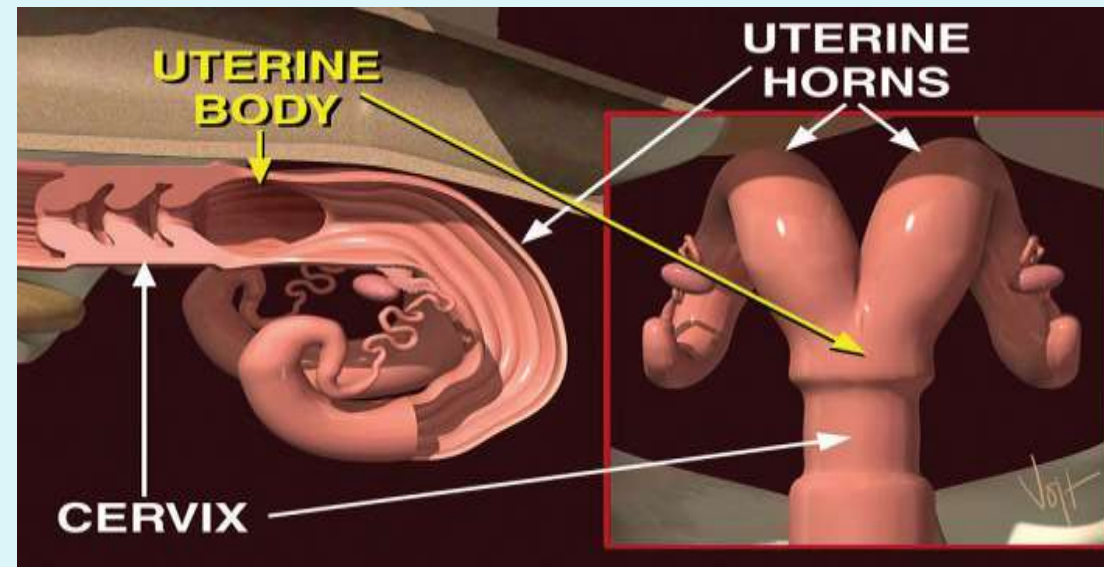
Transport of ovum towards uterus → cilia plus contractions

Capacitation of sperms

Fertilization → ampulla of oviduct

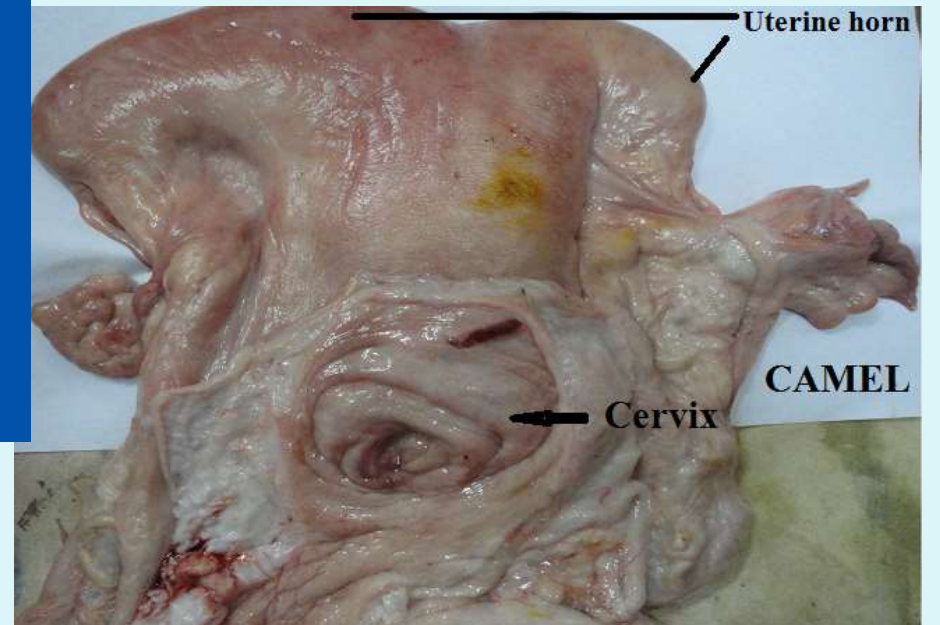
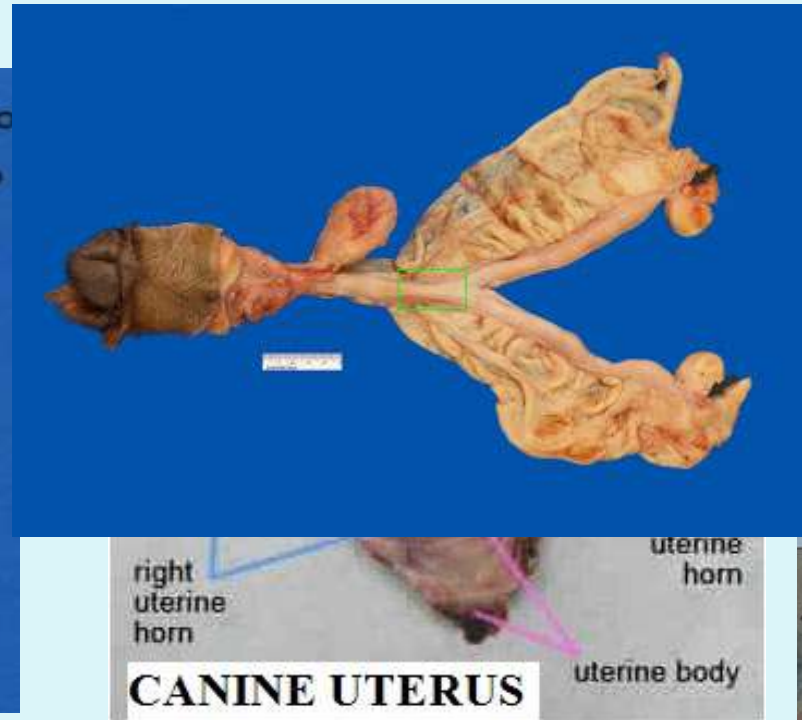
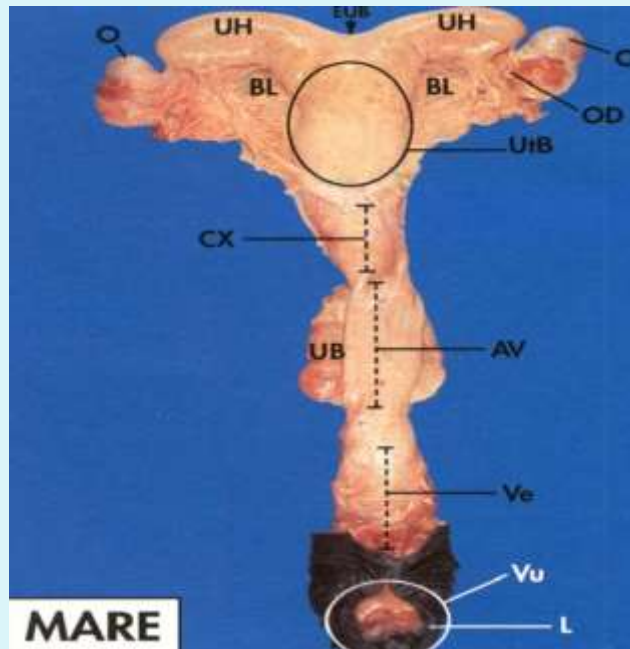
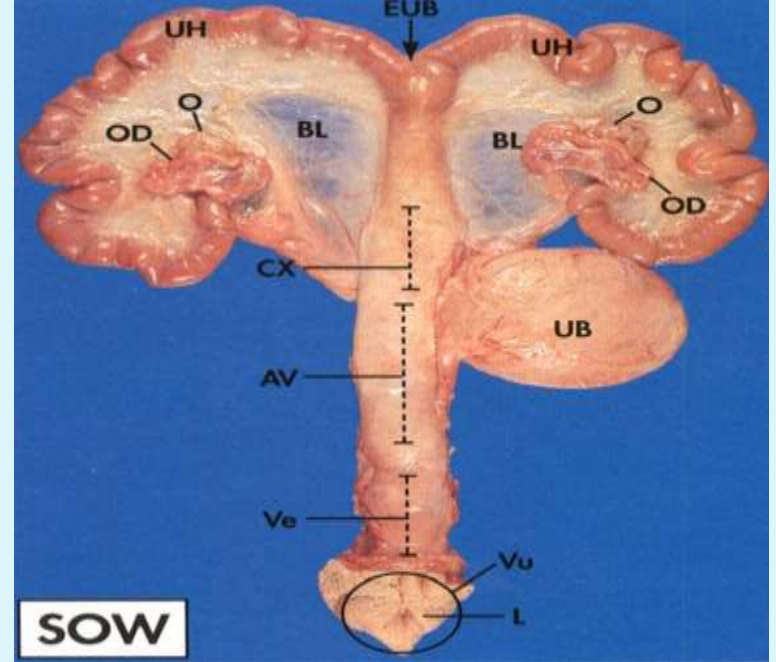
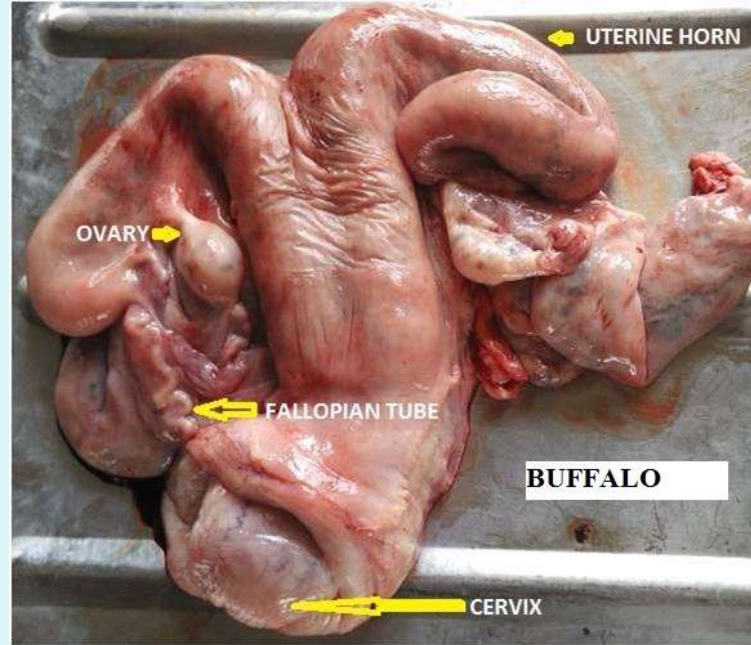
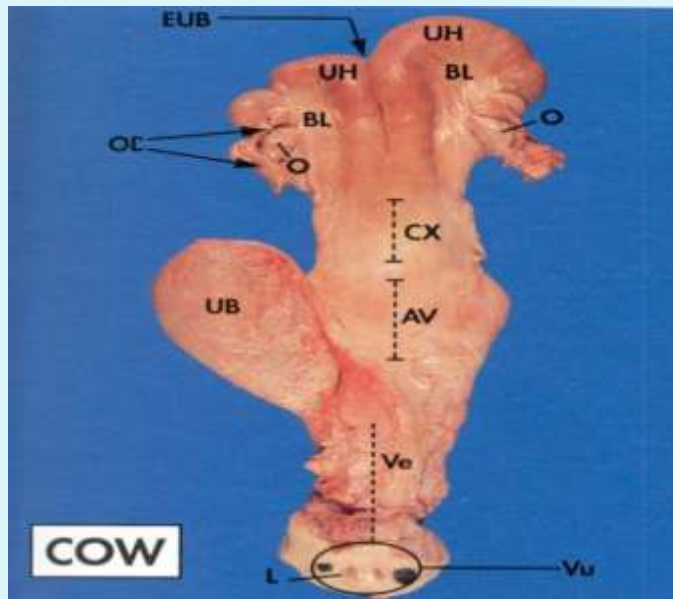
The Uterus

- The uterus is the tubular hollow structure where fetus grows and pregnancy continues. In other words The uterus is the organ of pregnancy as this is where implantation and development of the fetus occurs.
- It consists of a corpus (body), cervix (neck) and two cornua (horns).
- The shape of the uterus varies between species



Uterine Horn Appearance

Species	Mare	Cow	Ewe	Sow	Bitch	Camel
Uterine Horn Appearance	Straight and divergent 'T' shaped. Uterine body equal to uterine horn	Round parallel to each other	Round	Intestinal loop appearance	Straight and divergent	Straight and divergent 'T' or 'Y' shaped
Length of uterine horns	15-20 cm long 4-7.5 cm wide	20-40 cm long 1.25-5 cm diameter	10-12 cm long	Uterine body 5 cm long. In pregnant animals uterine horns 4-6 feet long	12-15 cm long 0.5-1.0 cm diameter	



Anatomical types of uterus

- **Duplex Uteri (Uterus duplex)**

Completely separate uterine horns each with their own cervical canal. Duplex uteri are seen in rabbits and marsupials.

Along with having 2 uterine horns and cervical canals marsupials also have two vaginas.

- **Simplex Uteri (Uterus simplex)**

Complete fusion of the paramesonephric ducts forming a single uterine body with no uterine horns. This is seen in primates and especially humans

Bicornuate Uteri

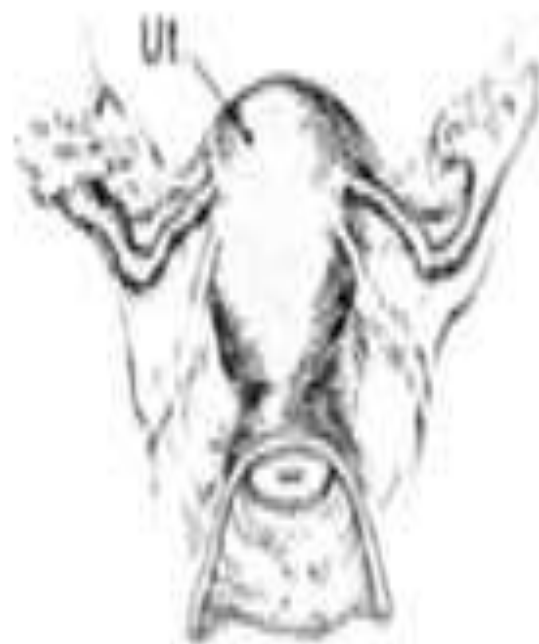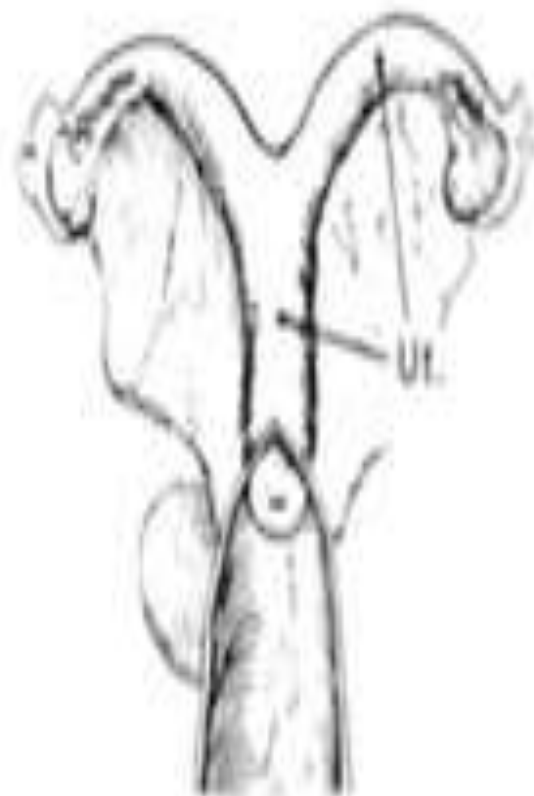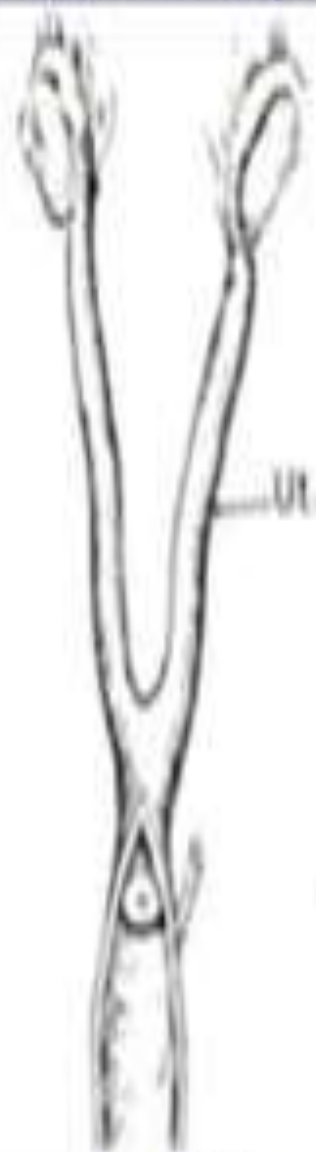
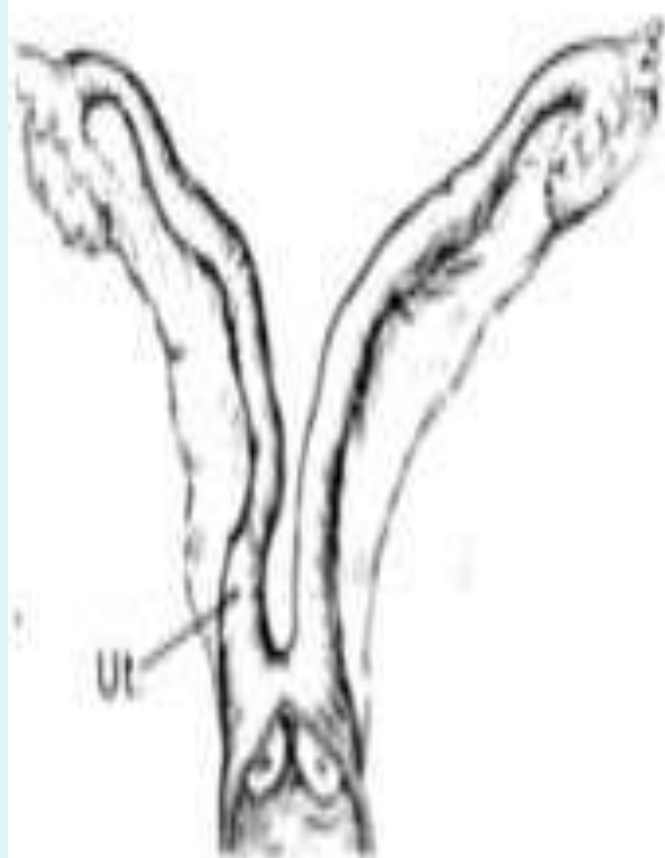
- (Previously Bipartite Uteri) Bicornuate uteri have a relatively small uterine body and two uterine horns of varying development.
- A relatively large uterine body and short, poorly developed uterine horns, as seen in the mare, are due to a high degree of paramesonephric duct fusion.
- Moderately developed uterine horns as in the cow, ewe and goat arise due to an intermediate degree of fusion.
- Long uterine horns and a small uterine body as seen in the sow, bitch and queen arise due to a low degree of fusion of the paramesonephric ducts.
- This varying degree of paramesonephric duct fusion reflects the species differences in litter sizes, monotocous species having short horns and polytocous animals having much longer uterine horns.

Double

Bicornuate (long)

Bicornuate (short)

Simplex



(Rodents, Lagomorphs)

(Carnivores, Suids)

(Ruminants, Equids)

(Primates)

Tissue layers of uterus

- 1) Tunica serosa (**perimetrium**)
 - a. Outermost layer
 - b. Connective tissue
- 2) Tunica muscularis (**myometrium**) Both circular (inner) (1 layer) and longitudinal (outer) (2 layers) muscles are present in the uterus. The two uterine horns are joined by the intercornual ligaments. There are **no intercornual ligaments** in the **bitch and sow**. The uterine **horns** in the **mare** lie **ventral** to the **intercornual ligaments**.

- 3) Tunica mucosa (**endometrium**) Provides point of placental attachment and glands provide secretions for embryo development and is highly secretory.
 - a. Consists of mucosa and submucosa and the endometrial glands. The endometrium is highly glandular over the entire lining except in ruminants
 - b. Ruminants have mushroom-shaped projections called caruncles where fetal membranes attach, the fetal sides are called cotyledons. The caruncles are convex in cow and concave in sheep
 - c. In the Sow and Mare - uterine folds are present.

Submucosa
Lumen
Mucosa

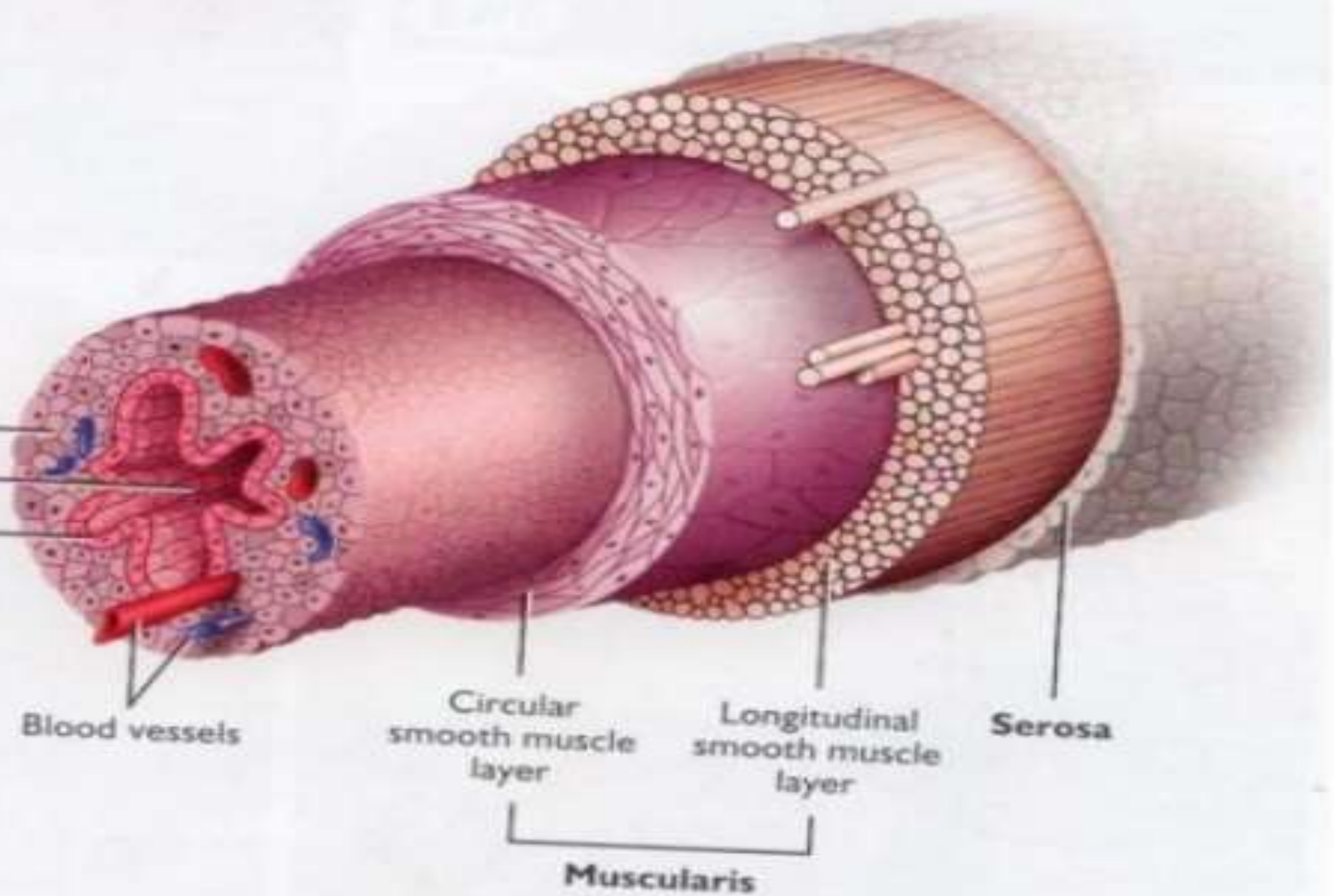
Blood vessels

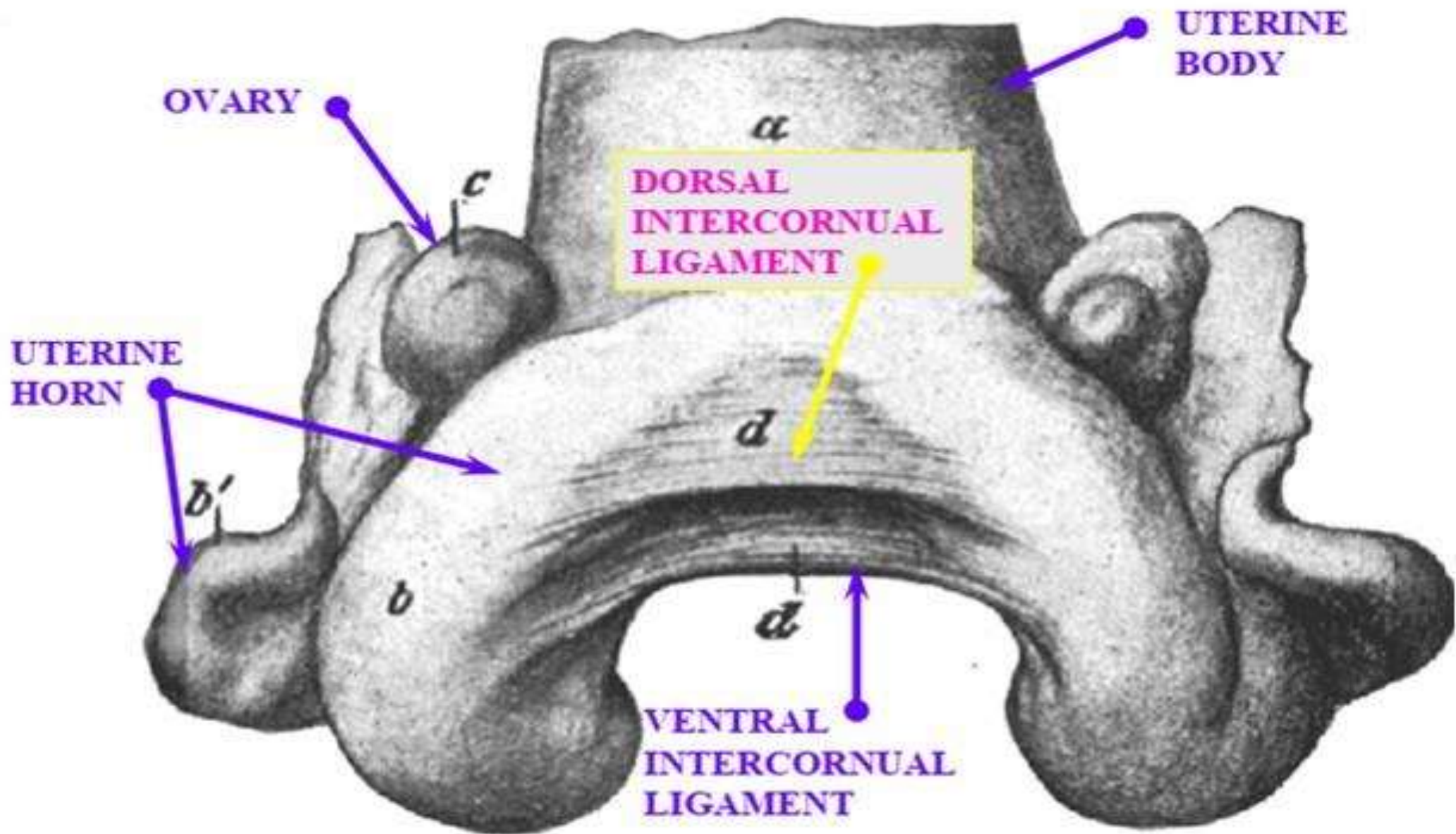
Circular
smooth muscle
layer

Longitudinal
smooth muscle
layer

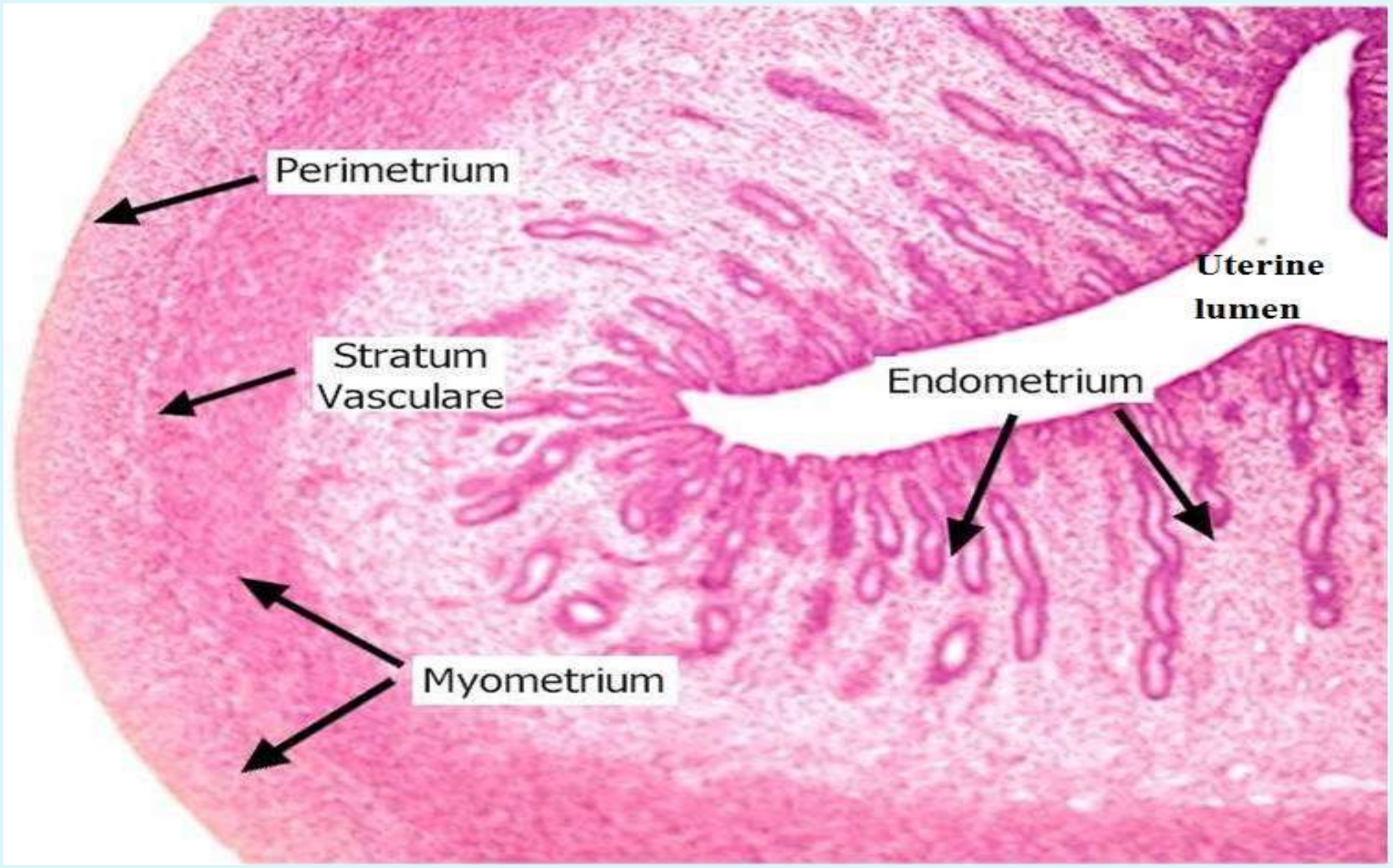
Serosa

Muscularis





DORSAL VIEW OF REPRODUCTIVE TRACT OF THE COW



Perimetrium

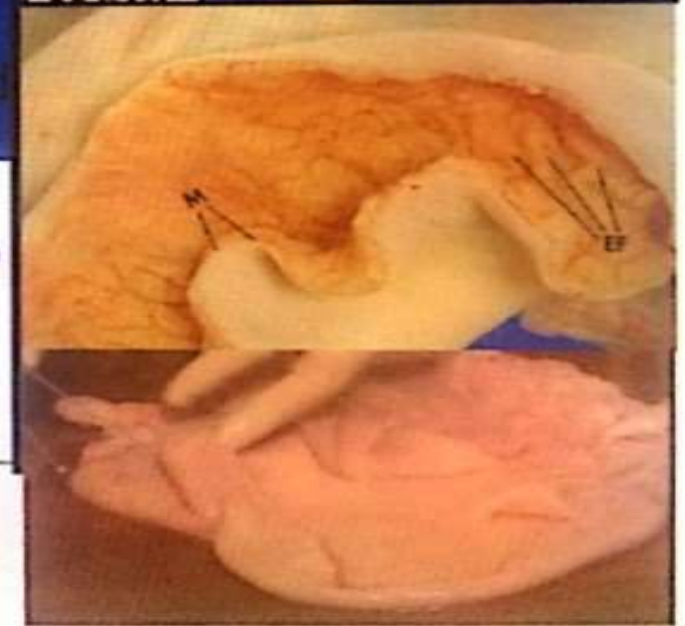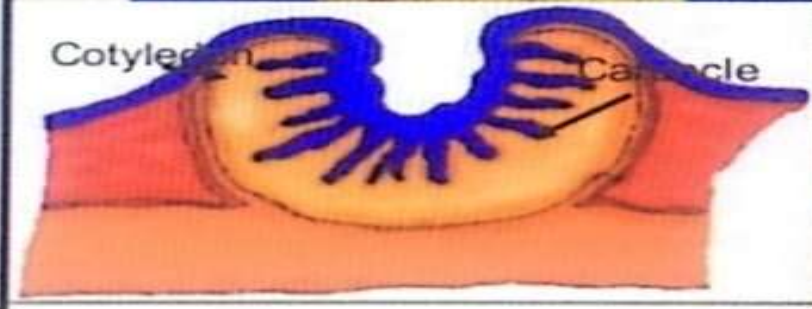
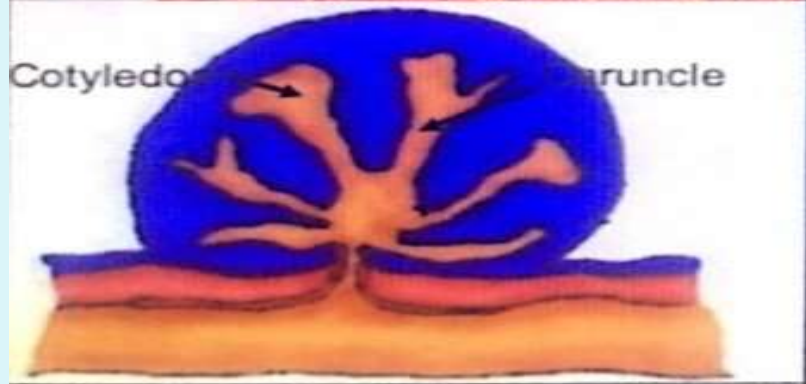
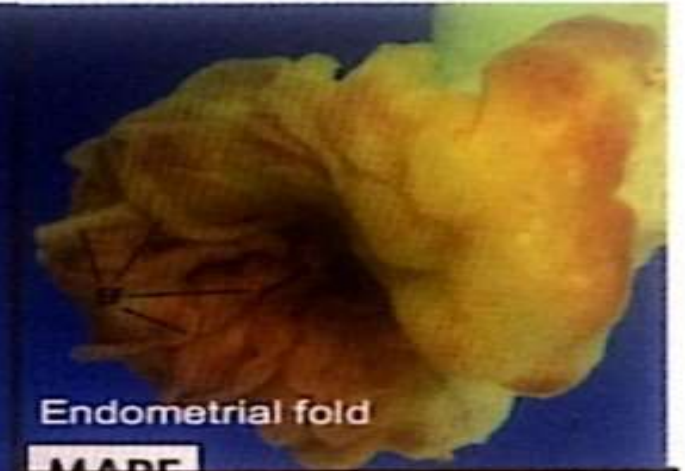
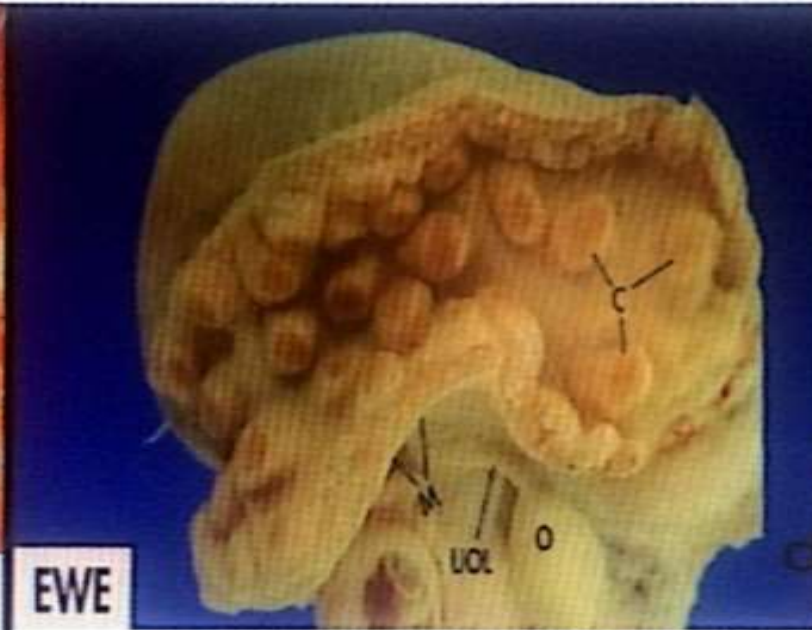
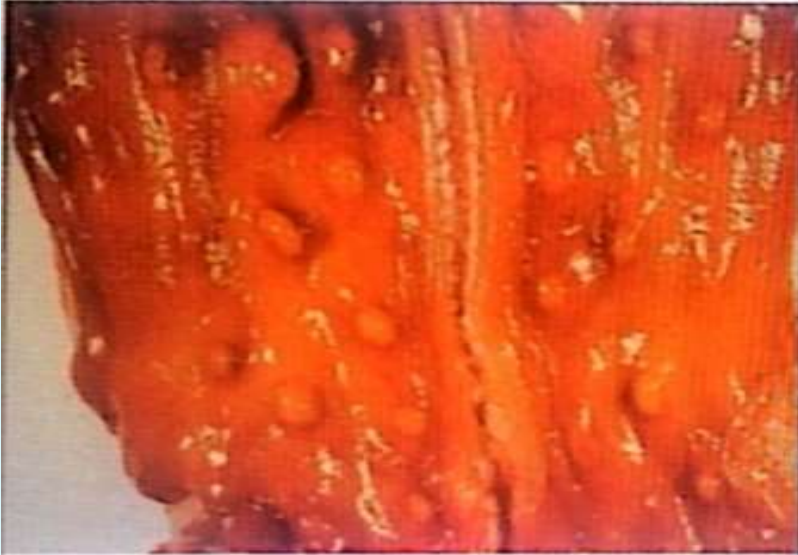
Uterine lumen

Stratum Vasculare

Endometrium

Myometrium

Uterine endometrium

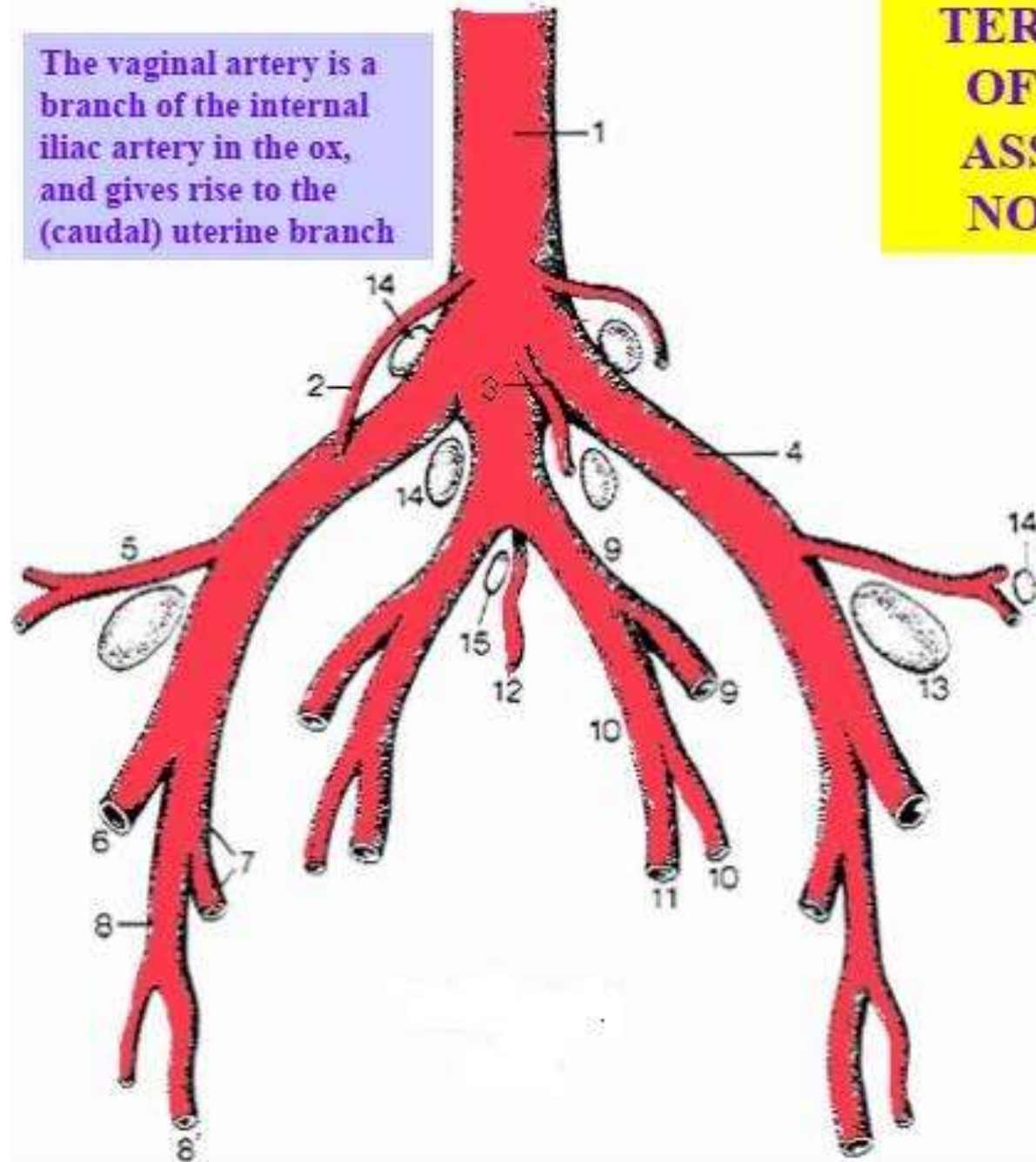


Vasculature

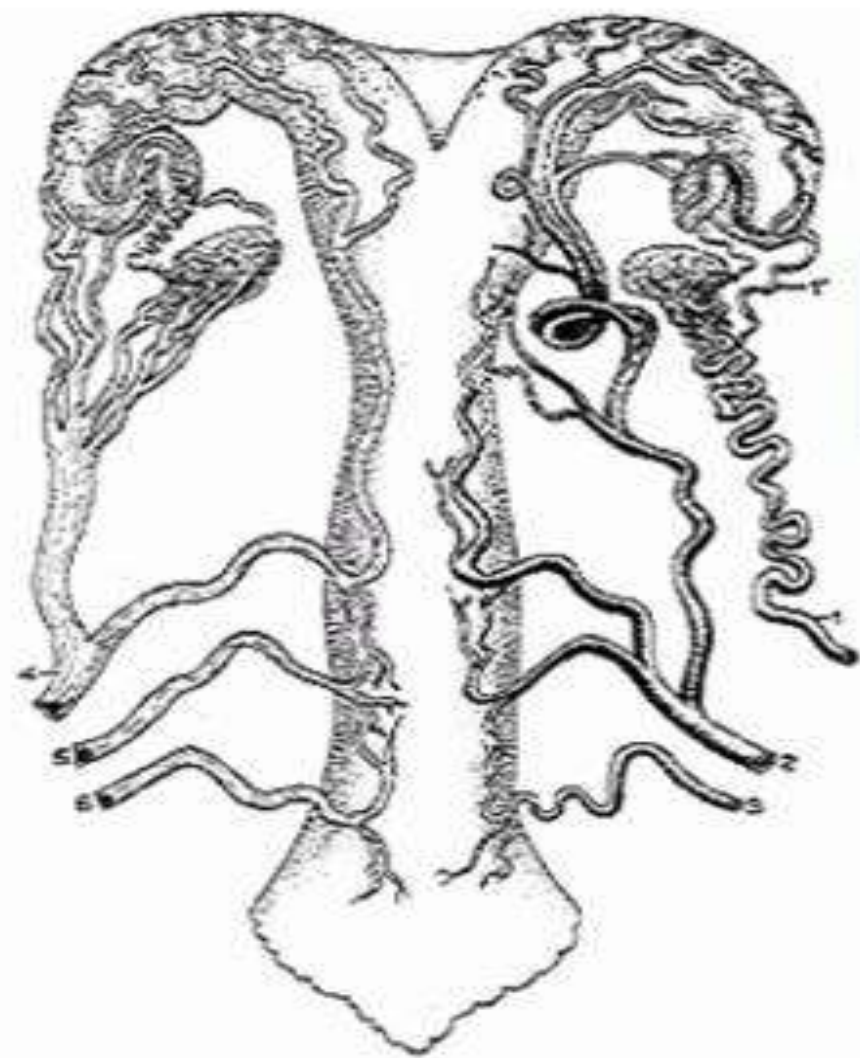
- Uterine branch of the Ovarian artery supplies the cranial parts of the Uterine horns.
- Uterine artery supplies the rest of the uterine horns and the uterine body. This is a branch off the Internal Iliac artery in most domestic species, except the Mare where instead it is a branch off the External Iliac artery. The Uterine artery and the Ovarian artery anastomose within the Broad ligament.

The vaginal artery is a branch of the internal iliac artery in the ox, and gives rise to the (caudal) uterine branch

TERMINAL BRANCHES OF THE AORTA, AND ASSOCIATED LYMPH NODES OF THE COW



1. Aorta
2. Ovarian Artery
3. Caudal Mesenteric A.
4. External Iliac A.
5. Deep Circumflex Iliac A.
6. Femoral A.
7. Deep Femoral Artery
8. Pudendoepigastric Trunk
- 8'. External Pudendal A.
9. Internal Iliac A.
10. Umbilical A.
11. Uterine (Middle Uterine) A.
12. Median Sacral A.
13. ND & NAV calls it Deep Inguinal, S1034 & 1038 calls it Medial Iliac
14. Medial Iliac LN's
- 14'. Lateral Iliac L.N.
15. Sacral L.N.

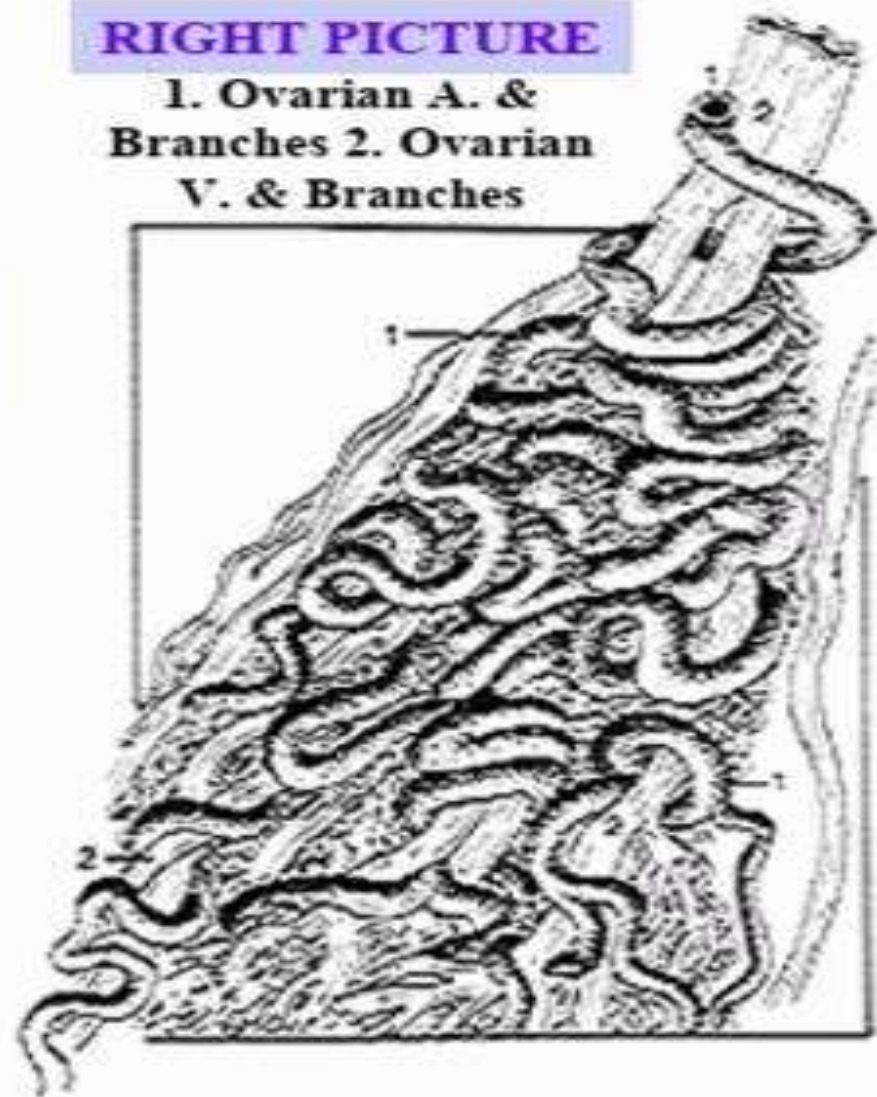


LEFT PICTURE
(Arteries on Right,
Veins on Left

1. Ovarian A.
- 1'. Uterine Branch
2. Uterine (Middle) A.
3. Vaginal A.
4. Ovarian V.
5. Accessory Vaginal V.
6. Vaginal V.

RIGHT PICTURE

1. Ovarian A. &
Branches
2. Ovarian
V. & Branches



**BLOOD SUPPLY TO
THE REPRODUCTIVE
TRACT OF THE COW**

Innervation

- The uterus is innervated by both Sympathetic and Parasympathetic fibres which play a part in the regulation of uterine activity. This is highlighted by iatrogenic manipulation of parturition using β -Adrenoreceptor agonists for delaying parturition and antagonists for inducing parturition. However, uterine activity and normal parturition can be achieved when these nerves are severed.

Cervix

Cervix is a sphincter that connects the uterus and vagina. The cervix opens anteriorly into the uterine body. About an inch long, the body of the uterus serves as a connection between the two uterine horns and the cervix.

The cervix is a fibrous organ composed predominantly of connective tissue with only small amount of smooth muscle tissue.

The lumen of the cervix is the cervical canal.

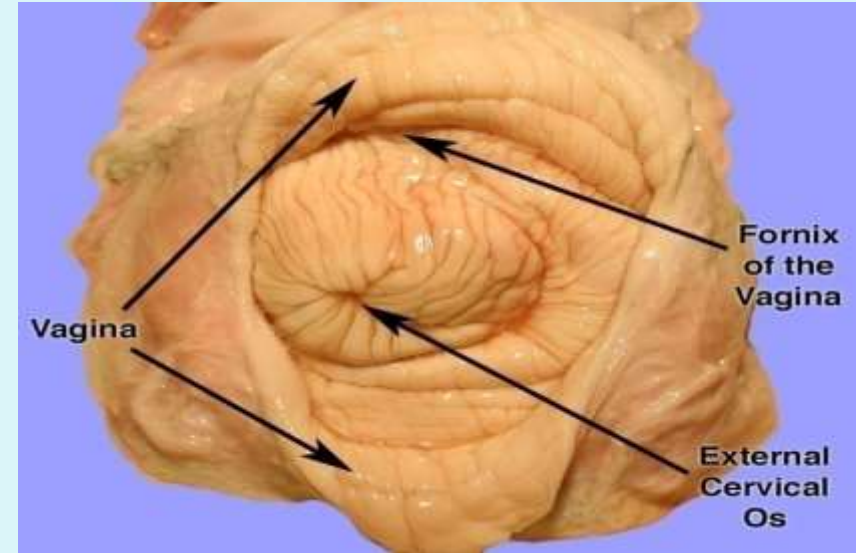
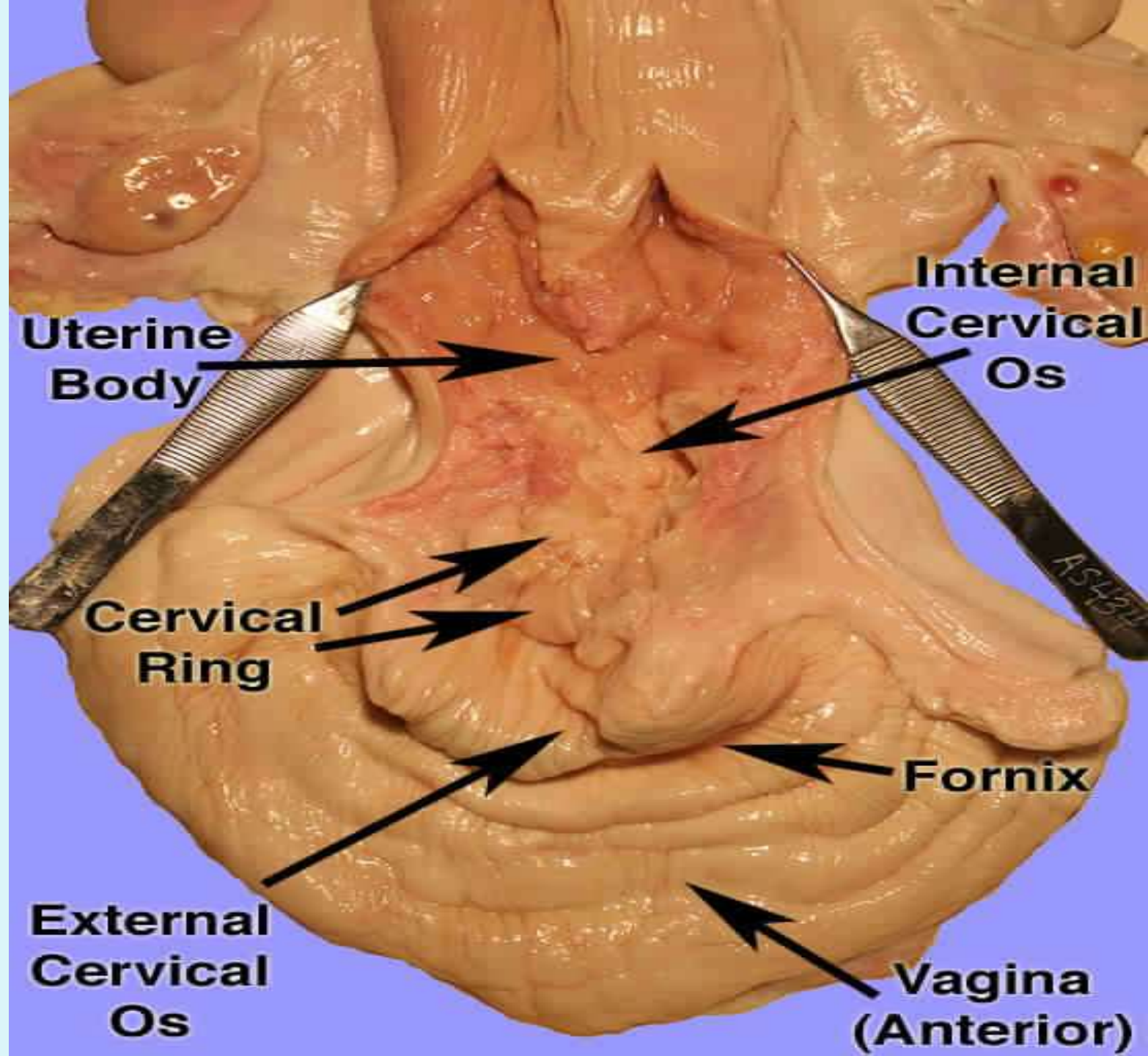
The canal is formed by, and often almost occluded by mucosal folds.

The cervix has mucus secreting cells.

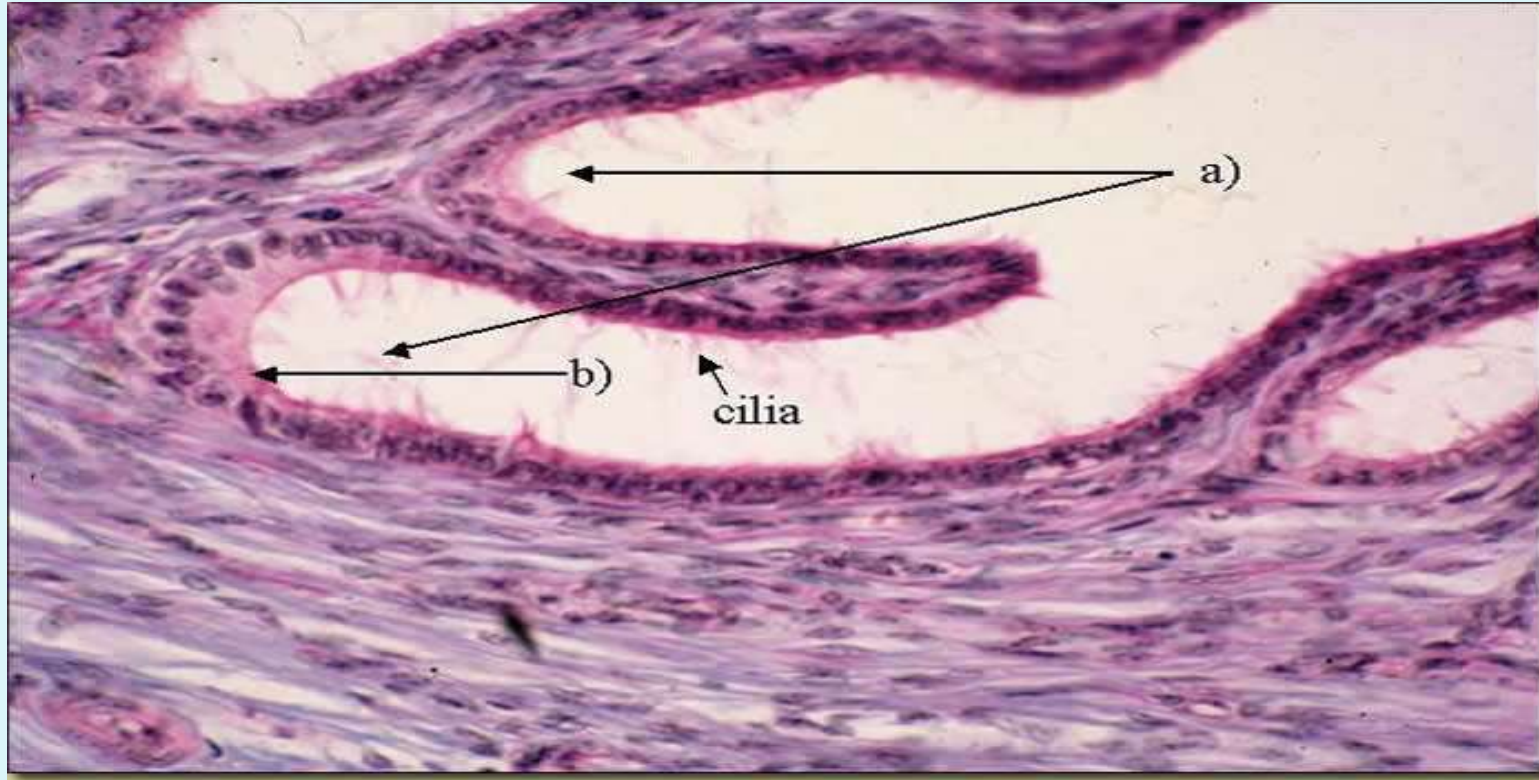
- The cervical canal has many prominences (mucosal folds). In ruminants these are present in the form of transverse or spirally interlocking ridges known as **annular rings**.
- They are prominent in the **cow** (usually 3-4 rings), buffalo (1-3 rings), goat (4-5 rings) and in the **ewe** (6-7 rings), in which they fit into each other to close the cervix securely.
- The cervix in buffaloes is comparatively shorter and narrower
- The annular ring arrangement in the ewe provides a curved canal.
- In the sow, the rings are interdigitating in a corkscrew arrangement that adapts to the spiral twisting of the tip of the boar's penis.
- The cervix of a mare is soft and does not have fibrous tissue or annular rings.

- The mucosal folds are single fold and have a smooth surface in the **queen and bitch**.
- The cervical canal opens cranially into the body of the uterus at the internal uterine ostium.
- The cervical canal opens caudally into the vagina at the external uterine ostium.
- The opening into the cervix protrudes back into the vagina. This forms a 360⁰ blind-ended pocket completely around the cervical opening. This pocket is referred to as the fornix.
- The fornix is absent in the **sow**.
- The opening of the cervix towards vagina is called os externus

- The cervix of sow and bitch are poorly defined.
- The connective tissue of the cervical stroma is made up of ground substance, fibrous constituents, and cellular contents. The ground substance contains **proteoglycan** and **hyaluronic acid dermatan sulfate** and proteins.
- The fibrous constituents include **collagen, elastin and reticulin**
- Cellular elements comprise mast cells, fibroblasts and wandering cells.
- The patterns of reticulin, elastin, and interfibrous ground substances facilitate the dilation of cervix at parturition. This is especially possible by the dissociation of collagen fibers which become widely separated from one another resulting in loosening of cervical tissues and increases clear spaces between collagen bundles.

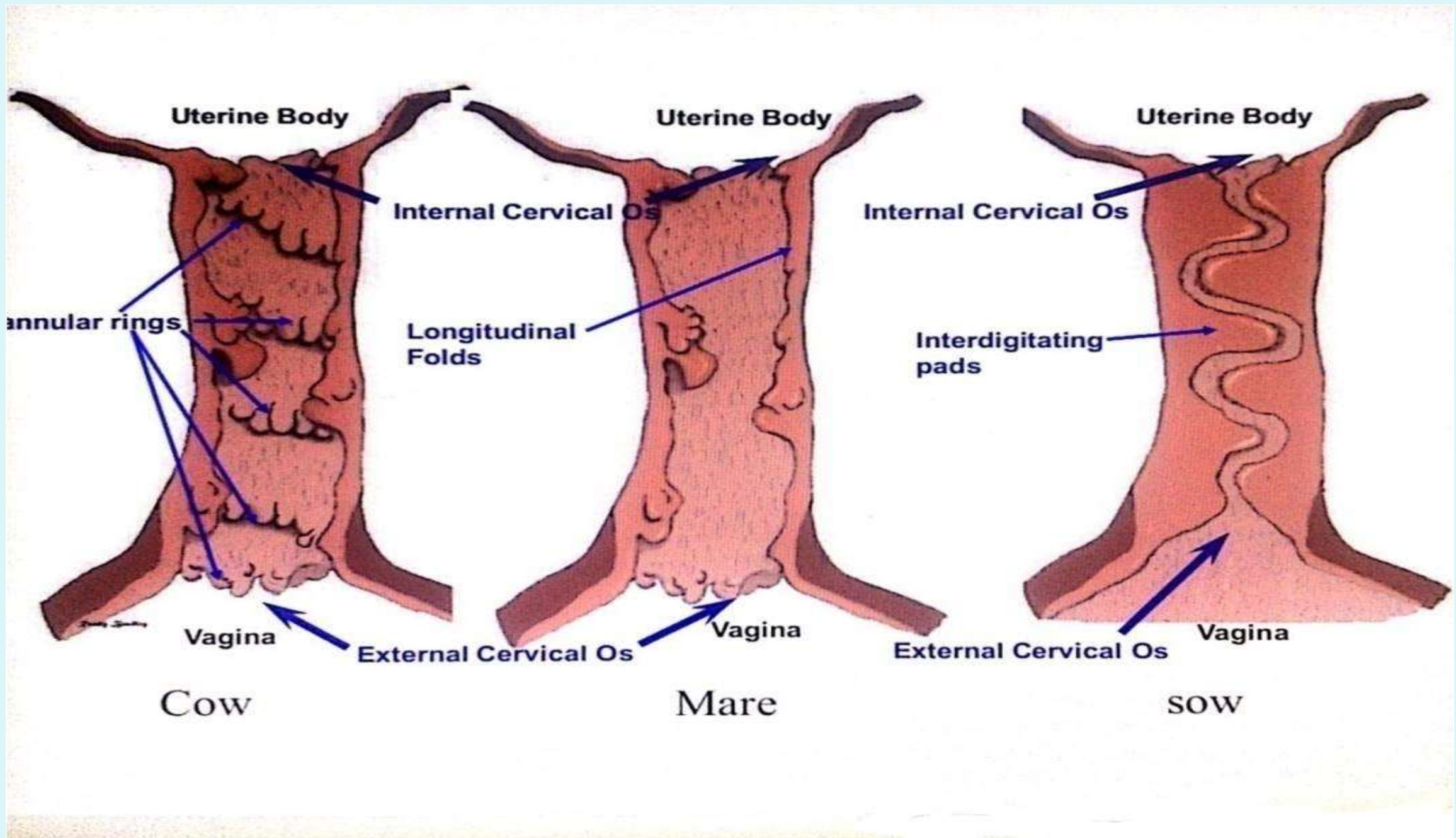


Bovine cervix Histology

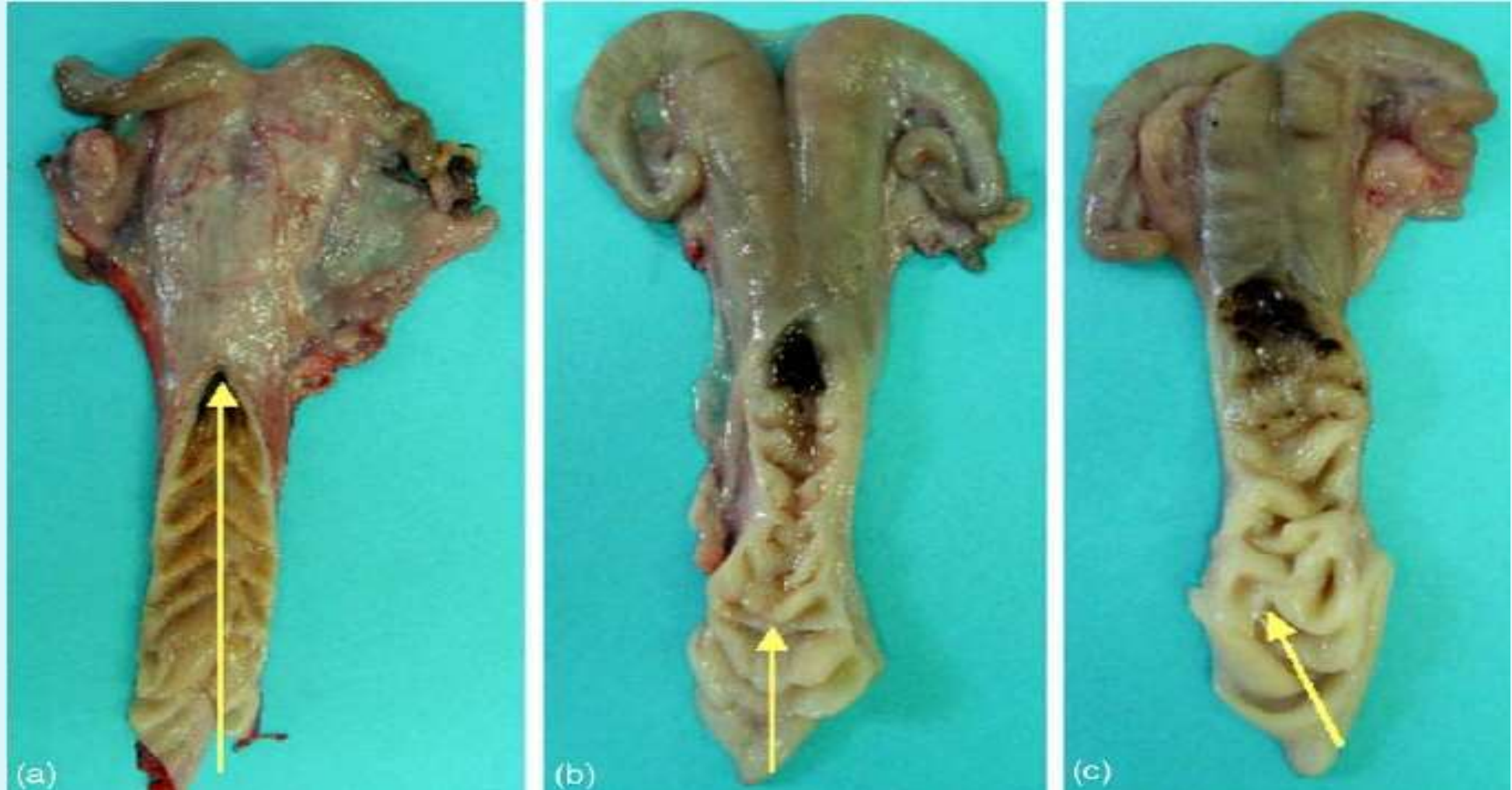

a) Cervical crypts

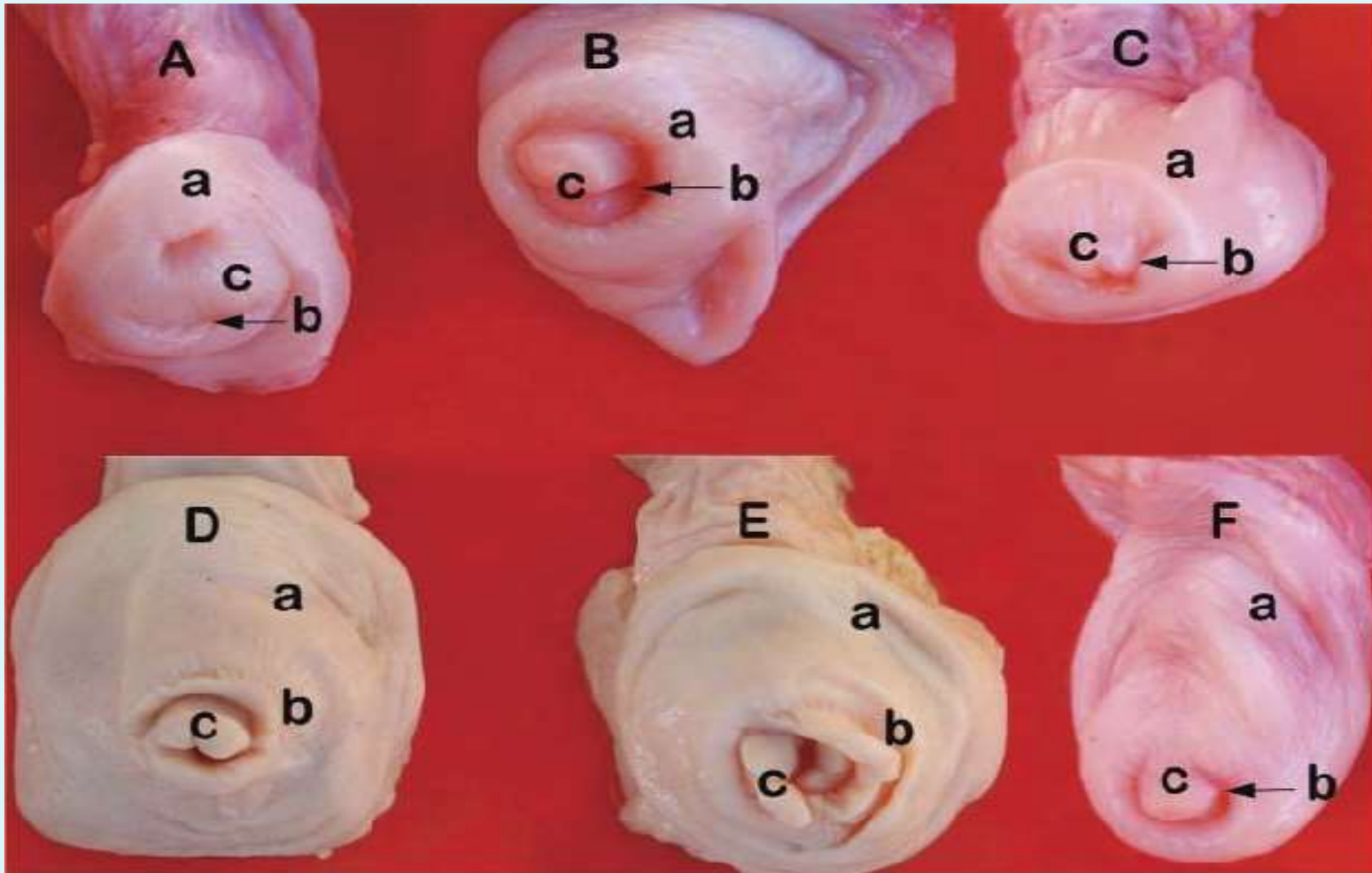
b) Simple columnar epithelium (some ciliated)



The annular rings in sheep cervix

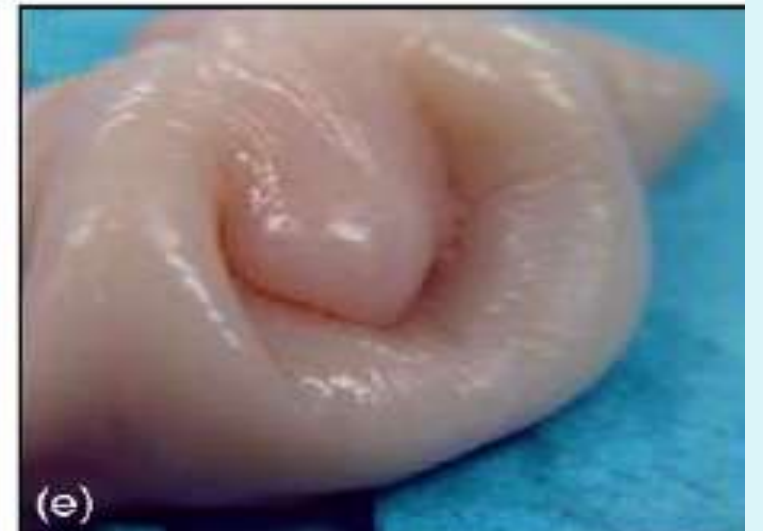
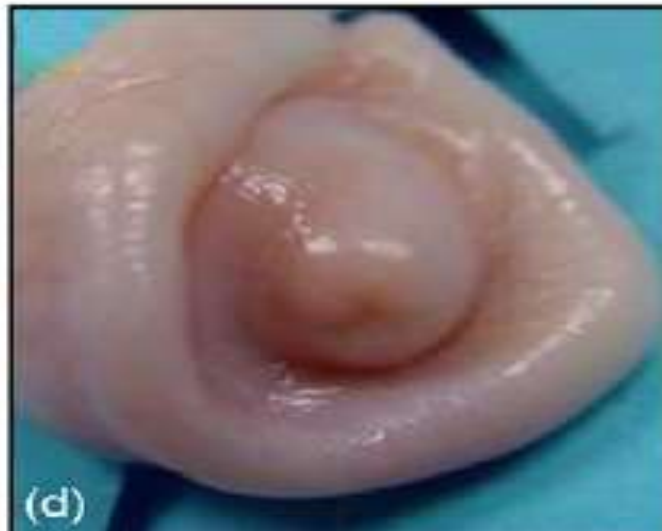
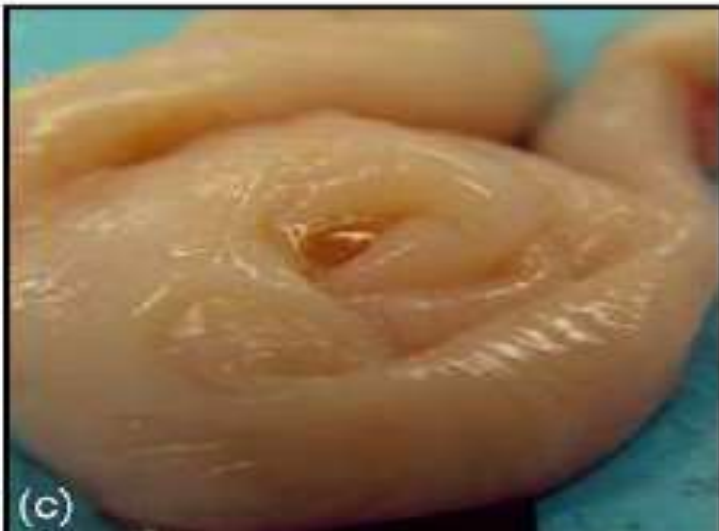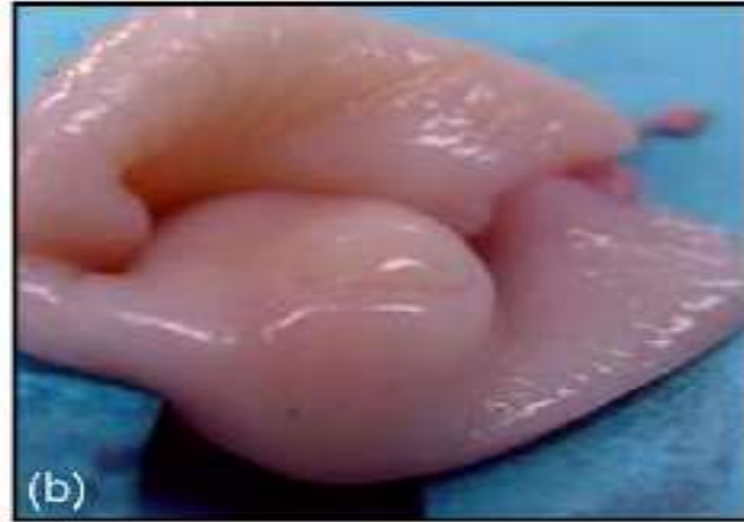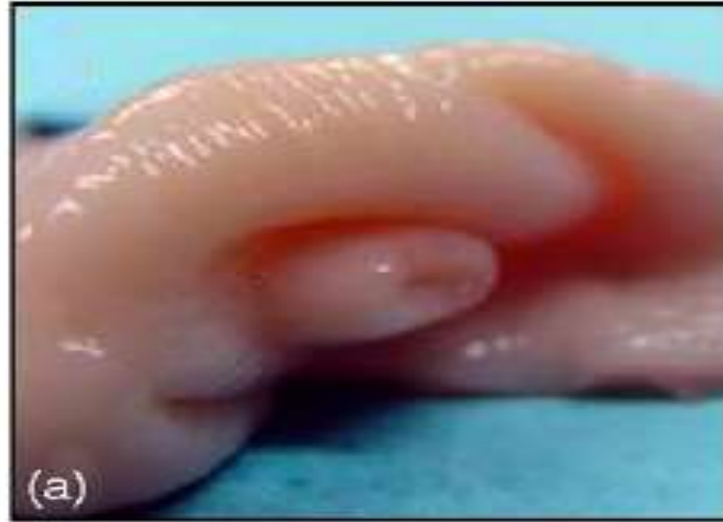- Vaginal protrusions of the cervix in sheep and goat form different shapes



Appearances of the vaginal protrusions in the Angora goat
A. Star, B. Duckbill, C. Crescent, D. Spiral, E. Cluster, F. Bump

External os of sheep cervix



Canine cervix

- The canine cervix (cervix uteri) is composed of smooth muscle that contains the cervical canal and averages 1.5 to 2 cm in length. The cervix may protrude 0.5 to 1 cm into the vagina but maintains an abdominal position.

The estrogen-stimulated cervix feels firm and lies dorsal to the urinary bladder. The cranial vagina is limited by the fornix, which extends ventral and cranial to the cervix.

A dorsal median fold of tissue has been described that extends caudally from the vaginal portion of the cervix. When viewed through a speculum, the caudal portion of the fold and constriction of the lateral and ventral vaginal walls give the appearance of a cervix (i.e., **pseudocervix**), with a ventral "fissure" .

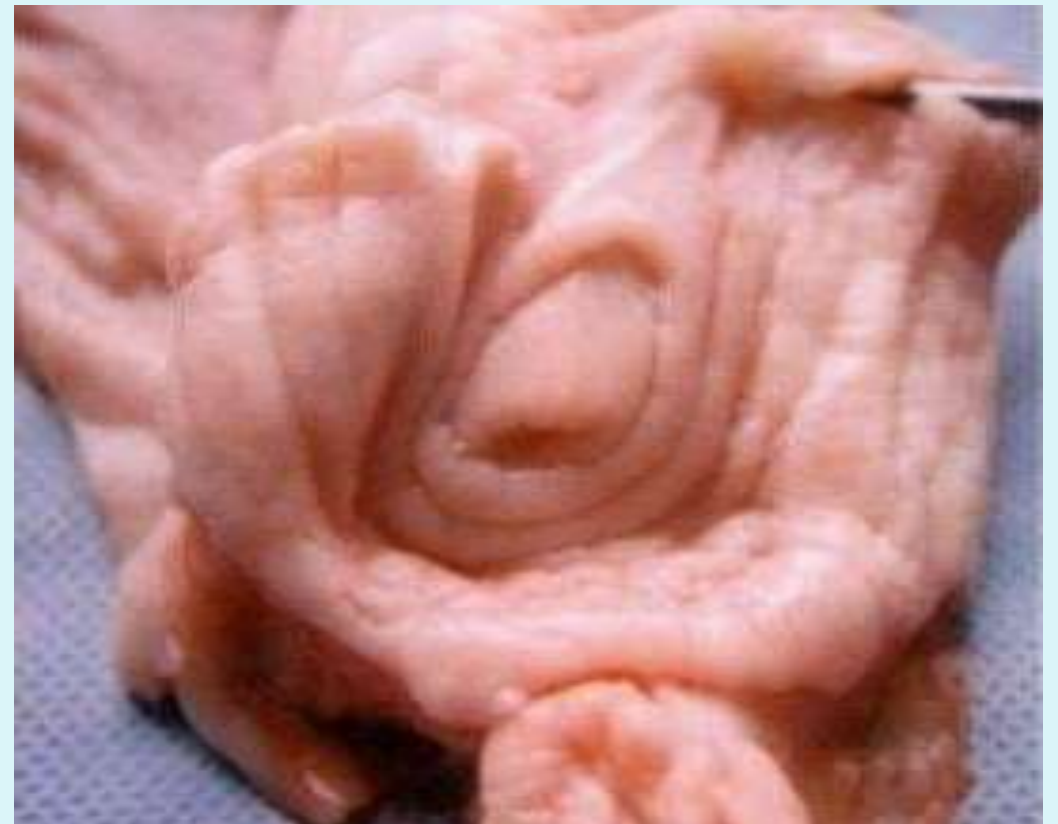- The true vaginal portion of the cervix is cranial to, and often obscured by, the **pseudocervix** . The constriction of the vaginal walls and pseudocervix render intrauterine cannulation per vagina difficult.
- Additionally, the cervical canal is nearly perpendicular to the long axis of the vagina and uterine body, further impeding easy cannulation. Muscular hypertrophy of the dorsal fold of tissue and cervix begins in proestrus, reaches maximal size in estrus, and begins to regress in early diestrus.

Camel Cervix

- Soft with longitudinal folds 3 or 4 in number
- Consistency of cervix does not differ with that of the uterus which makes it difficult to identify by rectal palpation
- Cervix projects caudally in the vaginal cavity forming a fornix (1-1.5 cm)

Cervical canal presents longitudinal folds which extend on annular muscular projections and form the cervical rings

The external cervical orifice is surrounded by 1-2 circular indented rings of the cranial part of the mucosa of the vagina



VAGINA

- This is a musculo-membranous organ connecting the cervix and external genitals. The vaginal wall consists of surface epithelium, muscular coat and serosa.
- The muscular coat is less developed compared to the uterine musculature.
- The muscularis is well supplied with blood vessels, nerve fibres and loose and dense connective tissue.
- The cow is unique in possessing an anterior sphincter muscle in addition to the posterior sphincter found in other farm animals.

- The surface epithelium of the vagina changes in species like bitch and cat in relation to the stage of the estrous cycle.
- The blood supply in the vagina increases during estrus.
- The vaginal fluid is a transudate through the vaginal wall that is mixed with vulvar secretions from sebaceous and sweat glands.
- The pH of vaginal mucosa is **5.7** and immunogenic response in the vagina is maximum.
- A blind pouch of vagina near the cervix is known as fornix. The fornix of vagina is absent in the sow.
- The urethral orifice opens on the urethral tubercle in the bitch.

- The anterior and posterior segments (vestibule) of vagina are different.

ANTERIOR VAGINA

- The anterior vagina is the site of semen deposition during natural mating in the cow, buffalo, sheep and goat.
- The luminal epithelium of anterior vagina is acidic with a pH of 5.7 which acts as a bacteriostatic.
- The epithelium of the anterior vagina near cervix is secretory and secretes mucus.
- On the ventral floor of vagina beneath the mucosa and running the length of vagina the two **Gartners ducts** (remnants of primitive mesonephric ducts or or wolffian ducts are frequently present.

POSTERIOR VAGINA (VESTIBULE)

- The posterior vagina starts from the external urethral orifice and thus forms the region common to urinary and reproductive and urinary systems.
- It forms a blind pouch near the urethral opening which is known as **sub-urethral diverticulum** in the sow, ewe and cow (2.5-4.0 cm) and this is considered to prevent the entry of urine in the uterus.
- Hymen is the membranous structure that is a embryonic remnant sometimes present in the vestibule.

Vaginal and vestibular dimensions

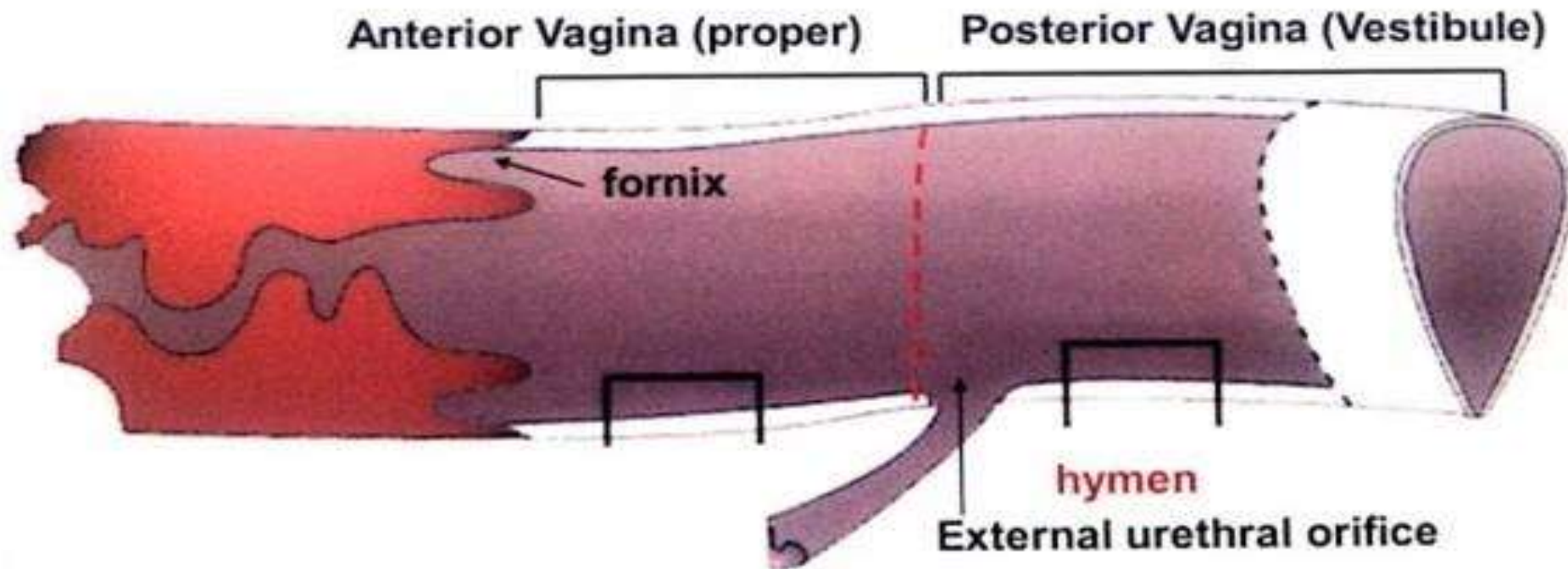
Species	Cow	Mare	Bitch	Sow	Buffalo
Vagina	25-30 cm	18-23 cm	10-14 cm	7.5-11.5 cm	13.0 to 30.0 cm
Vestibule	10-12.5 cm	10-12 cm		8.9 cm	

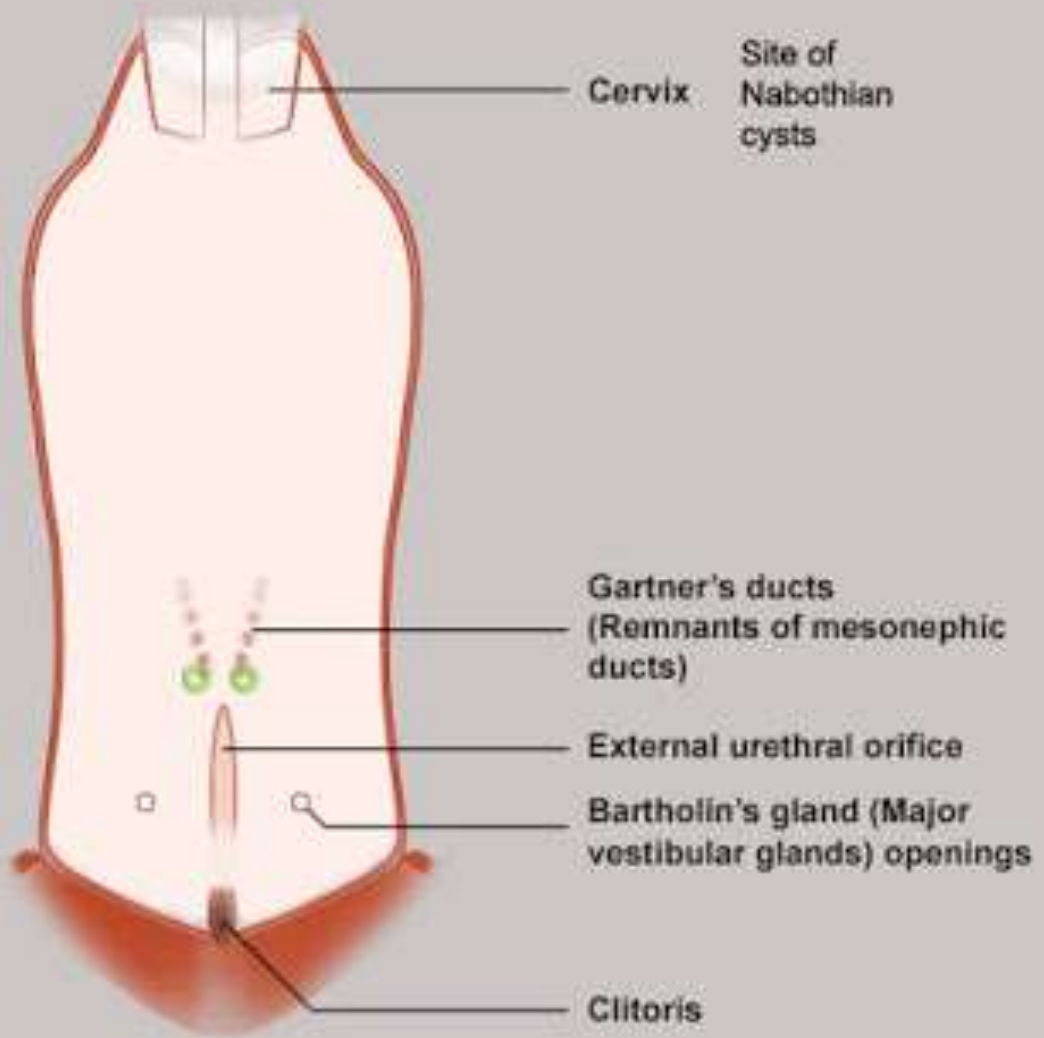
- There are two Bartholin glands, one on each side, located in the constrictor muscles of the vestibule. They are about 1.5 to 3 cm in diameter. In cows, each of these glands open to lateral wall of the vestibule about 2.5 cm caudal to the vagina by a single duct.
- The Bartholin glands secrete mucus most actively at estrus, and have a tubuloalveolar structure.
- The vestibular glands are inconsistent in sheep and different in the dog.
- Bitch, ewe, mare and some have only minor vestibular glands. Vestibular glands are small in the bitch, but numerous. Duct openings are arranged in a linear series.

Vagina and vestibule

It is musculo-membranous collapsed tube extends from the external cervical os to vulvular cleft

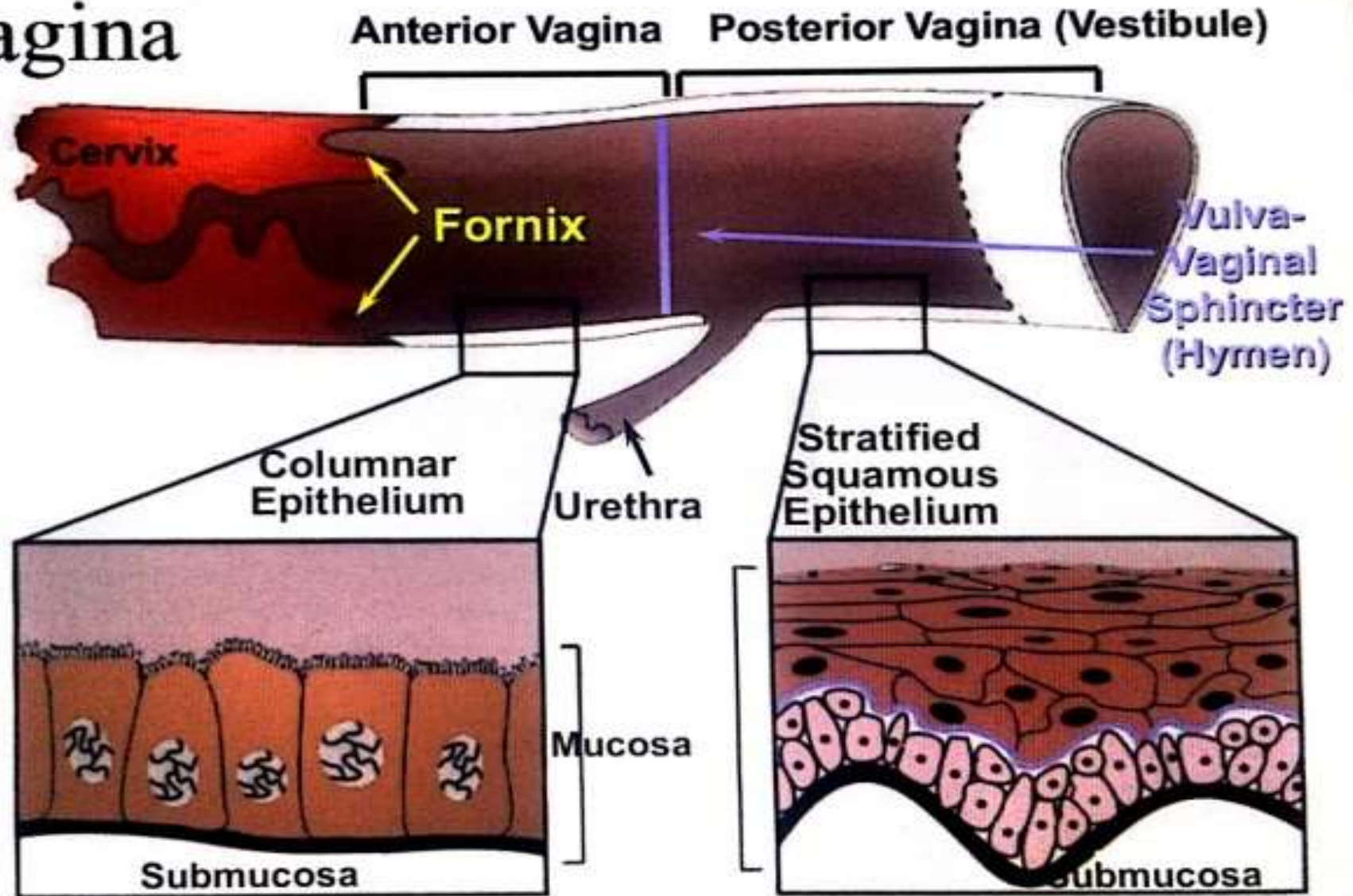
Parts of the vagina





Minor vestibular (Skene's/ female prostate) glands when developed = 

Vagina



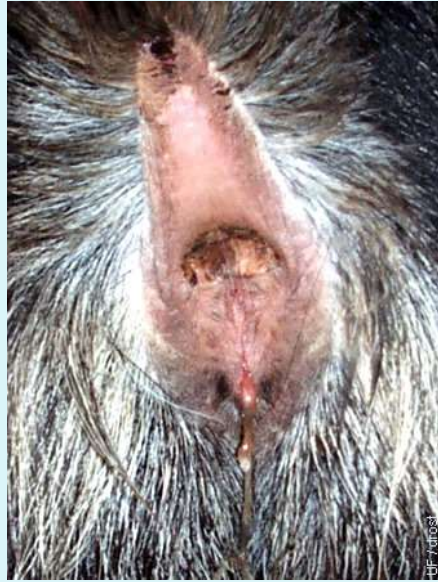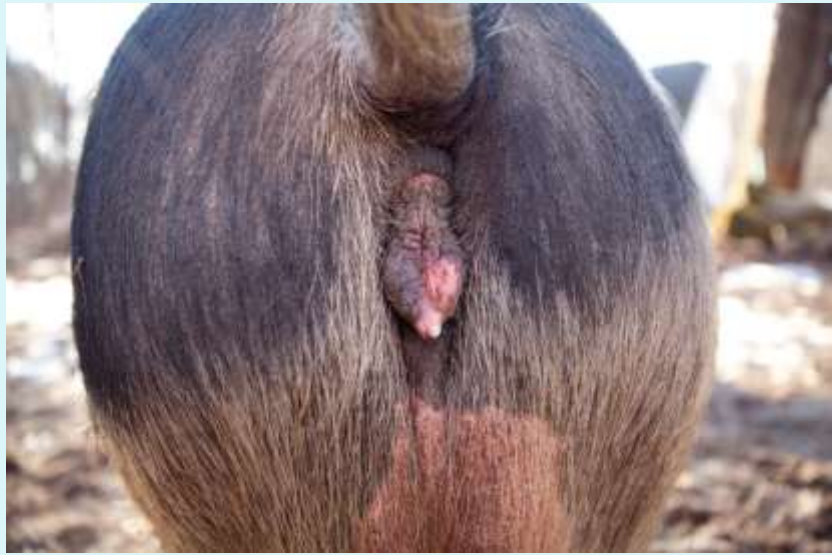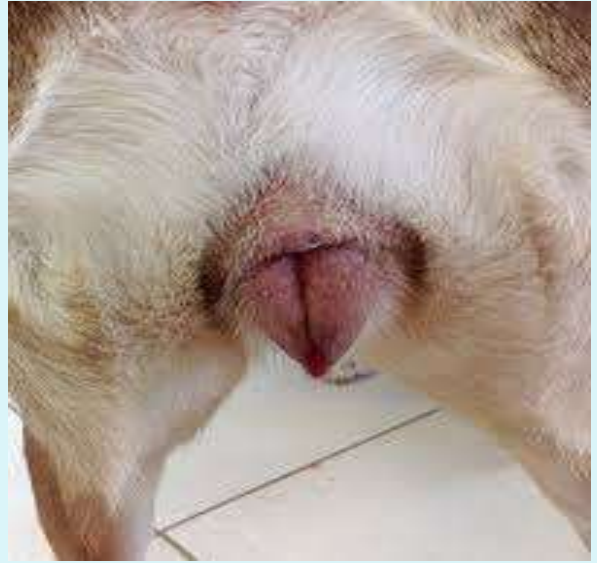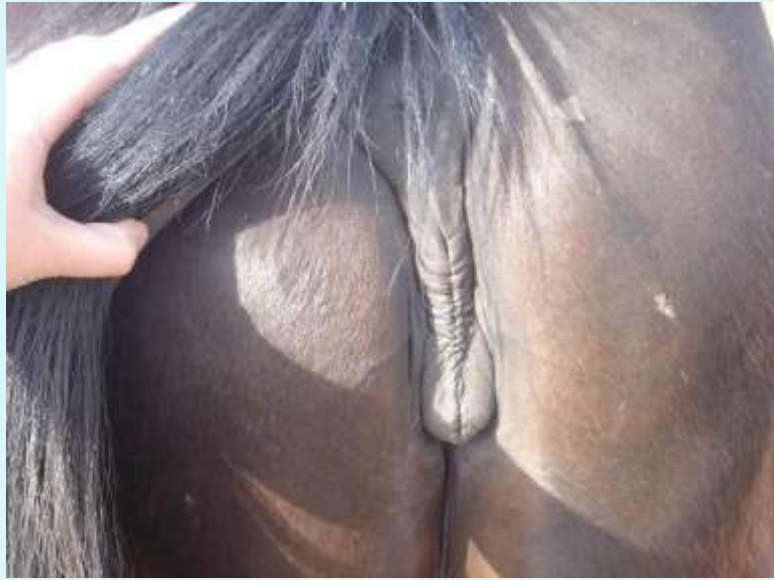
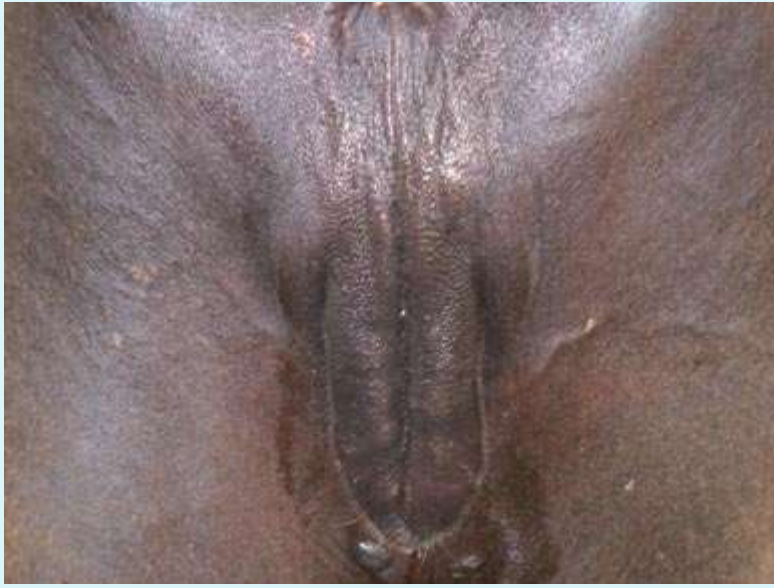Vestibular Bulbs

- Present in the mare and bitch
- Dark patches on the vestibular walls mark the position of vestibular bulbs.
- Vestibular bulbs are a concentration of veins forming erectile tissue, this is the female homologue of the bulb of the penis.
- During the dog's 'tie', the bulbs are erect and press against the penis, caudal to the enlarged bulb of the glans.

External genitals- Vulva

- The vulva is formed by two labia that meet at dorsal and ventral commissures surrounding the vertical vulvar opening. The dorsal commissure is rounded in cow and sheep whereas the ventral commissure is pointed.
- In the mare the dorsal commissure is pointed and the ventral is rounded.
- The vulva provides anatomical closure to vagina so as to minimize entry of foreign material into vagina.

- The **vulva** is the opening to the reproductive system. Its functions are the passage of urine, the opening for mating and as the birth canal. Included in the **vulva's** structure are the lips, vestibule and clitoris. The **vulvar** lips are located at the opening and appear wrinkled and dry when the **cow** is not in heat.



Clitoris

- Partial homologue of the penis.
- Located within the ventral commissure of the vulva.
- Can be divided into two parts:
 - Body (corpus)
 - Glans (glans clitoridis)
- Has left and right crura that attach to the ischiatic arch.
 - Crura come together to form the body.
- Lies within a fossa, largely covered by a mucosal fold which is the female equivalent of the prepuce.
- The glans is the only exposed part of the clitoris.

- The clitoris is composed of erectile tissue covered by stratified squamous epithelium and is well supplied with sensory nerve endings. In the cow the greater part of the clitoris is covered under the mucosa of the vestibule. In the mare, however it is well developed and has a fossa (fossa clitoridis) and in the sow it is long and sinous terminating in a small cone.

Os Clitoridis

- Found radiographically in some bitches.
- Homologue of the os penis

THANK YOU