Ultrasonography in Animal Reproduction

Prof G N PUROHIT

Head, Department of Veterinary Gynecology and Obstetrics, College of Veterinary and Animal Science, Rajasthan University of Veterinary and Animal Sciences, Bikaner, Rajasthan, India

Definition

- High frequency Sound waves inaudible to human ear (20-20000 Hz)

Basic Principle

- The ultrasound equipment basically consists of a transducer and a scan converter.
- The transducer is the ultrasound producing part.
- It is fitted with a piezoelectric crystal (Lead – zirconate – titanate or others) which when stimulated by a high voltage current emits the ultrasound.

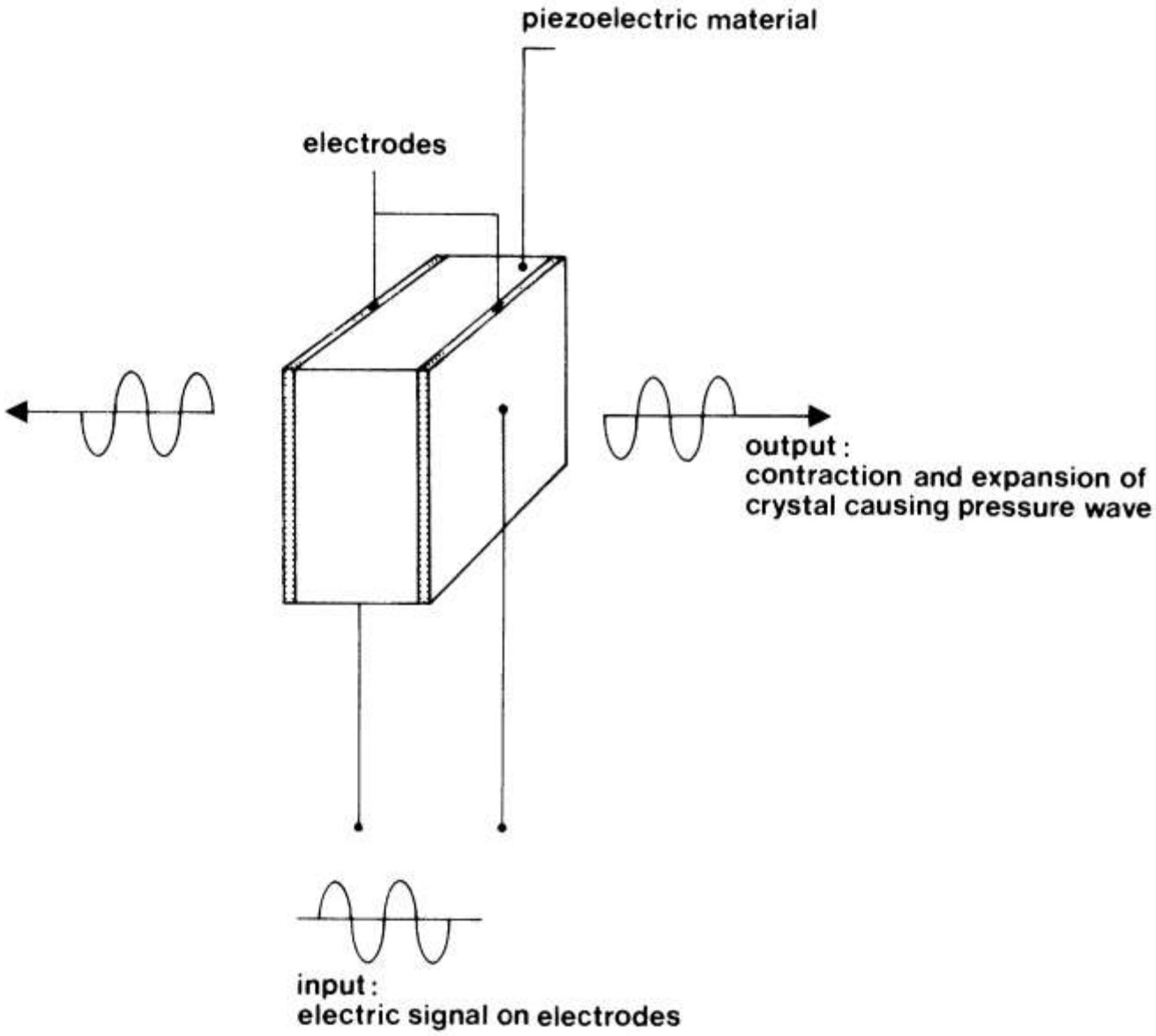
piezoelectric material
electrodes
output :
contraction and expansion of
crystal causing pressure wave
input :
electric signal on electrodes

- The ultrasound is transmitted to the patient from the transducer and propagates through the tissues.
- The ultrasound beam is either reflected back, partially absorbed or entirely absorbed. The returning beam (echoes) meets back and deforms the crystals in the transducer.

- This mechanical energy is converted back to an electrical signal proportional to the strength of the echo and delayed by a time roughly proportional to the distance traveled.
- The scan converter interprets the variations in brightness displayed on the cathode ray tube of a B-mode system (or as a variation in amplitude in A-mode oscilloscope screen) and also stores images when required.

- The ultrasound is emitted in a pulse – echo manner. A pulse of ultrasound is emitted and its reflection perceived prior to emission of the next pulse.

How Ultrasound Image is constructed

1. Electrical Energy converted to Sound waves

- Acoustic Impedance
- Velocity
- Frequency
- Reflection
- Amplification

2. The Sound waves are reflected by tissues

3. Reflected Sound waves are converted to electrical signals and later to Image

Acoustic Impedance

- **Acoustic impedance** (**Z**) is a physical property of tissue. It describes how much resistance an ultrasound beam encounters as it passes through a tissue.
- Acoustic impedance depends on:
- the density of the tissue (d, in kg/m^3)
- the speed of the sound wave (c, in m/s)
- and they are related by:
- **Z** = d x c

- Examples of impedance for bodily tissues (in $kg/(m^2s)$):
- air 0.0004×10^6
- lung 0.18×10^6
- fat 1.34×10^6
- water 1.48×10^6
- kidney 1.63×10^6
- blood 1.65×10^6
- liver 1.65×10^6
- muscle 1.71×10^6
- bone 7.8×10^6

Types of instruments

- For most diagnostic veterinary purposes B-mode, real time ultrasonography is used employing different types of transducers.
- Linear transrectal transducer (frequencies of 5-10 MH_z)

  and the

  Sector trans-abdominal transducer (frequencies of 1.0-4.0 MH_z).

  For most reproductive diagnostic work, linear array transrectal transducers are employed in cattle, buffaloes, mares and female camels. Small sized transrectal transducers are also used for early pregnancy diagnosis in small ruminants (sheep and goat).

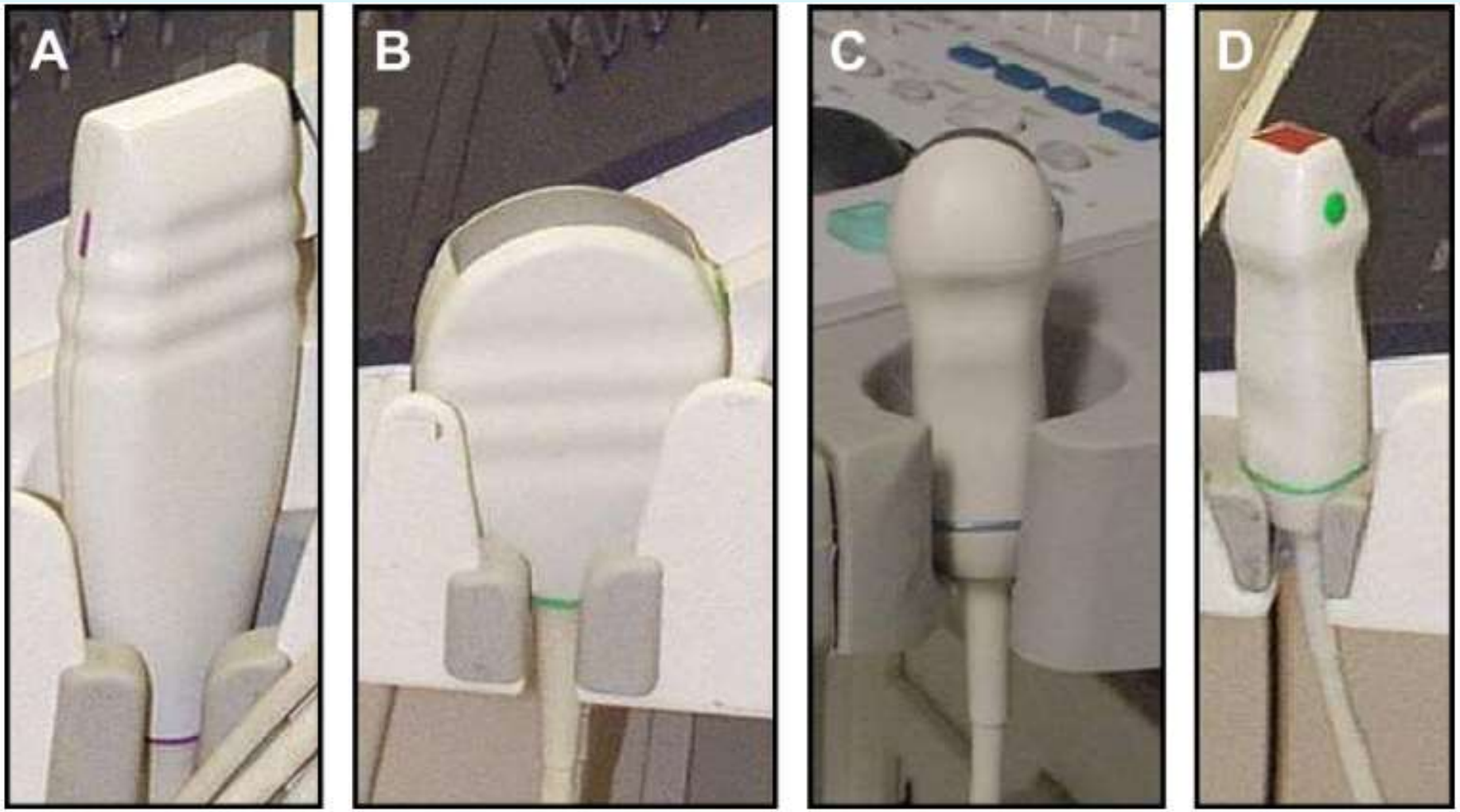

Fig. 2. Examples of available types of probes for ultrasound imaging: (*A*) linear probe, (*B*) curvilinear probe, (*C*) sector scanner, and (*D*) phased array.

Images by a sector and linear probe

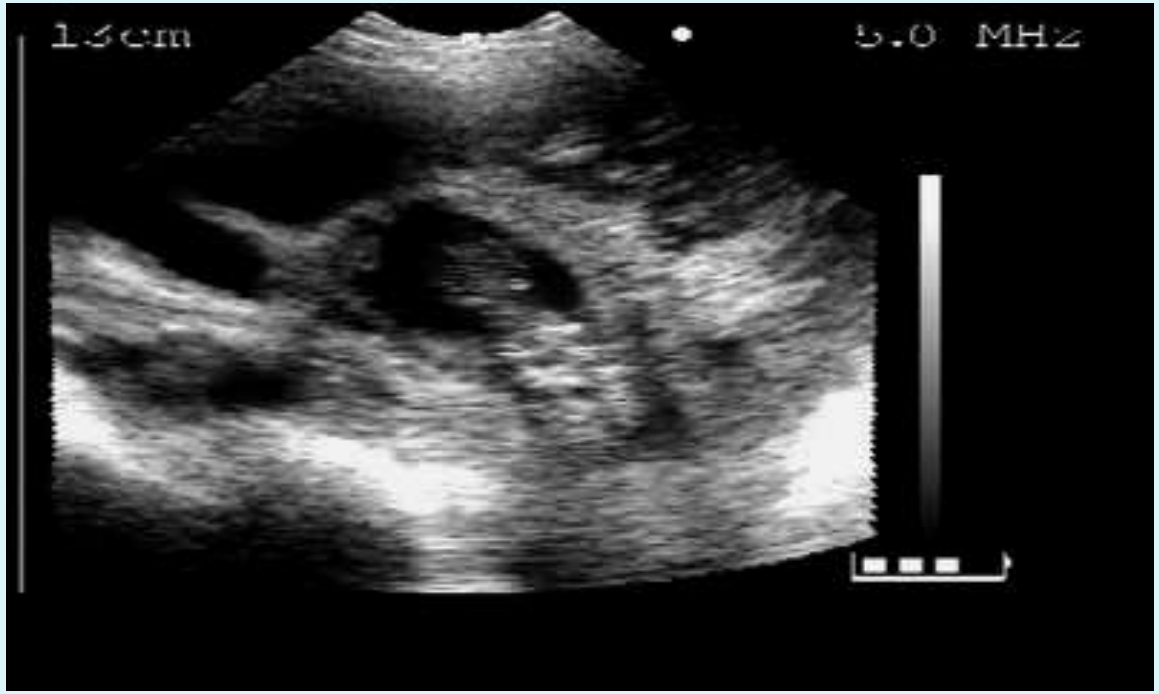

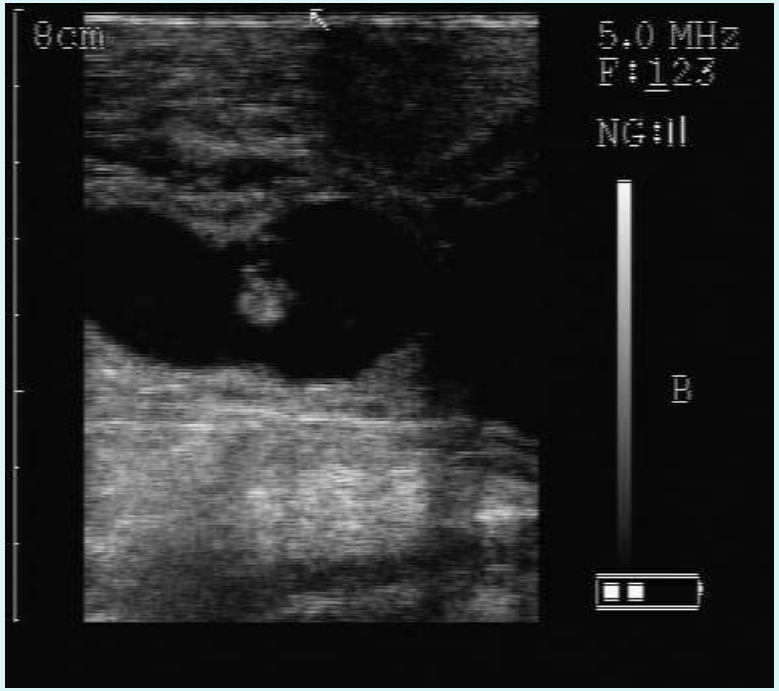

- **A- mode** Amplitude modulation. A one-element (one dimensional) display with time (distance) on the horizontal axis.
-
- **B-Mode** Brightness modulation. A compound A-mode scan with amplitude translated into a brightness scale. Location on the display is related to position and depth.

- **Doppler ultrasound** When an ultrasound beam meets a moving object the reflected ultrasound is either of increased or decreased frequency, depending upon whether the motion is towards or away from the transducer.

- **Echogenic** A structure causing a marked reflection of the ultrasound beam. A change in echogenecity in a homogeneous structure may indicate a pathological change.
- **Hperechoic** Showing increased echogenecity.
- **Hypoechoic** Showing decreased echogenecity.
- **Attenuation in ultrasound** is the reduction in amplitude of the **ultrasound** beam as a function of distance through the imaging medium

Echotexture terminology

Echotexture terminology of a tissue structure relative to the surrounding tissue



Ultrasound artifacts

- An **ultrasound artifact** is a structure in an **image** which does not directly represent actual tissue being scanned.
- Artifact assumes different forms including :
  - Structures in the image that are not actually present
  - Objects that should be represented but are missing from the image.
  - Structures which are misregistered on the image.

Common artifacts in reproductive ultrasound

- Artifacts in ultrasound may be divided into two main categories:
- (1) artifacts related to the operator, such as wrong settings (power, gain, frequency) or poor patient preparation, which impair image quality;
- (2) artifacts that result from ultrasound interactions with tissues (absorption, reflection or refraction). If adequately identified, they may be useful in the characterization of a lesion.

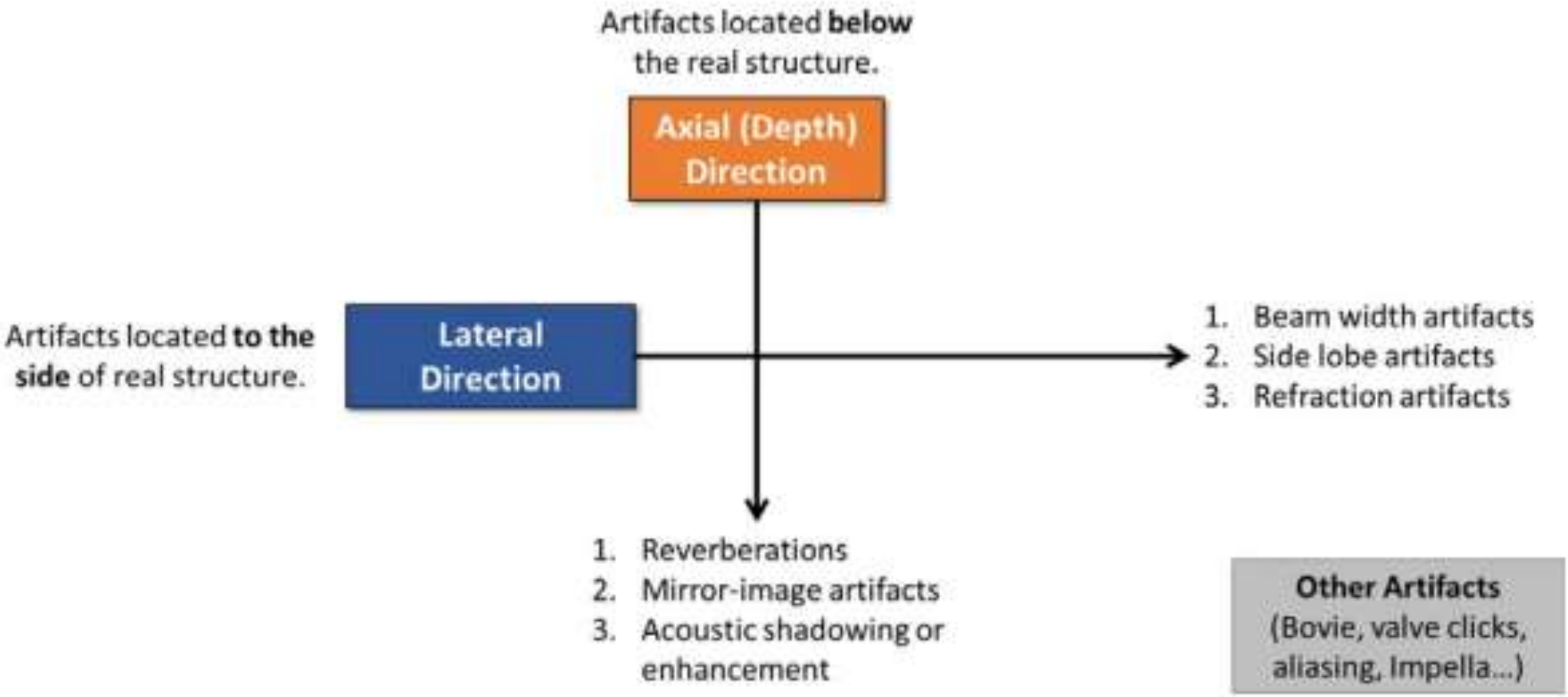
Artifacts located **below** the real structure.
Axial (Depth) Direction
Artifacts located **to the side** of real structure.
Lateral Direction
1. Beam width artifacts
2. Side lobe artifacts
3. Refraction artifacts
1. Reverberations
2. Mirror-image artifacts
3. Acoustic shadowing or enhancement
Other Artifacts
(Bovie, valve clicks, aliasing, Impella...)

Reverberation

- This is the production of false echoes due to repeated reflections between two interfaces with a high acoustic impedance mismatch
- The air between the probe and the skin is the main cause of reverberation (external reverberation).
- Reflectors such as intestinal gas and bones are causes for internal reverberation. This artifact is characterized by formation of several hyperechoic lines that are equally spaced and gradually attenuated

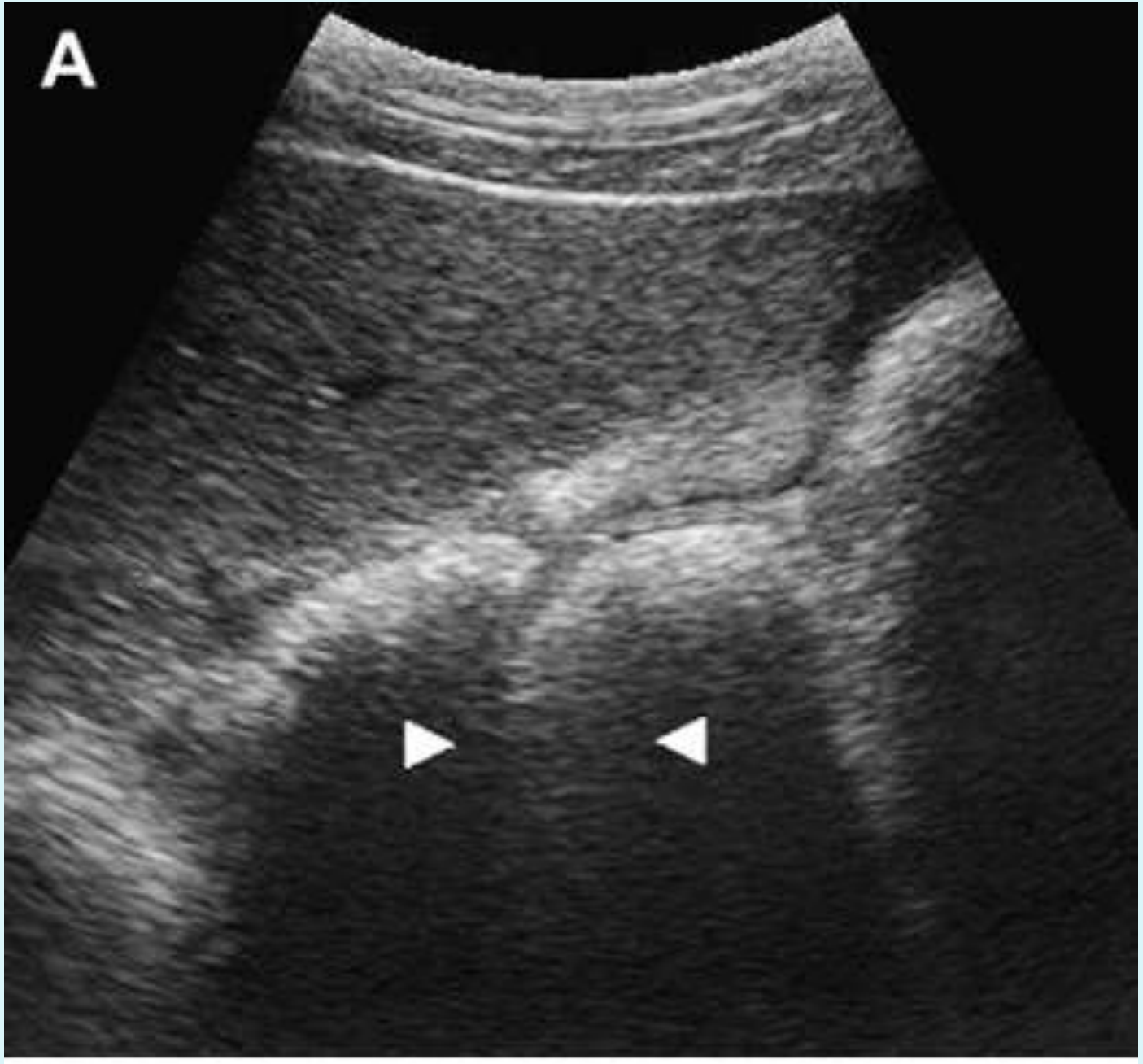

Gas within the spiral colon is creating reverberation artifacts (white arrowheads) characterized by several hyperechoic lines, equally spaced and
gradually attenuated.

Reverberation

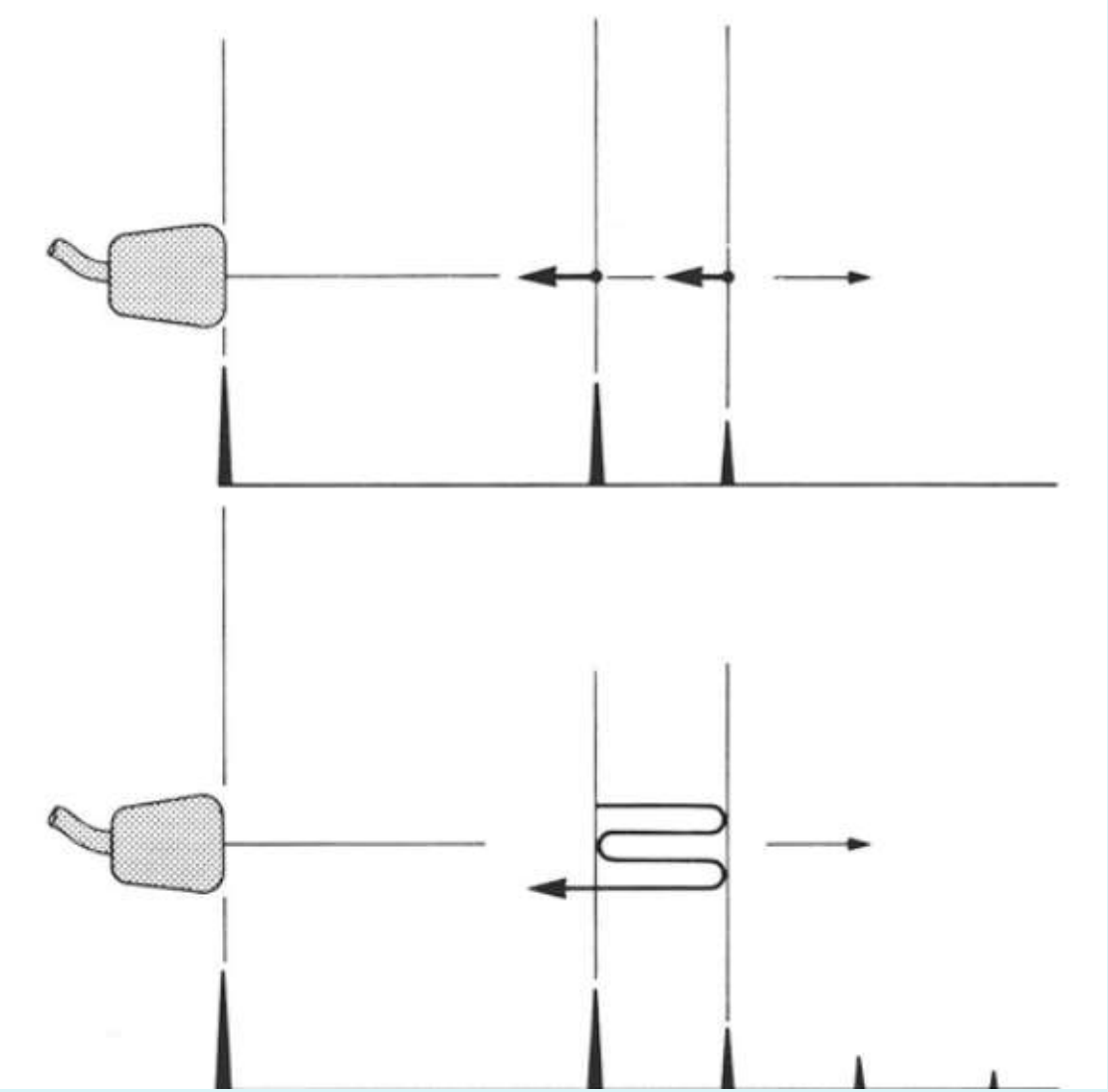

COMET TAIL ARTIFACT

- The comet-tail artifact is a type of reverberation artifact met with small reflective surfaces as gas bubbles or small metallic objects and is characterized by the formation of a narrow beam of closely spaced, discrete, hyperechoic lines

Comet-tail artifact represented by a narrow beam of closely spaced, discrete, hyperechoic lines (white arrowhead).

Acoustic Shadowing

- Acoustic shadowing appears as an anechoic area distal to a structure that strongly attenuates the ultrasound, such as bone or any mineralized or dense material (eg, metal, wood, fibrosis.

Acoustic shadowing artifact. The hypoechoic band (white arrowheads) superimposed on this image is the result of attenuation of part of the ultrasound beam by a focus of dense
material (mineralized or fibrous tissue) in the near field.

Distal Acoustic Enhancement

- Distal acoustic enhancement is caused by augmentation of the amplitude of the echoes (brighter so whiter) distally to a structure with a low attenuation (more often fluid). It is convenient for identifying fluid-filled structures, such as cysts

- It may be reduced by decreasing the differential gain at this level.

Distal acoustic enhancement artifact. The increased echogenicity distal to this gravid uterus (asterisk) is caused by the augmentation of the amplitude of the echoes distally to allantoic and amniotic fluid with a low attenuation

Diagnostics

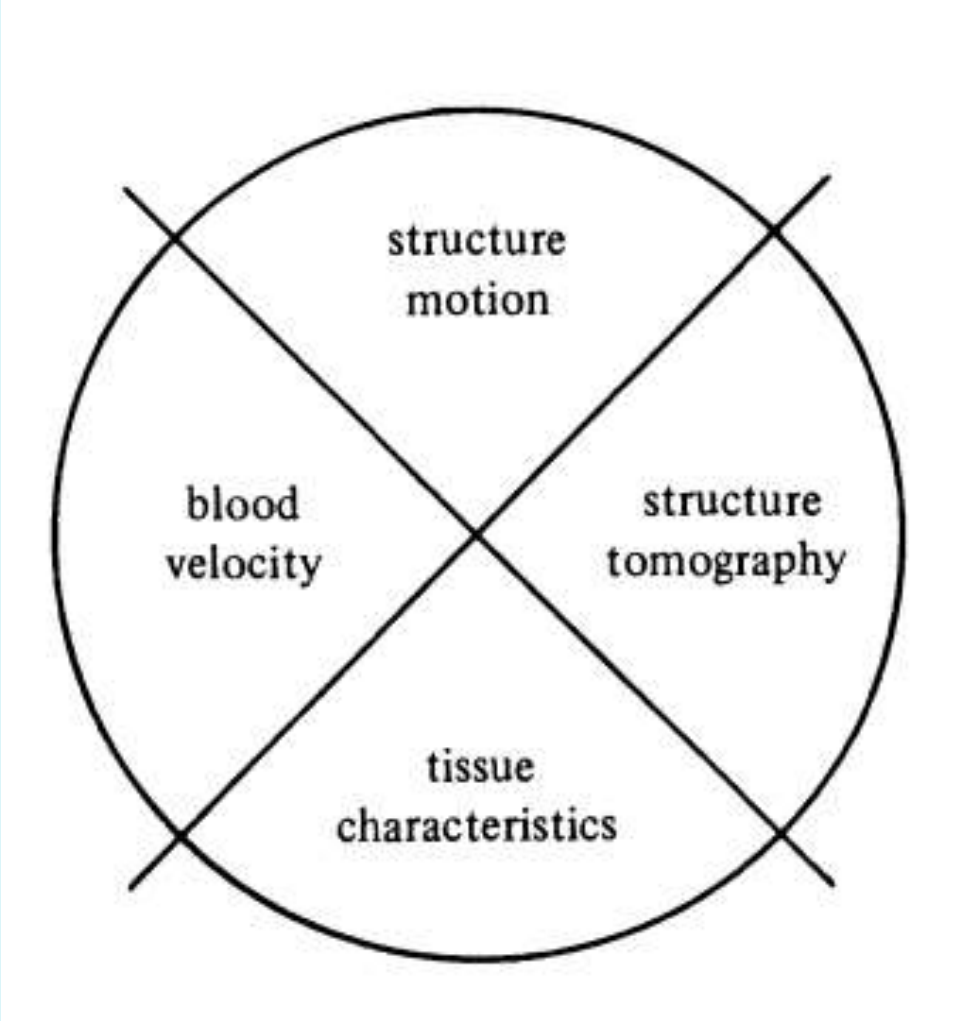

Reproductive diagnostics

1. Evaluation of ovarian and uterine physiology and pathology

- Ovarian follicle, CL, Cysts, tumors, etc..
- Studying ovarian follicular dynamics
- Ovarian blood supply by color doppler
- Normal uterine echotexture, estrus
- Growths or fluid accumulations such as mucometra, pyometra, tumors

2. Evaluation of pregnancy & gestational physiology

- Pregnancy diagnosis
- Fetal heart beat
- Fetal sex determination
- Determination of gestational age
- Fetal numbers and viability
- Estimating abnormal pregnancies
- Fetal growth assessments
- Early embryonic losses

3. Interventions

- Ultrasound guided ovum pick-up for IVF
- Ultrasound guided aspiration of fetal contents of one fetus in twin pregnancies.
- Aspiration of amniotic or fetal fluids

Patient preparation

- For transrectal examination the probe is placed in a sleeve or condom with gel inside.
- The animal is restrained and the rectum is evacuated from the feces.
- The probe is inserted in the rectum and the ovaries and uterus are scanned.

- For every transcutaneous ultrasonographic examination, the area has to be shaved and the skin cleaned with water or alcohol. Acoustic gel is then applied to improve the contact between the probe and the skin.

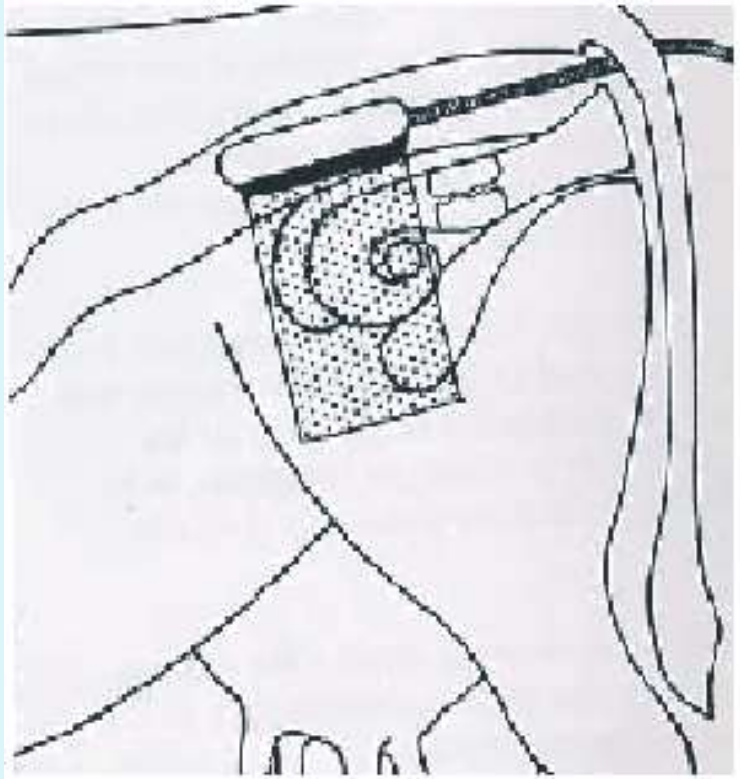

Ultrasonographic features of early pregnancy in various species

Sonographic Structure appearance (days post mating)	Cow	Buffalo	Mare	Sheep/ Goat	Sow	Bitch	Camel	Cat
Fetal fluid	18-20	18-22 days, 5th week	10-16	20-25	18-20	18-20	17-18	10-16
Fetal Heart beat	24	30	24-25	21-23	–	24	28-30	16-18
Fetus	28-30	20-26day, 4th week	20-22	25-30	25-30	–	23-25	16-20
Cotyledons /Allantois	35-40	30-35	20-22	40-50	–	–	–	25
Fetal bones fetal buds	57-60	–	–	70	–	42-50	40 days	30-33
Fetal sex determination	57-60	10-18 weeks	60-70	60–90	–	–	–	38-43
Fetal movement	42-50	47-51	40-45	–	60	–	–	30-34

Probe requirements for pregnancy diagnosis in domestic animals

	Cattle	**Buffalo**	**Mare**	**Sheep/ Goat**	**Sow**	**Bitch**	**Camel**	**Cat**
TYPE OF PROBE	Trans Rectal Linear 5-10 MHz	Linear Trans-rectal 5-10 MHz	Linear Transrectal 5-10 MHz	Up to day 40 Linear Rectal 5-10 MHz Beyond day 40 2.5-4.0 MHz	A mode or Linear and Sector 3.5-10 MHz	Early pregnancy 5-10 MHz Late pregnancy 3.5-4.75 MHz	Trans Rectal Linear 5-10 MHz	Early pregnancy 5-10 MHz Late pregnancy 3.5-4.75 MHz

Follicle

Corpus Luteum

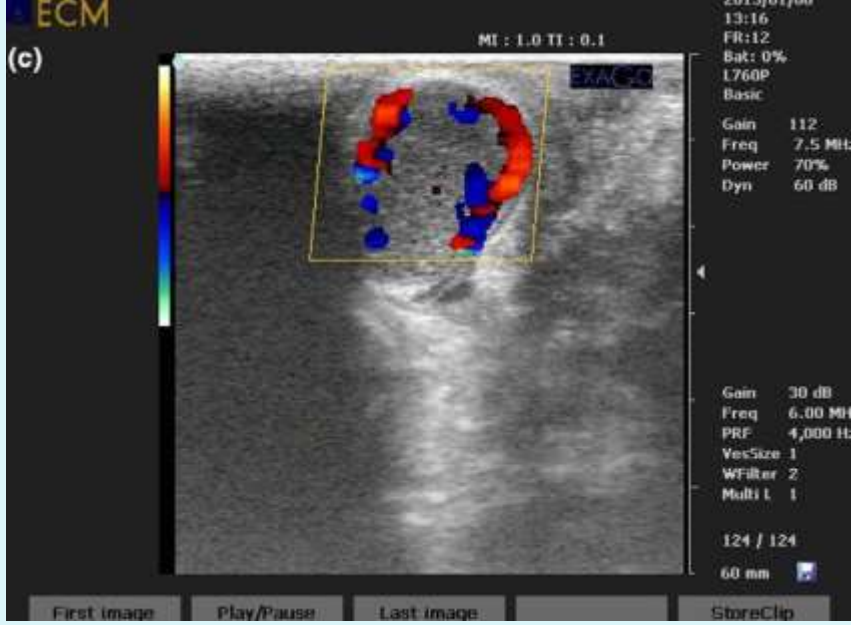

Corpus Luteum and its vascularity

Follicular Ovarian cysts

Luteal cyst

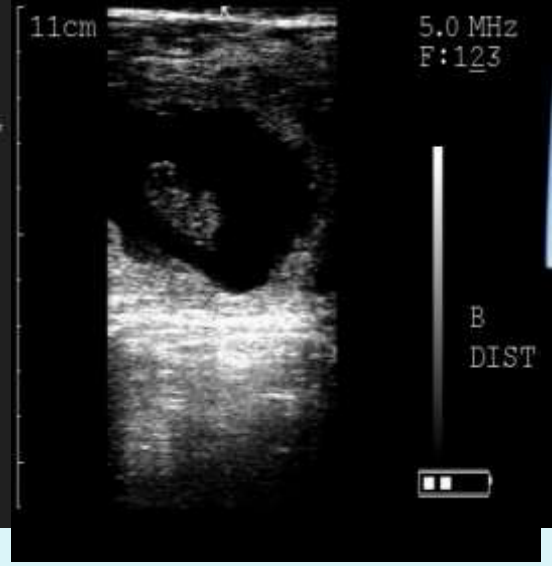

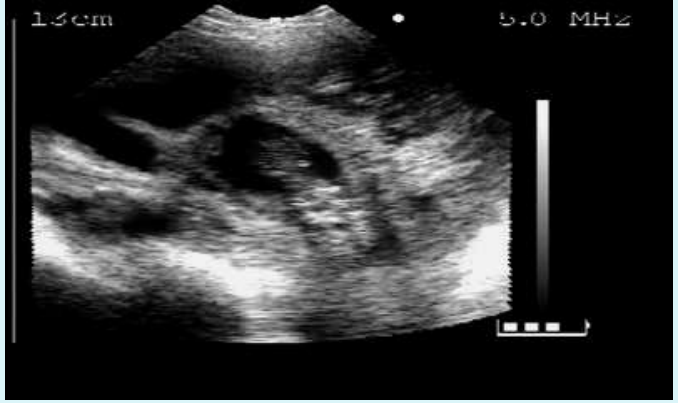

Pregnancy diagnosis in cow and goat and sow

Color Doppler finding of umbilical arteries and veins

Pyometra in a bitch

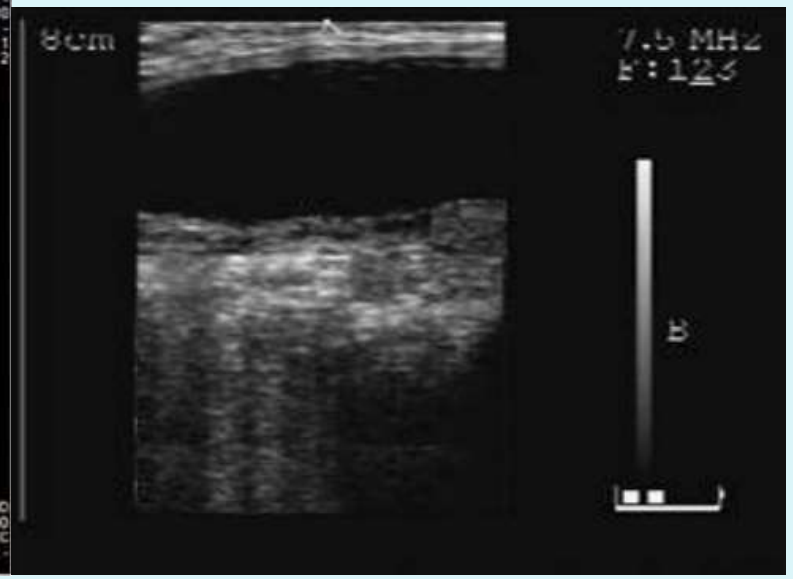

Mucometra in a cow

Thank You

Kindly share the video and subscribe to my You tube channel **Govind Narayan Purohit** if you like them