OBSTETRICAL OPERATIONS IN DOMESTIC ANIMALS

Prof G N PUROHIT

Head, Department of Veterinary Gynecology and Obstetrics,
College of Veterinary and Animal Science, Rajasthan University
of Veterinary and Animal Sciences, Bikaner, Rajasthan, India

OBSTETRICAL OPERATIONS:

1. DELIVER VIABLE FETUS
2 PREVENT INJURY TO DAM

Normal Birth posture

OBSTETRICAL OPERATIONS

Obstetrical operations are the procedures used for correction of dystocia and include **mutation, forced extraction, fetotomy** and **caesarean section.**

Mutation: is defined as those operations by which a fetus is returned to its normal presentation, position and posture by *repulsion, rotation, version* and *extension or adjustment of the extremities.*

- Repulsion (Retropulsion): In this the fetus is pushed back from the birth canal into the abdominal cavity where space is available for its correction. Epidural anesthesia should be given and the operators hand or a crutch repeller can be used for repulsion. Sufficient dilation and lubrication are essential.

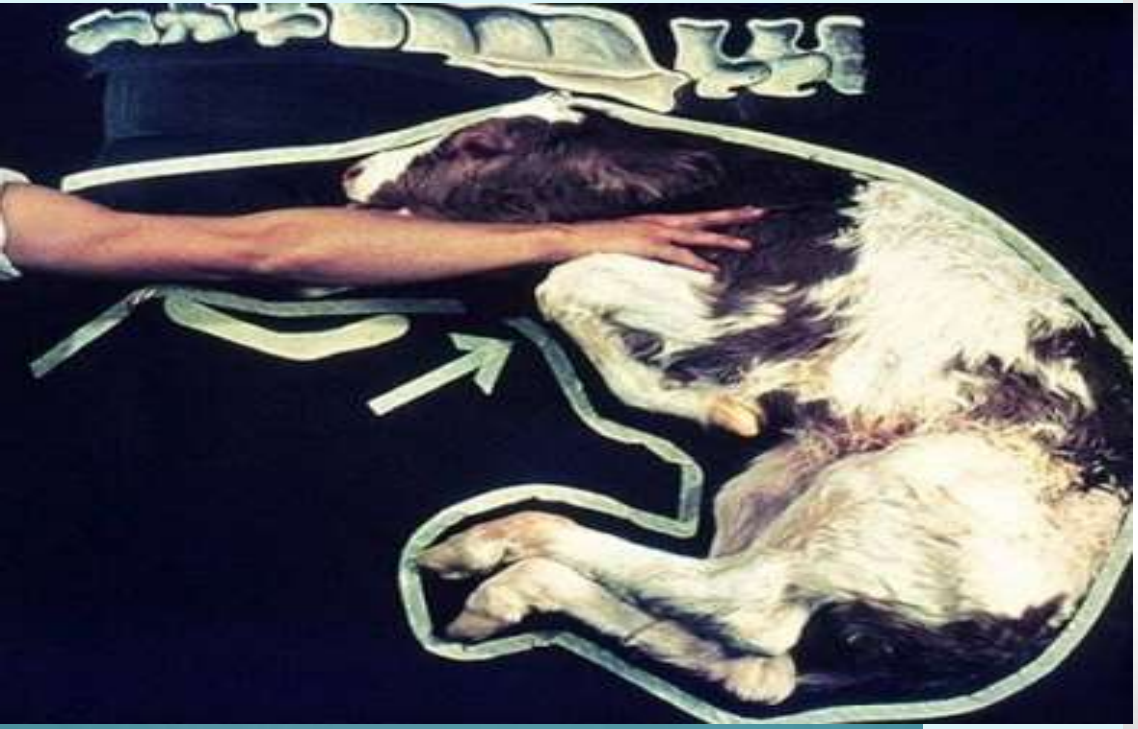

- **Name:** Kühn Crutch.
- **Use:** For retroplusion of fetus.



Rotation is the turning of fetus on its long axis to bring it into a dorso-sacral position from a dorso-ilial position. Rotation should be done by applying cross traction when the operators hand is used for correction. A detorsion rod or a cammerers torsion fork can be used for this purpose.

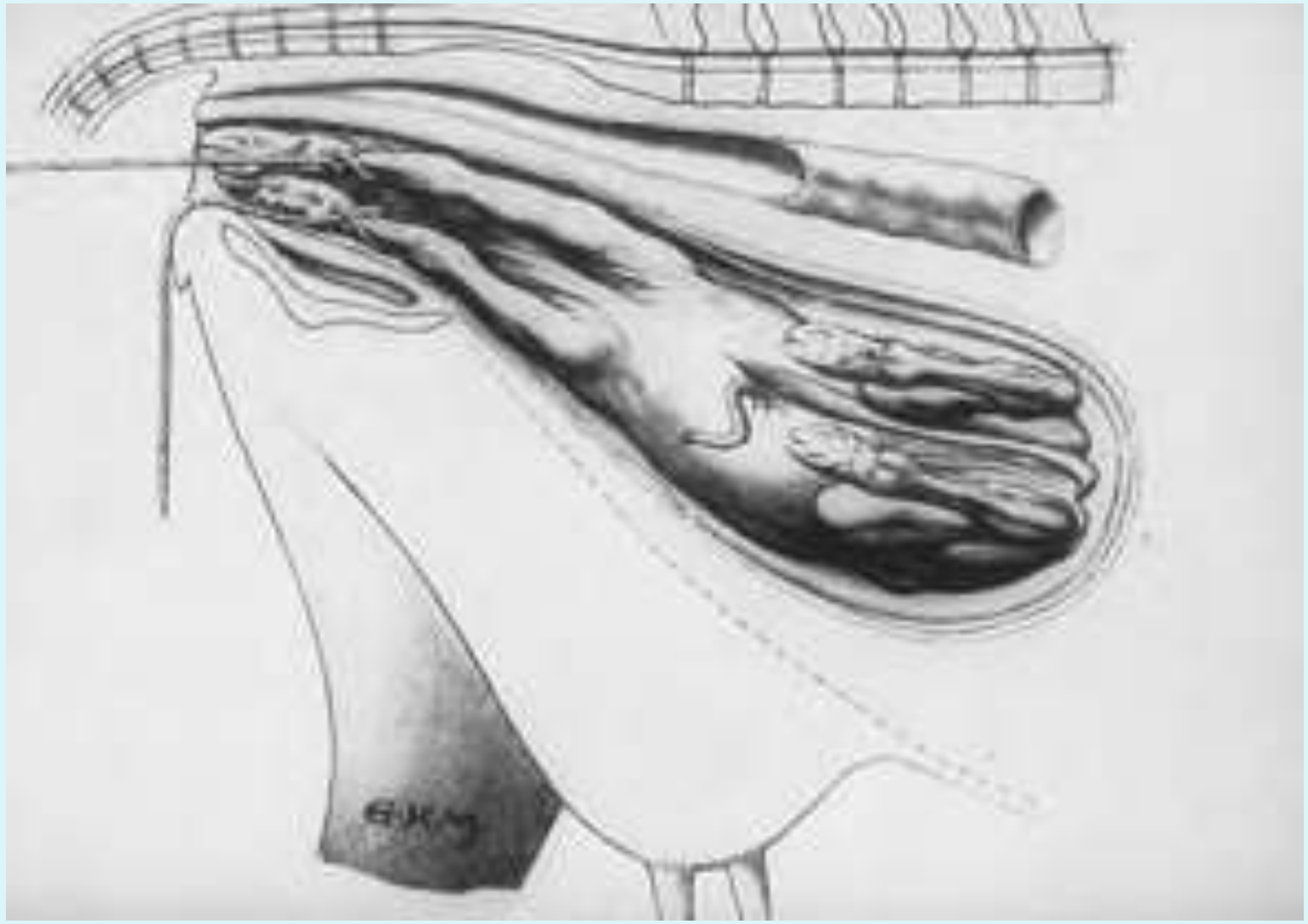

Version: is the rotation of the fetus on its transverse axis into an anterior or posterior longitudinal presentation. It should be limited to 90 degrees only and is frequently indicated for transverse equine pregnancies.

- Extension and adjustment of extremities: This is required in limb flexion or head deviation. Often ropes or long obstetrical hooks are required during correction by the operators hand. Some repulsion may be required in correction of breech presentations.
- The ropes and hooks should be used with care in live fetuses to avoid injury. Long eye hooks should be avoided in live fetuses.

Forced Extraction is defined as the withdrawal of the fetus from the dam through the birth canal by means of application of outside force. The indications for forced extraction include

1. Uterine inertia
2. Subsequent to epidural anaesthesia
3. Large fetuses
4. Small birth canal in primipara
5. Posterior presentation
6. To avoid caesarean section.

Maximum force 2-3 persons

- The force should be applied in an arc fashion first downwards and then in a straight manner.
- Traction should be steady without jerks.
- Traction is seldom required in the mare if the fetus is in normal disposition.
- The possibility of uterine torsion should be ruled out before traction and traction should be applied with care in the dairy goat as the birth canal is very fragile.
- In the bitch a vectis, snare and fingers can be used for applying traction. Calf pullers can be used for applying traction.

Forced Extraction

Ropes, chains, Calf Puller

Proper presentation, position and posture

Sufficient lubrication

Dilated birth canal

Obstetric Chains and chain pullers

Calf Puller



Producers or vets should never touch the calf puller until they can meet the rule of three. Both shoulders and the head of the calf (the three things) must be delivered into the pelvis by hand before they touch the calf jack. Manual traction on cat fetus

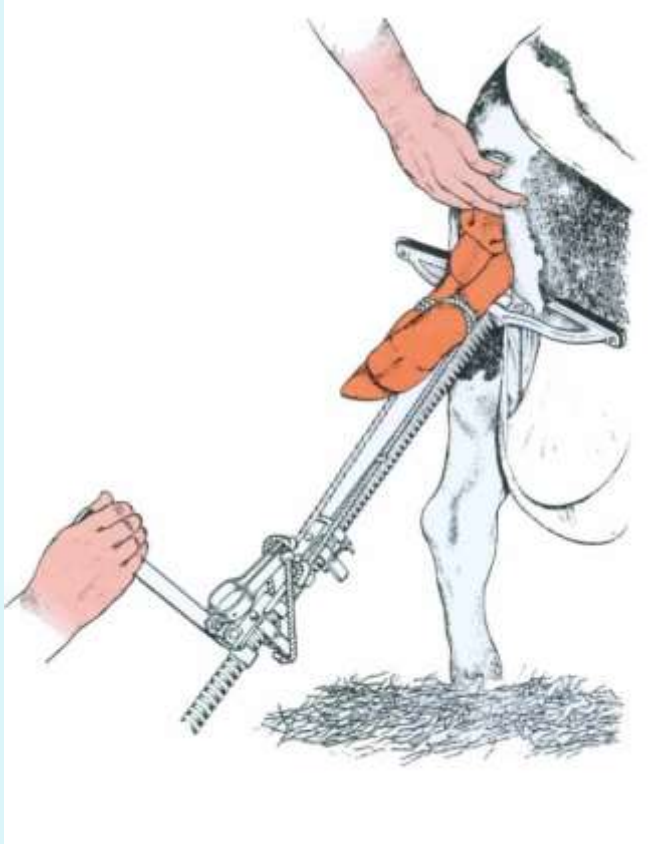

HOOKS FOR TRACTION

Blunt eye hook

Double Blunt eye hook

Krey Schottler hook

Sharp small hook

Long Obstetric Hook

Manual traction on pig fetuses

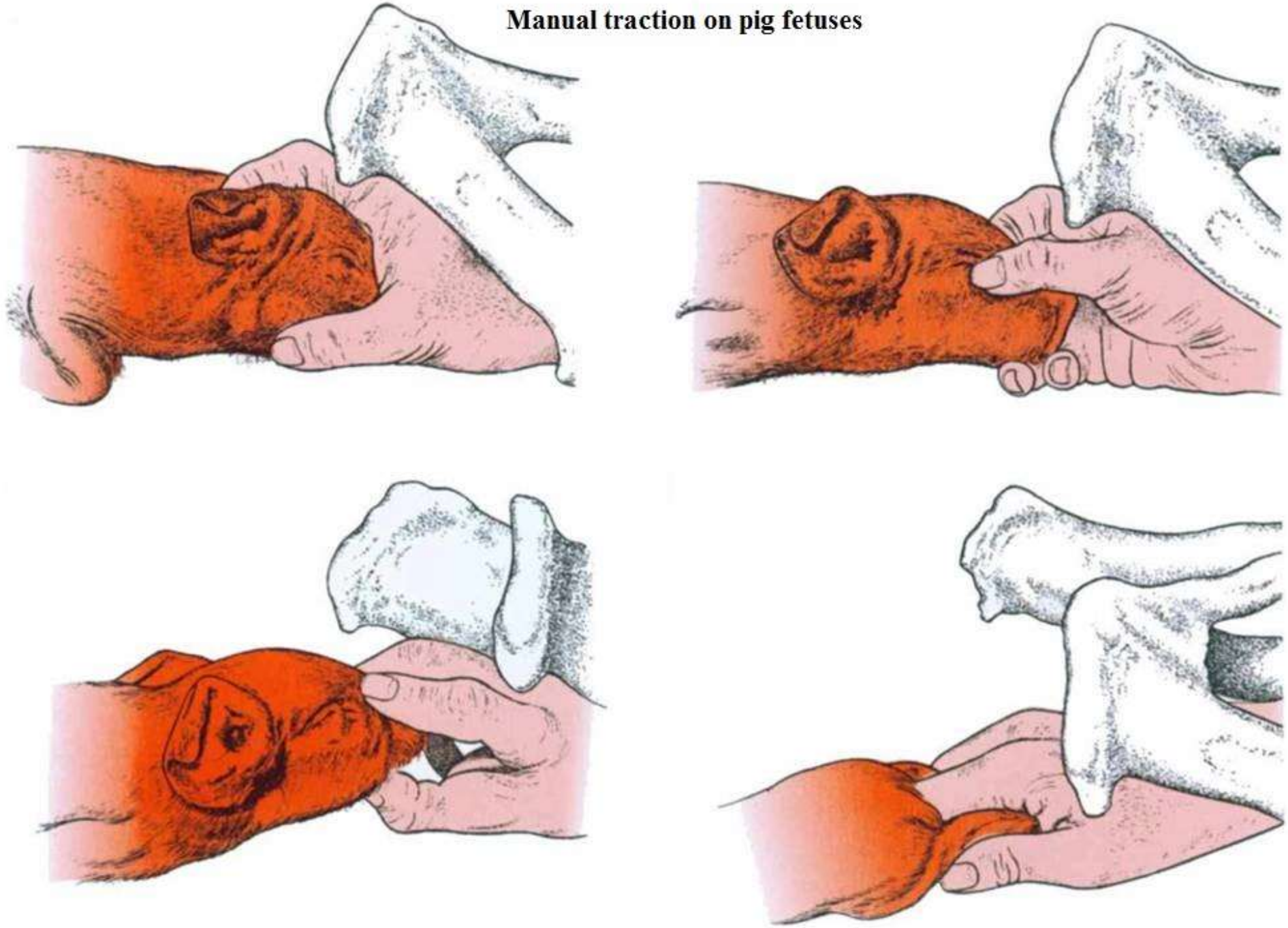

Manual traction on cat fetus

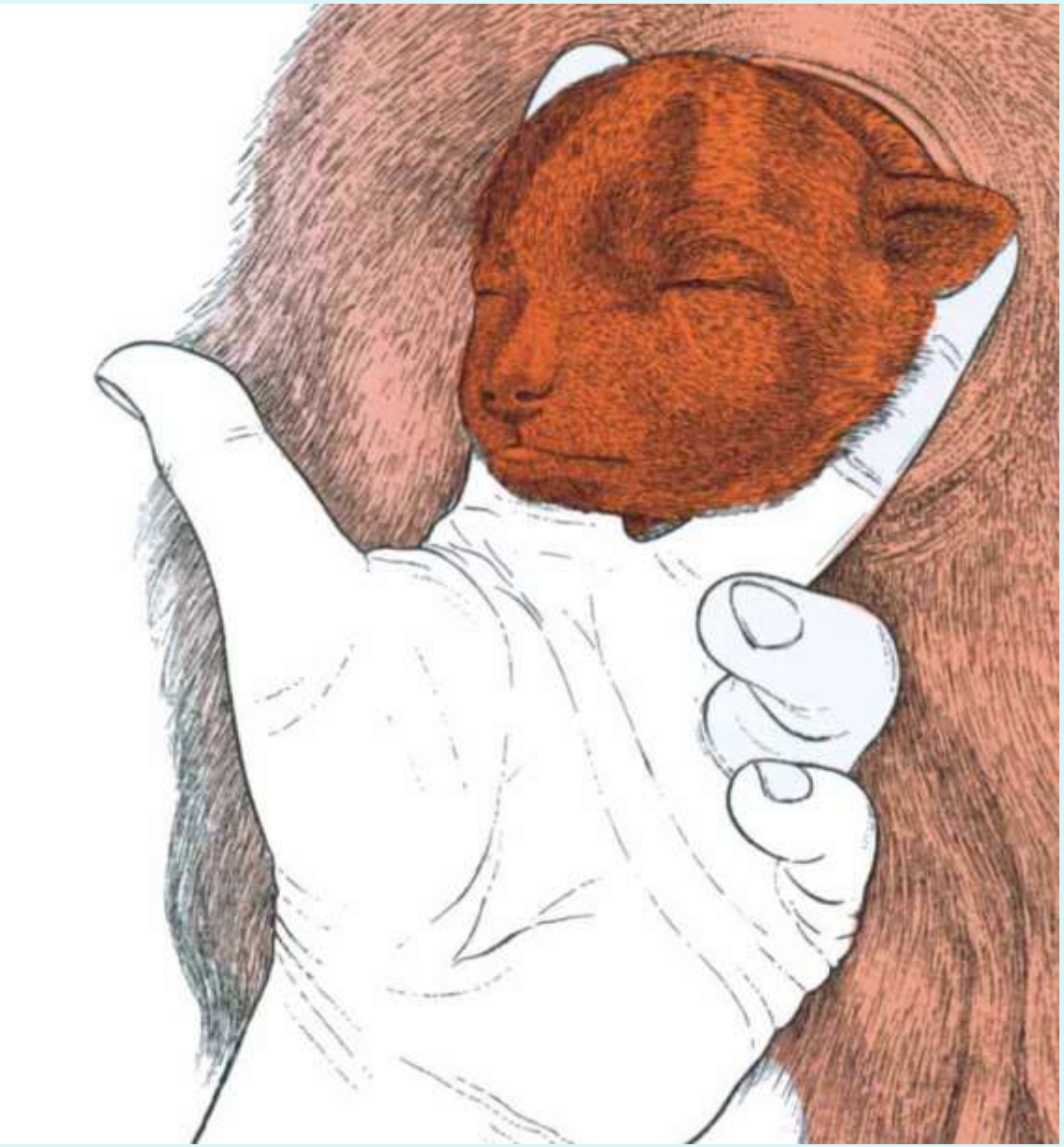

Applying traction on bitch fetuses

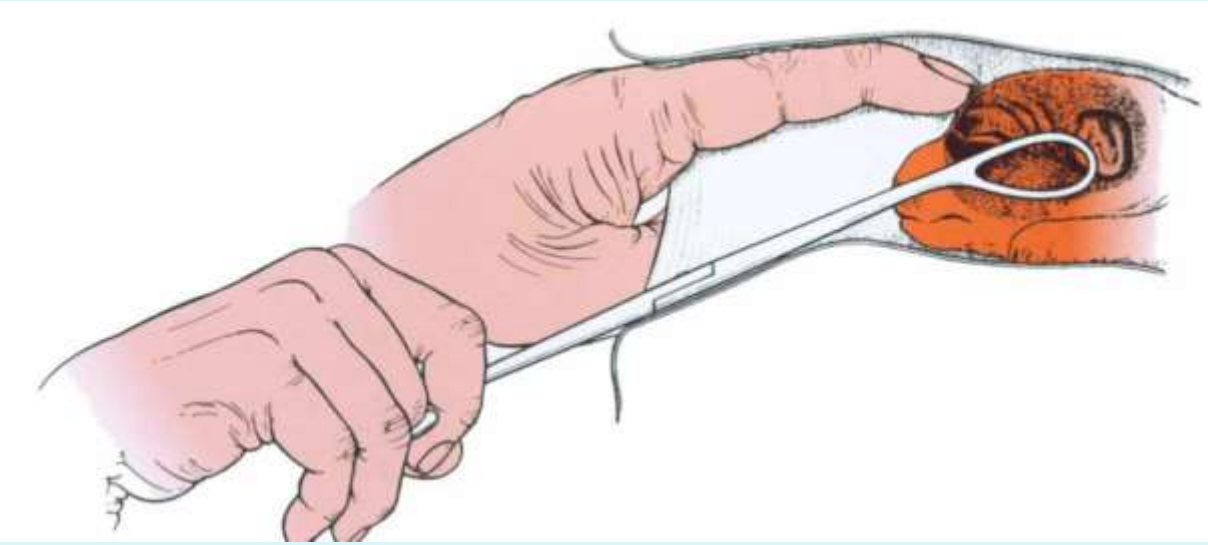

Whelping Forceps

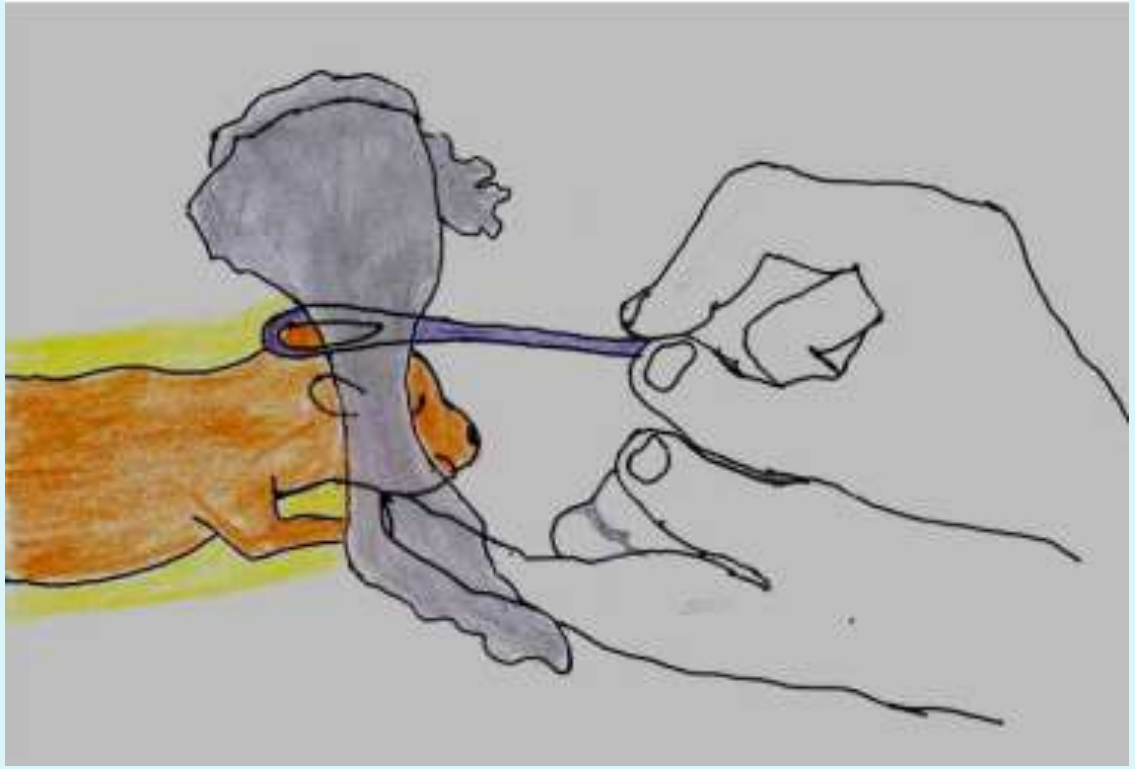

Vectis

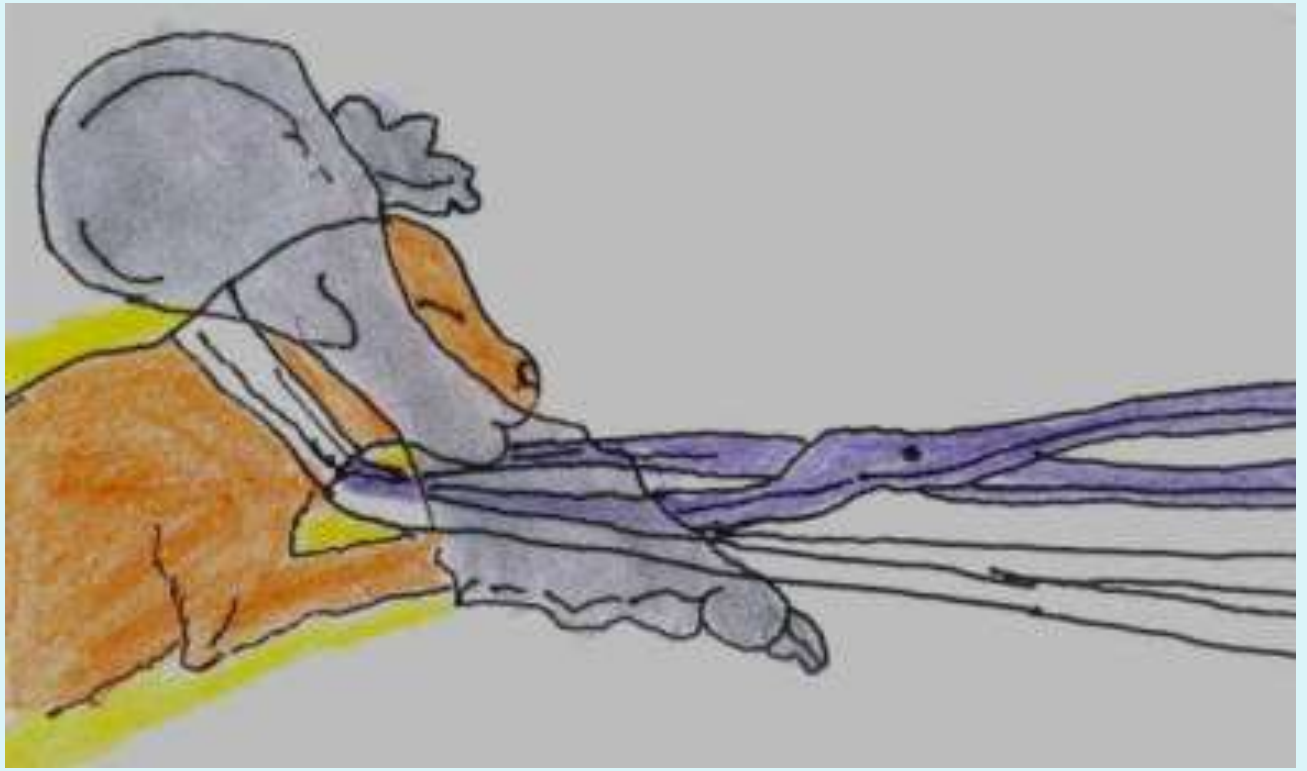

Snare and forceps

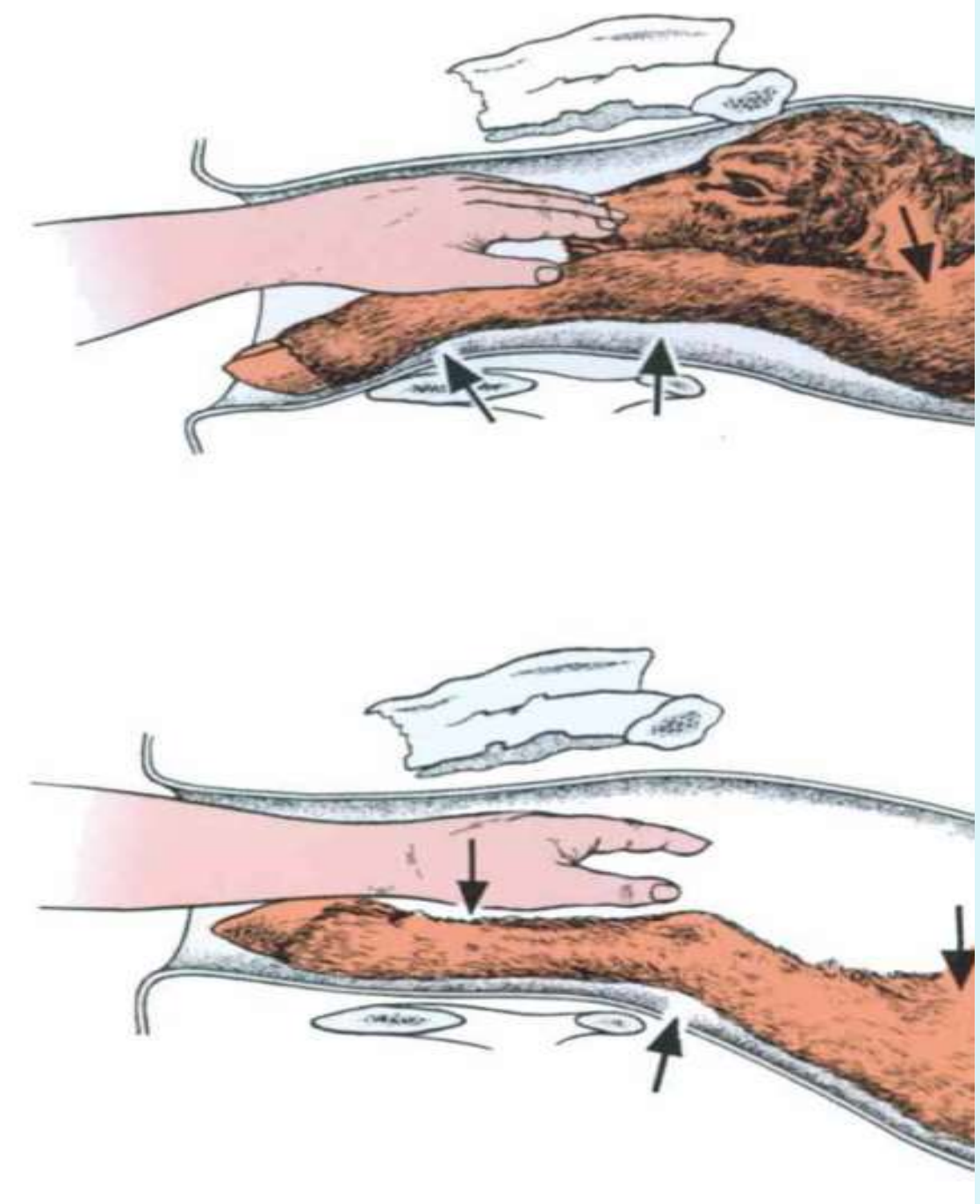

Identifying the fore and hind limbs by joints and direction of hoof

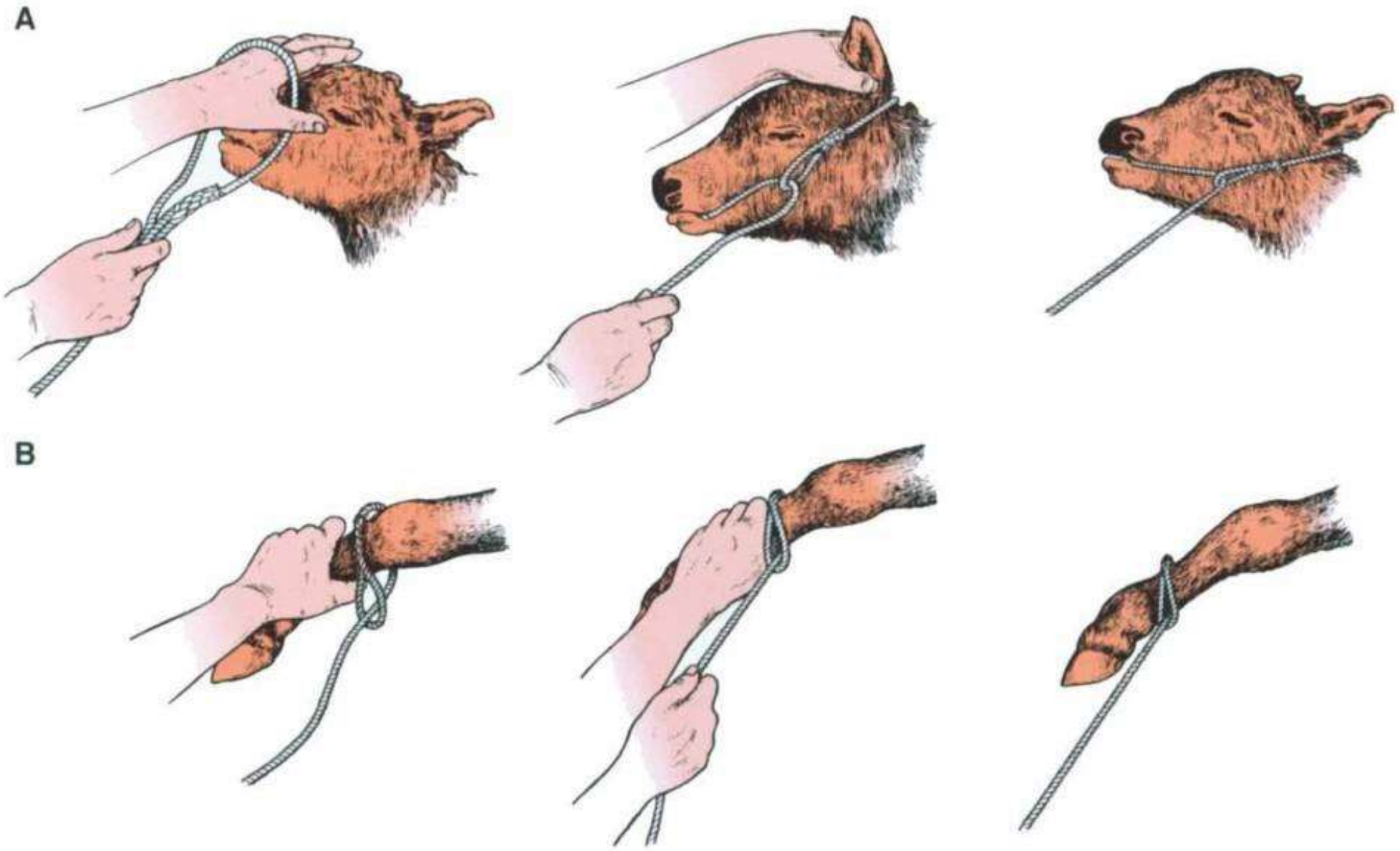

Application of calving ropes. (A) to the head, (B) to the leg.

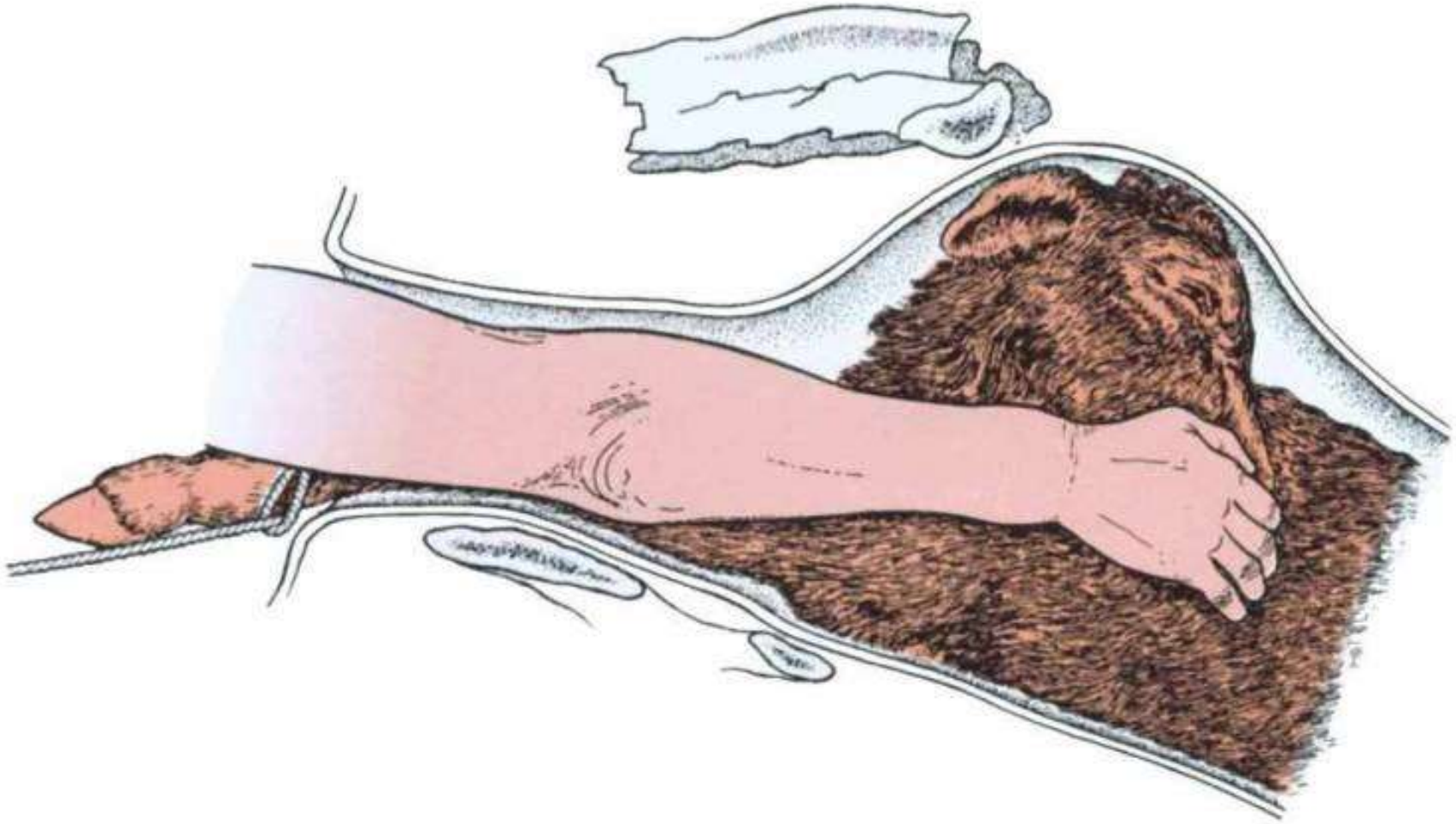

Correction of fetal malposture – lateral deviation of the head.

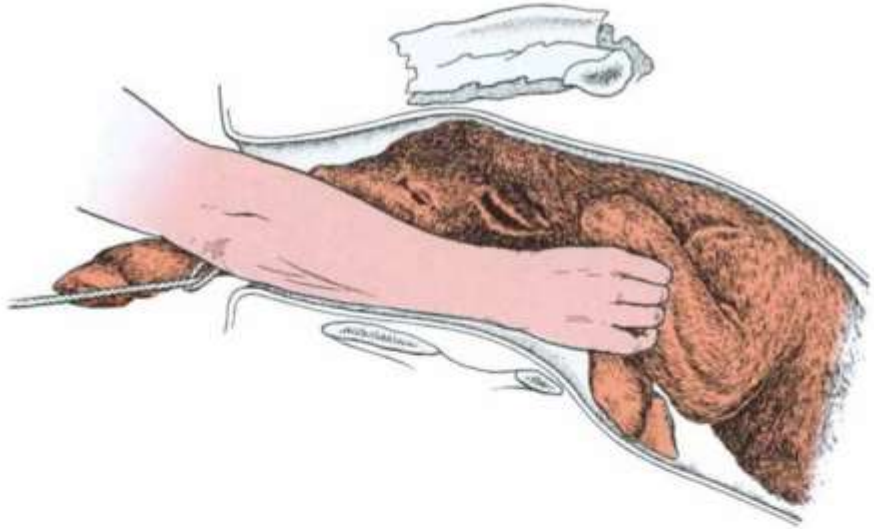

Correction of fetal malposture – carpal flexion (stage 1); see the text.

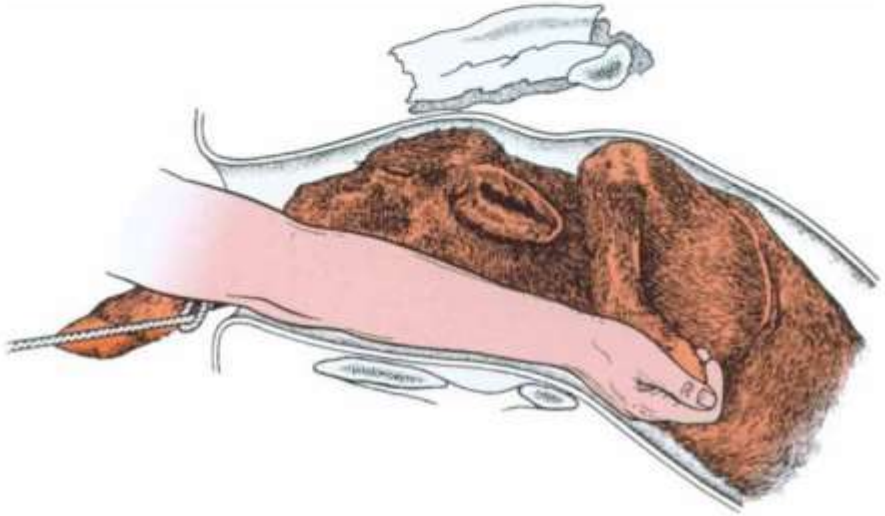

Correction of fetal malposture – carpal flexion (stage 2).

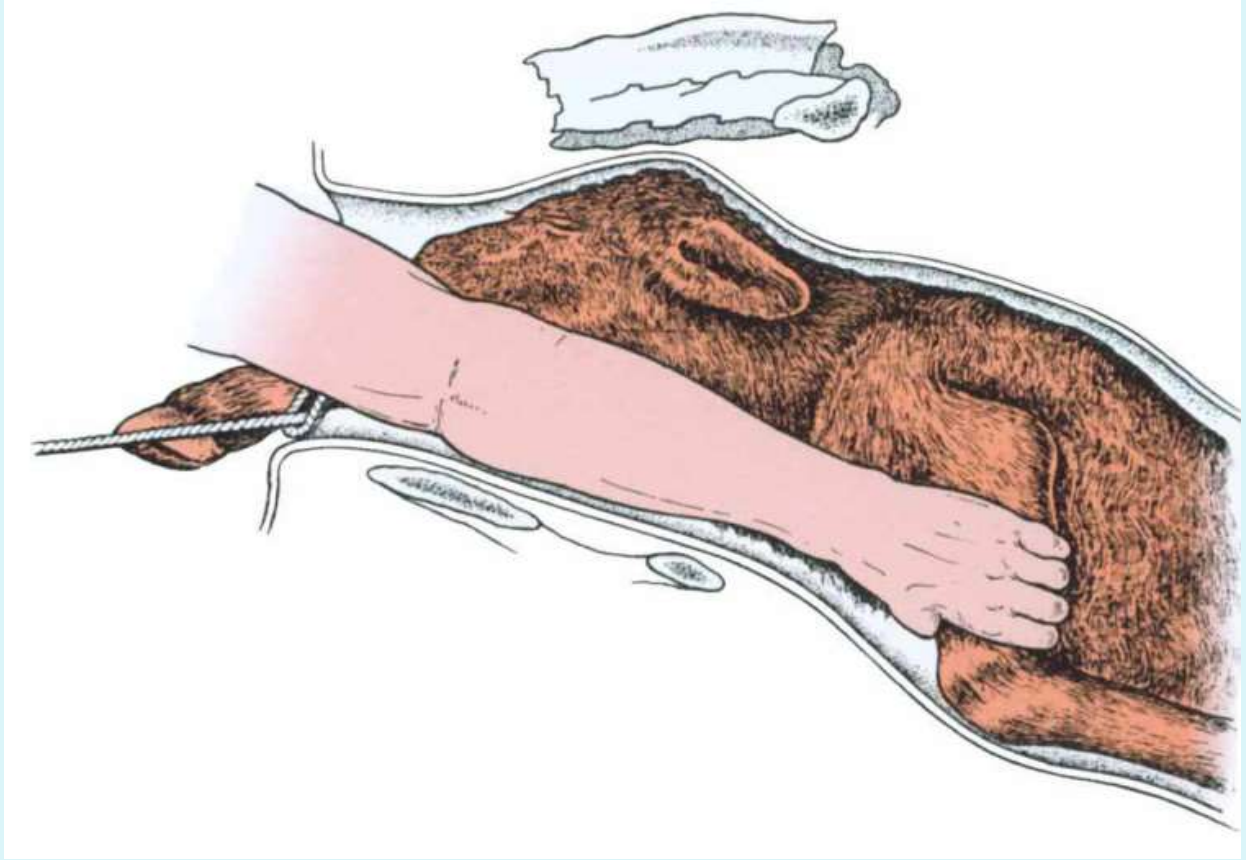

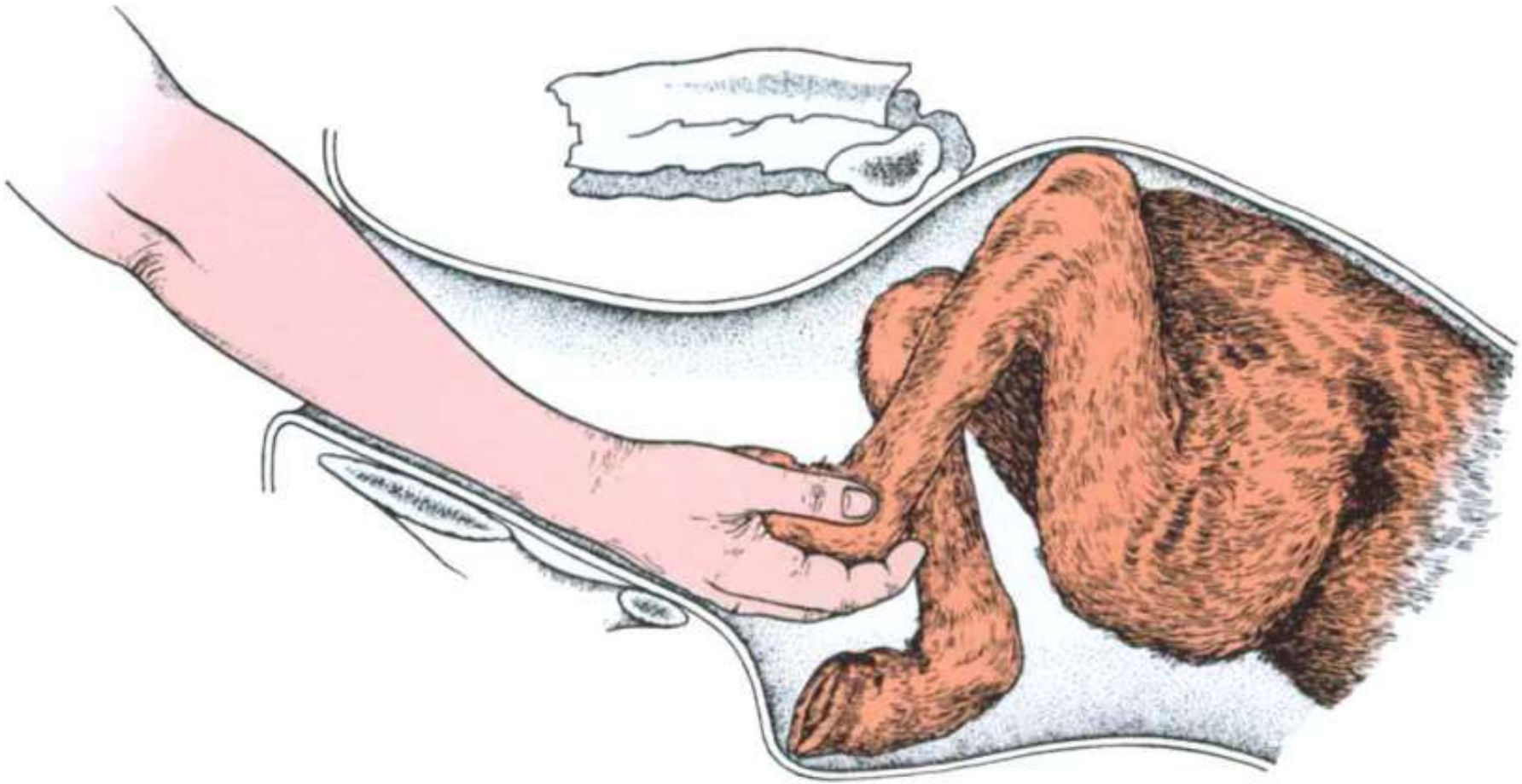

- **Fetotomy:** is defined as those operations performed on the fetus for the purpose of reducing its size by either division or removal of certain of its parts for its vaginal delivery. Fetotomy can be either partial (only some of the portions removed) or total (complete fetus divided into many parts). A fetotomy can be performed under the following circumstances to save the life of the dam:
- The fetus is dead.
- The fetus is emphysematous, which decreases the survival rate after a C-section.
- The fetus is too big to be delivered or the dam's pelvis is too narrow (i.e., feto-maternal disproportion/size mismatch).
- The fetus has an abnormality that will not allow it to be delivered (such as schistosomus reflexus]; perosomus horridus; or perosomus elumbis]).
- The fetus and the dam are in a hip-lock that cannot be corrected by fetal rotation.
- In all cases, there must be sufficient space to perform the cuts.

Advantages of fetotomy:

1. It reduces the size of the fetus
2. It avoids traumatic surgical procedures
3. It requires less of assistance
4. It prevents trauma to the birth canal by use of excessive traction
5. It creates space in the birth canal for correction of a fetal maldisposition
6. It maintains future fertility of the animal when carefully performed

Disadvantages of fetotomy

1. It may create injuries to the birth canal when performed carelessly.
2. It may take a longer time and is sometimes exhausting
3. It predisposes the obstetrician to infections of the arm when the
   fetus is emphysematous.
4. Cervical adhesions are almost inevitable in the mare after prolonged Intervention

Techniques of fetotomy

Fetotomies are of two types

Percutaneous and **Subcutaneous**

Percutaneous fetotomy.

This is done using specialized instruments known as fetatomes (Thygesons, Utrecht fetatome) which are double barrel instruments

A wire saw is threaded and applied to the part to be cut and the other free ends of the wire are tied in wire saw holders and by sawing action the part is cut.

Due care should be taken to avoid the tissues of the birth canal in the wire saw.

The skin and the part (for ex: limb) to be cut are separated by the sawing action of the wire saw and the part is removed.

If sufficient space has been created in the birth canal the maldisposition of the fetus is corrected and the fetus delivered.

The birth canal should be well lubricated. Limb removal, head removal (decapitation), head and neck removal (cephalotomy), removal of the thorax (detruncation) and pelvic bisection can be done with the careful use of fetatomes in cattle.

The maximum number of cuts suggested for fetotomy are six.

Types of fetatomes



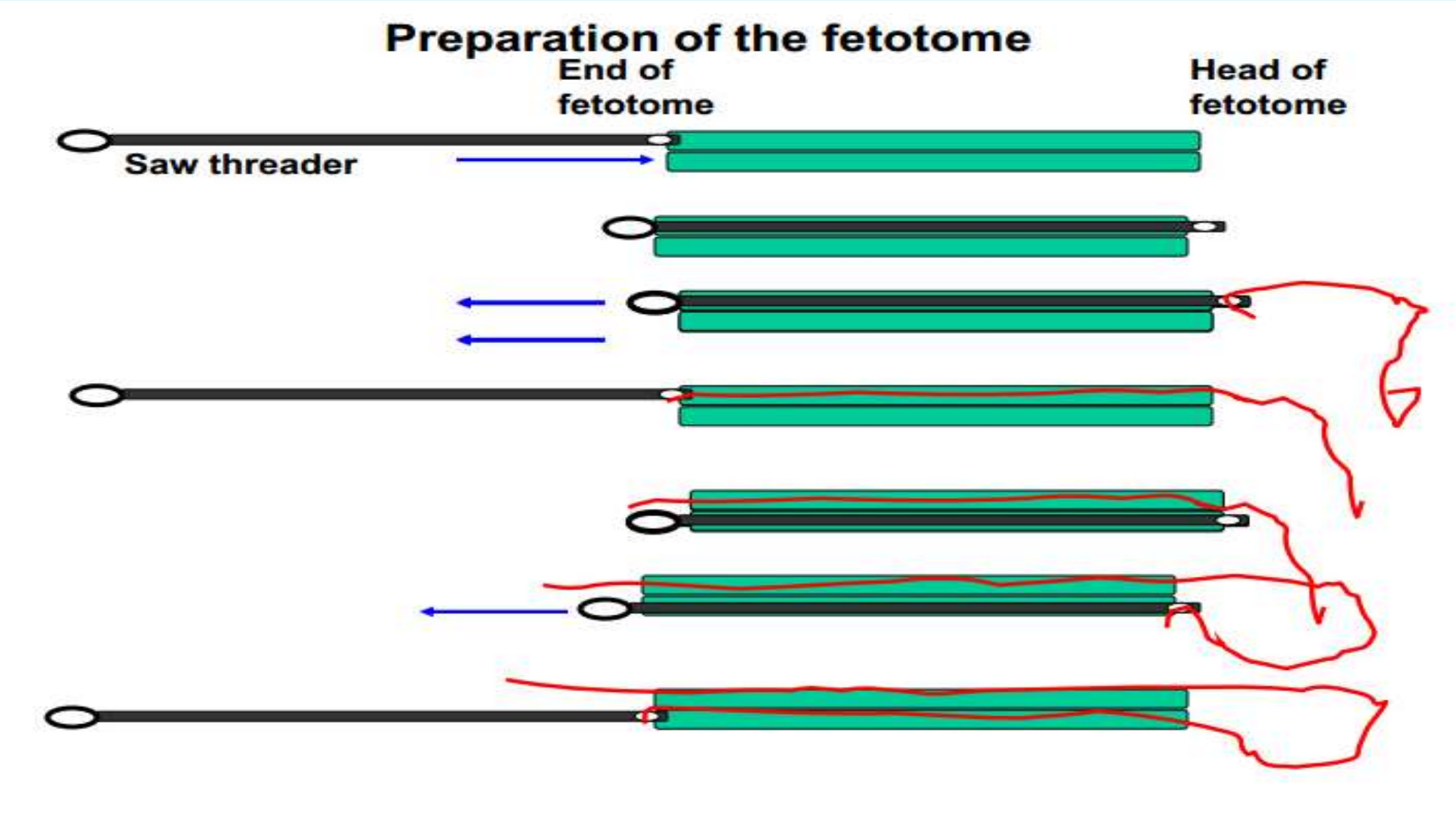
Preparation of the fetotome
End of fetotome
Head of fetotome
Saw threader

Decapitation, Detruncation

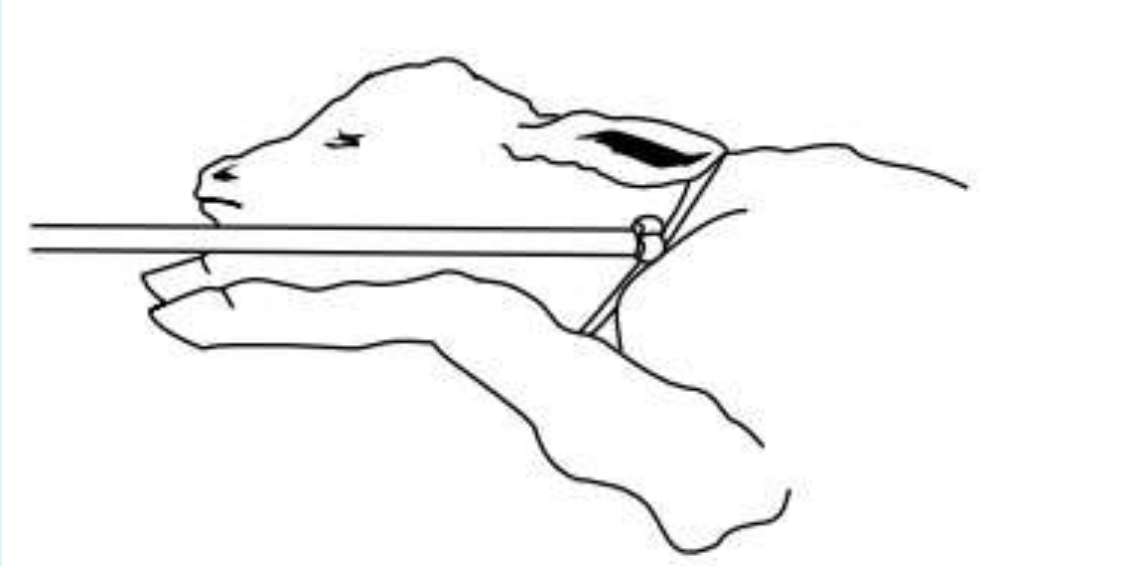

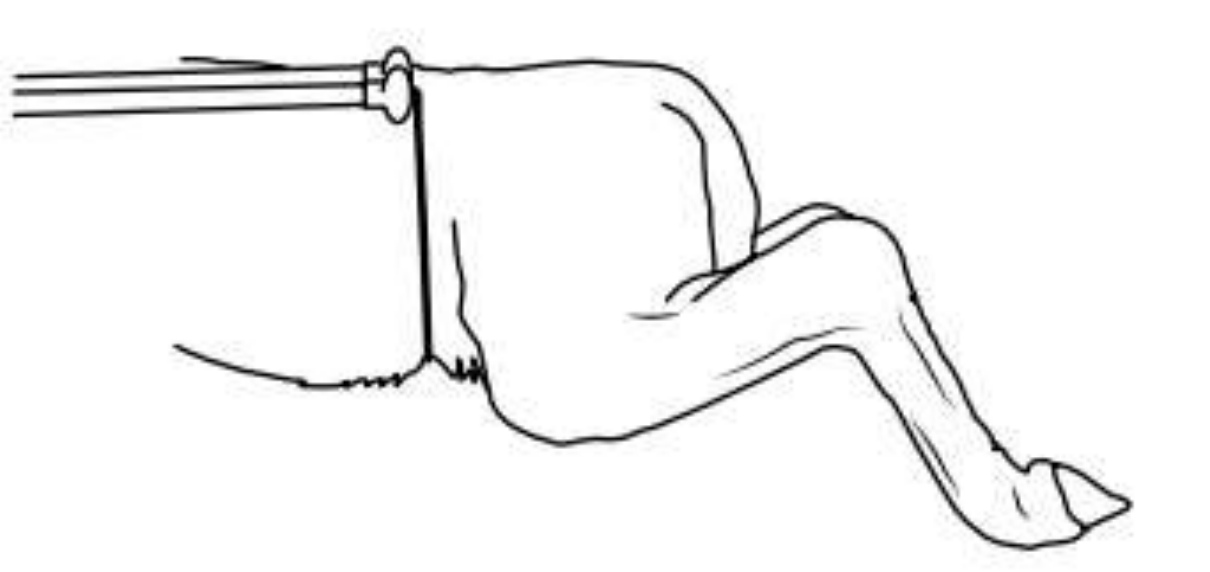

Pelvic bisection

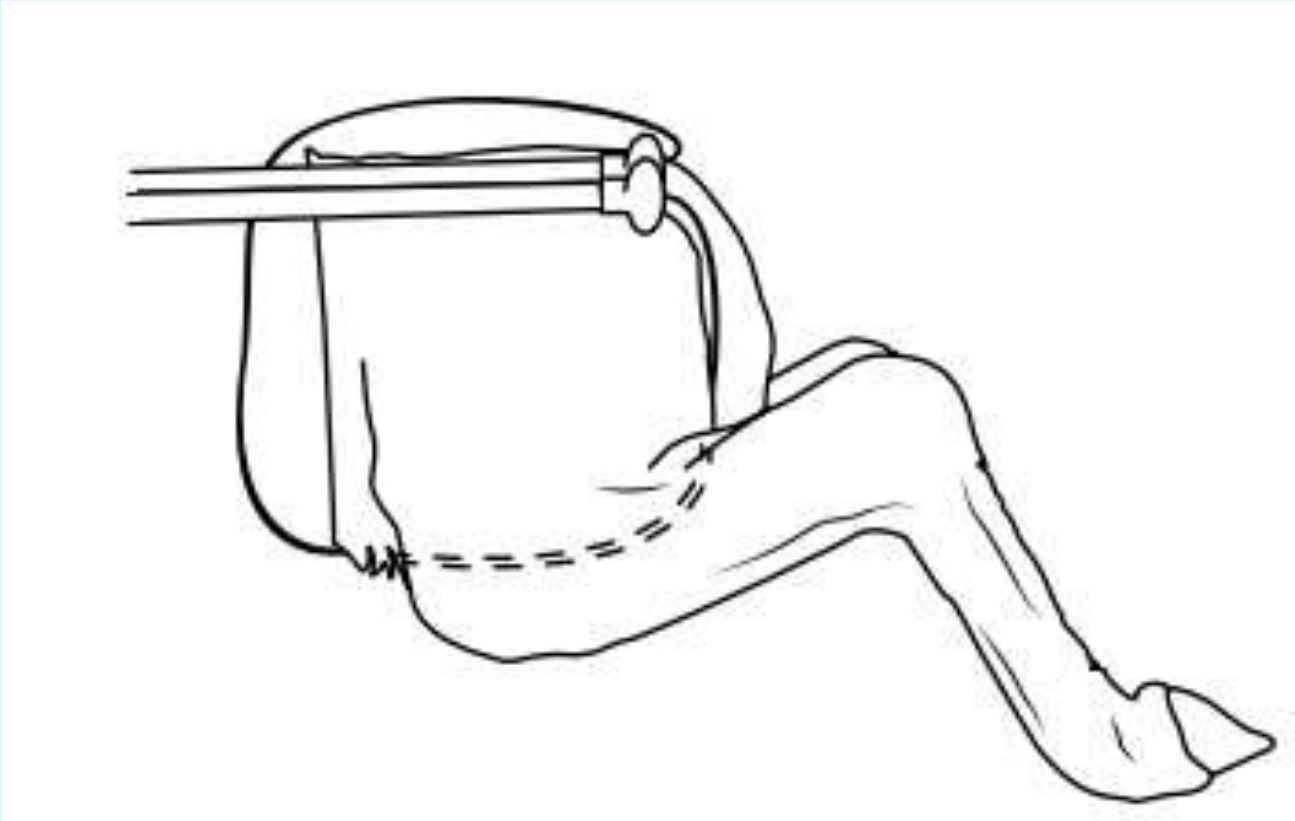

- Subcutaneous fetotomy: This involves the cutting of certain fetal parts (usually the limbs) without the removal of the skin.
- It is usually used in emphysematous fetuses using different types of knives. The skin is incised from the scapular point to metacarpal bone in anterior presentation and from hip joint to metatarsal bone in posterior presentation.
- The skin is then separated from the muscles and other attachments by the operators fingers and or blunt instruments.
- The pectoral muscles or the muscles around the scapula are broken and traction is applied on the limb.
- The limb breaks off and is removed.
- Care should be taken to avoid injury to the birth canal.
- The advantage of subcutaneous fetotomy is that all operations are done under the skin of the dead fetus thus avoiding injury to the birth canal and the skin left can also serve as a point of traction.
- Also subcutaneous fetotomy can be done without specialized instruments.

Fetotomy Knives (Linde and Guenther Pattern)

Subcutaneous fetotomy

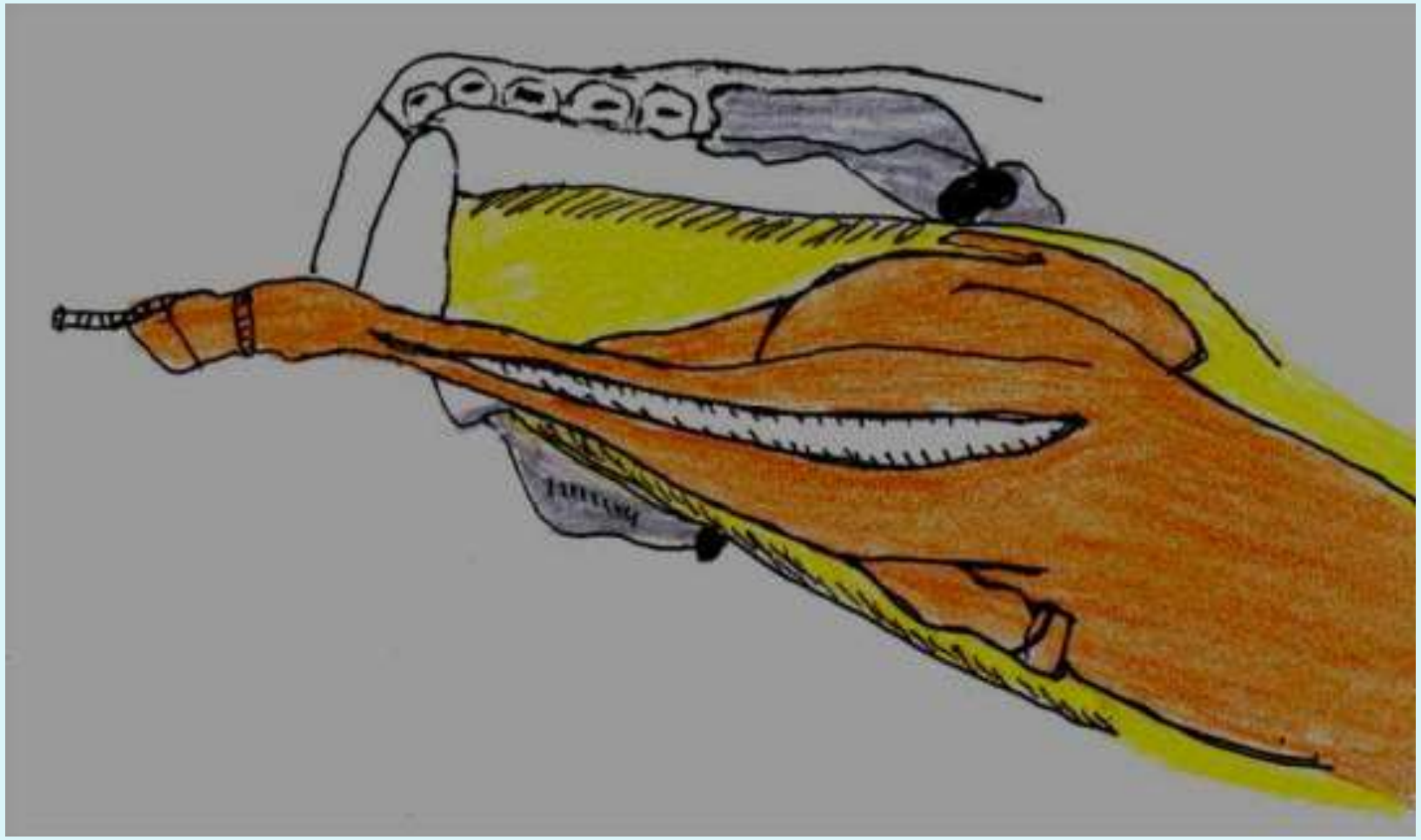

Fetotomy Equipment

1. Utrecht model fetotome
2. Wire threader
3. Wire saw handles
4. Wire introducer
5. Krey hook
6. OB chains
7. Lubricant
8. Epidural equipment

Fetotomy



Methods of dystocia handling in the mare have been recently divided into assisted vaginal delivery, controlled vaginal delivery, fetotomy and cesarean section.

In assisted vaginal delivery, the mare is aware and assisted to a small or large degree for vaginal delivery of an intact foal within 10-15 minutes. If resolution takes longer than 10-15 minutes, the obstetrician should consider the alternatives for correction of the dystocia. For assisted vaginal delivery the following points must be kept in mind:

Assist when the mare is lying down. If mare is foaling in standing position, the foals umbilical cord may rupture prematurely resulting in tissue hypoxia. However, for repositioning of the foal, the mare must be standing.

Once the thorax of fetus is delivered traction should stop.

Never apply traction on a fetus with fetal maldisposition.

Pull fetus in a downward arc, one leg at a time to reduce the width of shoulders.

Controlled Vaginal Delivery:

Controlled vaginal delivery employs general anaesthesia and hoisting the mare's hindquarters upwards. The uterine relaxation and effects of gravity assist in fetal repulsion and manipulation.

The position and posture of the fetus is determined, and the fetus is then repelled and repositioned to allow vaginal delivery.

Manipulations must be gentle and plenty of lubrication must be used to help delivery.

When the head and distal forelimbs come out in the birth canal, the mare should be lowered into lateral recumbency and traction must be applied to the foal until delivery. The umbilical cord must be clamped and cut. The mare must be placed on a thick mat for recovery.

If the foal cannot be delivered within 15 minutes a fetotomy (if the foal is dead) or caesarean section (if foal is live) should be performed. Moreover, the option to perform a fetotomy may be limited if manipulations before presentation of the mare have already inflicted severe trauma.

Controlled Vaginal Delivery

Fetotomy is dangerous in the mare

- Tranquilizers with epidural anesthesia is suggested
- Maximum cuts permissible are 1 or 2

Fetotomy in sheep and goats

- Only partial fetotomy of one or both limbs or the head is possible in sheep and goats with dead fetuses in the birth canal and should be performed carefully as the birth canal is very fragile and may tear easily.

Thank You

Kindly share the video and subscribe to my You tube channel **Govind Narayan Purohit** if you like them