

Studies on
Host-Parasite Relationship of
Ascaridia galli (Schrunk, 1788)
In Fowl And Pigeon

Thesis

Submitted to Rajendra Agricultural University
in partial fulfilment of requirements for
the degree of Master of Veterinary Science
(Parasitology)
August, 1978

*Department of Veterinary Parasitology
Bihar Veterinary College
Patna*

Shailja Kant Mishra

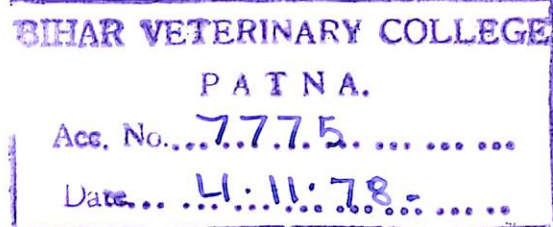
PS

338

Studies on
Host-Parasite Relationship of
Ascaridia galli (Schränk, 1788)
In Fowl And Pigeon

Thesis

Submitted to Rajendra Agricultural University
in partial fulfilment of requirements for
the degree of Master of Veterinary Science
(Parasitology)
August, 1978



*Department of Veterinary Parasitology
Bihar Veterinary College
Patna*

Shailja Kant Mishra

Dr. B.N.Sahai, M.V.Sc., Ph.D., GAESS (Giessen, W. Germ.),
University Professor and Head,

Department of Veterinary Parasitology,
Rajendra Agricultural University, Bihar,
Bihar Veterinary College,
Patna - 800014.

August 5, 1978

Certified that the thesis captioned
"Studies on host-parasite relationship of
Ascaridia galli (Schrunk, 1788) in fowl and
pigeon" is a bonafide work of Dr. Shailja
Kant Mishra under my supervision and guidance
for the award of the degree of Master of
Veterinary Science (Parasitology) of Rajendra
Agricultural University, Pusa, Samastipur.

Shailja Kant Mishra
6/10/78


(B. N. SAHAI)

The work embodied in this thesis has been carried out in the Department of Veterinary Parasitology, Bihar Veterinary College, Patna and certified that the research work incorporated in this thesis have not been published in part or in full in any other journal.

S. K. Mishra
5/8/78

(S. K. MISHRA)

CONTENTS

1. Introduction	1	1	1
2. Objectives of the study	2	2	2
3. Materials and Methods	3	3	3
4. Results and Discussion	4	4	4
5. Conclusion	5	5	5
6. References	6	6	6
7. Appendix	7	7	7
8. Bibliography	8	8	8
9. Glossary	9	9	9
10. Index	10	10	10
11. Summary	11	11	11
12. Acknowledgements	12	12	12
13. Certificate of Appreciation	13	13	13
14. Declaration	14	14	14
15. Certificate of Originality	15	15	15
16. Certificate of Acceptance	16	16	16
17. Certificate of Completion	17	17	17
18. Certificate of Award	18	18	18
19. Certificate of Distinction	19	19	19
20. Certificate of Merit	20	20	20
21. Certificate of Honors	21	21	21
22. Certificate of Fellowship	22	22	22
23. Certificate of Membership	23	23	23
24. Certificate of Associate Membership	24	24	24
25. Certificate of Life Membership	25	25	25
26. Certificate of Corresponding Membership	26	26	26
27. Certificate of Honorary Membership	27	27	27
28. Certificate of Emeritus Membership	28	28	28
29. Certificate of Distinguished Service	29	29	29
30. Certificate of Distinguished Achievement	30	30	30
31. Certificate of Distinguished Contribution	31	31	31
32. Certificate of Distinguished Leadership	32	32	32
33. Certificate of Distinguished Service to the Profession	33	33	33
34. Certificate of Distinguished Service to the Community	34	34	34
35. Certificate of Distinguished Service to the Nation	35	35	35
36. Certificate of Distinguished Service to the World	36	36	36
37. Certificate of Distinguished Service to Humanity	37	37	37
38. Certificate of Distinguished Service to the Universe	38	38	38
39. Certificate of Distinguished Service to the Cosmos	39	39	39
40. Certificate of Distinguished Service to the Galaxy	40	40	40
41. Certificate of Distinguished Service to the Universe	41	41	41
42. Certificate of Distinguished Service to the Cosmos	42	42	42
43. Certificate of Distinguished Service to the Galaxy	43	43	43
44. Certificate of Distinguished Service to the Universe	44	44	44
45. Certificate of Distinguished Service to the Cosmos	45	45	45
46. Certificate of Distinguished Service to the Galaxy	46	46	46
47. Certificate of Distinguished Service to the Universe	47	47	47
48. Certificate of Distinguished Service to the Cosmos	48	48	48
49. Certificate of Distinguished Service to the Galaxy	49	49	49
50. Certificate of Distinguished Service to the Universe	50	50	50

CONTENTS

			<u>PAGE</u>
Acknowledgements.
Introduction.	1

PART - I

Incidence and Intensity of Ascaridia galli in fowls, pigeons and ducks.

(i) Review of literature.	3
(ii) Materials and Methods.	4
(iii) Results.	5
(iv) Discussion.	8
(v) Summary.	9

PART - II

Host-Specificity of Ascaridia galli in fowls and pigeons.

(i) Review of literature.	10
(ii) Material and Methods.	11
(iii) Observations.	14
(iv) Discussion.	16
(v) Summary.	17

PART - III

Histopathological studies of the intestine of fowls infected with Ascaridia galli.

(i) Review of literature.	18
(ii) Material and Methods.	20
(iii) Observations.	21
(iv) Discussion.	22
(v) Summary.	24
(vi) Explanation of Figures.

PART - IV

Histochemical studies of the intestine
of fowl infected with Ascaridia galli.

(i) Review of literature.	25
(ii) Material and Methods.	30
(iii) Observations.	30
(iv) Discussion.	39
(v) Summary.	43
(vi) Explanation of Figures.

PART - V

Anthelmintic efficacy of
Helatac, Banninth and Wopell
against immature Ascaridia
galli in fowl.

(i) Review of literature.	44
(ii) Material and Methods.	47
(iii) Results.	48
(iv) Discussion.	51
(v) Summary.	52
General Summary and Conclusion.	53
References.	1

*

The investigation was carried out under the supervision and guidance of Dr. B.N.Sahai, M.V.Sc., Ph.D., F.H.S.I., G.A.E.S.S. (Giessen, W. Germany), M.N.A.Sc., M.I.S.P., University Professor and Head, Department of Veterinary Parasitology, Rajendra Agricultural University, Bihar. I wish to express my indebtedness to him for his guidance, keen interest and help in the preparation of the manuscript and also for keeping his personal collection of literature at my disposal.

It is my pleasant duty to express my gratitude to Dr. Y. Prasad, Animal Husbandry Commissioner-cum-Special Secretary, Ministry of Agriculture, Government of India, New Delhi and the then Director, Animal Husbandry, Bihar; to Dr. D.P.Singh, Vice Chancellor, Rajendra Agricultural University, Bihar, Pusa, Samastipur, for according permission to undertake the present study as in-service student; to Dr. R.N.Singh, Principal, Bihar Veterinary College, Patna, for providing necessary facilities; to Dr. L.N.Mandal, Regional Joint Director, Animal Husbandry, Central Range, Patna and to Dr. P. Lakra, Regional Joint Director, Animal Husbandry, Chotanagpur Range, Ranchi for encouragement.

I feel pleasure to record my sincere gratitude to Dr. G. Prasad, M.Sc. (Vet.), F.R.V.A.U. (Denmark), S.R.O. (Anatomy) and to

Dr. G.J.Jha, M.V.Sc., Ph.D. (AIIMS), Assistant Professor (Path.) for their generous help in interpretations of histochemical and histopathological preparations and to Dr. S.P.Singh, M.Sc., Ph.D., Assistant Professor (Parasit.) for his help in day to day work.

Thanks are also due to Dr. C.D.N.Singh, M.Sc. (Vet.), F.R.V.C.S. (Sweden), Professor of Pathology, Bihar Veterinary College, Patna; to Dr. M.N.Sahay, M.Sc. (Vet.), Junior Assistant Research Officer (Parasit.); to Dr. B.K.Sinha, M.V.Sc., Assistant Lecturer (Path.) for their co-operation and help. Assistance of Sri Ram Janam Singh, Technician, Department of Pathology is also acknowledged.

Lastly but not least the author is grateful to his colleagues and friends for their encouragement and time to time help.

I fail in my duty if I do not acknowledge my wife Mrs. Meena Mishra; without whose active co-operation, it would have been impossible to complete the work.

INTRODUCTION

The importance of poultry for raising the nutritional standard of the people of the world is well known. To meet the requirements of meat eating population tremendous emphasis is being laid on the development of poultry husbandry. Therefore, intensive development programme is being taken up in the State to raise healthy birds. For this purpose various methods to rear chickens are the open-pan system and the deep-litter system. The latter is often employed for the poultry development under the poultry intensification programme. However, the widely practised deep-litter system provides ideal conditions for various parasitic diseases specially nematodiasis. This poses a serious threat for the proper development of poultry industry.

Among the nematodes the most common and injurious parasite is Ascaridia galli (Schrunk, 1788) Freeborn, 1923 - a large intestinal roundworm of poultry, giving rise to a disease known as ascaridiasis, which undermine insidiously the health of birds. Gupta and Rao (1959) estimated 20 per cent mortality among growing chickens and lowering of egg production and also stunted growth to a varying degree among layers due to A. galli infection. In India 50 per cent losses in poultry industry is caused by A. galli alone

The importance of poultry for raising the nutritional standard of the people of the world is well known. To meet the requirements of meat eating population tremendous emphasis is being laid on the development of poultry husbandry. Therefore, intensive development programme is being taken up in the State to raise healthy birds. For this purpose various methods to rear chickens are the open-pan system and the deep-litter system. The latter is often employed for the poultry development under the poultry intensification programme. However, the widely practised deep-litter system provides ideal conditions for various parasitic diseases specially nematodiasis. This poses a serious threat for the proper development of poultry industry.

Among the nematodes the most common and injurious parasite is Ascaridia galli (Schrunk, 1788) Freeborn, 1923 - a large intestinal roundworm of poultry, giving rise to a disease known as ascaridiasis, which undermine insidiously the health of birds. Gupta and Rao (1959) estimated 20 per cent mortality among growing chickens and lowering of egg production and also stunted growth to a varying degree among layers due to A. galli infection. In India 50 per cent losses in poultry industry is caused by A. galli alone

(Rai, 1972). The host-range of this parasite is wide and infects fowls, guinea fowls, turkeys, geese and various other birds and cosmopolitan in distribution. The infection is clinically characterised, by symptoms of sluggishness, loss of appetite, ruffled feathers, drooping wings, loss of blood and body weight and also retarded muscle and bone development.

In view of the importance of A. galli, researches on the various aspects of the parasite and parasitic infections were carried out in the Department of Veterinary Parasitology, Rajendra Agricultural University, Bihar Veterinary College, Patna. The results of these investigations incorporated in the thesis have been presented in five parts - (i) Incidence and intensity of A. galli in fowls, pigeons and ducks; (ii) Host-specificity of A. galli in fowls and pigeons; (iii) Histopathological studies of the intestine of fowl infected with A. galli; (iv) Histochemical studies of the intestine of fowl infected with A. galli and (v) Anthelmintic efficacy of Helatac, Banminth and Wopell against A. galli infection in fowl.

PART - I

INCIDENCE AND INTENSITY OF ASCARIDIA GALLI IN FOWLS, PIGEONS AND DUCKS .

Several (1958) studied the incidence of *Ascaridia galli* in fowls of 20-25 weeks and found 50 per cent of fowls infected with *A. galli*. Choudhary (1962) found *A. galli* infection in fowls 10-15 per cent and 20-25 per cent in 21/2 and 2 1/2 years respectively. (1965) reported 41.4 per cent fowls infected with *A. galli*. Ghosh (1967) reported 10 to 25.2 per cent. Ghosh and Ghosh (1973) reported 27 per cent infection in fowls and 23.3 per cent in pigeons and ducks.

During the investigation on the various aspects of A. galli, it was thought necessary to find out the exact incidence and intensity of this nematode in fowls, pigeons and ducks in and around Patna, as it is said to be the commonest nematode of poultry and other birds.

REVIEW OF LITERATURE

Ascaridia galli is the commonest nematode parasite of the poultry and has been reported by several workers (Srivastava, 1939; Mudaliar and Alwar, 1947; Dutt, 1950; Dixit, 1951; Lahiri, 1951; Gupta and Rao, 1959; Srivastava and Malaviya, 1959; Mukhopadhyay, 1962; Deo, 1964; Kaushik, 1965; Chand, 1967; Srivastava, 1968; Katara, 1971 and Kumar and Sahai, 1975 etc.).

Qureshi (1950) studied the incidence of helminths in fowls of Uttar Pradesh and found 50 per cent of deshi fowls infected with A. galli. Mukhopadhyay (1962) found A. galli infection in deshi fowls 70.73 per cent where as in RIR and WLH- 47.61 per cent. Kaushik (1965) reported 41.4 per cent fowls infected with A. galli. Chand (1967) observed it to be 59.2 per cent. Kumar and Sahai (1975) noticed 80 per cent infection in deshi fowls and 33.3 per cent in W.L.H. and R.I.R. birds.

MATERIAL AND METHODS

SOURCE AND COLLECTION.

To study the incidence and intensity of A. galli infection, birds were obtained from different locality of Patna and Central Poultry Farm, Patna and examined for the presence of the nematode. The intestine was taken out and opened by a longitudinal incision and gut-lumen was thoroughly searched for the presence of worms. A. galli was collected in normal saline in petridishes.

FIXATION AND PRESERVATION.

Nematodes were fixed in 10% hot formalin and 70% steaming alcohol. After couple of hours these parasites were transferred to fresh 10% formalin for preservation.

CLEANING FOR MICROSCOPICAL EXAMINATION.

Preserved nematodes were cleared for microscopical examination in lacto-phenol, which was prepared as suggested by Taylor (cited by Sahai, 1960).

Carbolic acid	-	50 ml.
Lactic acid	-	50 ml.
Glycerine	-	100 ml.
Distilled water	-	50 ml.

RESULTS

In the examination of 1,415 fowls, 46 pigeons and 32 ducks, for the prevalence of A. galli only 1,113 fowls (78.6%) were found to be positive. The results are summarised in Tables 1 and 2.

TABLE - 1

INCIDENCE AND INTENSITY OF A. GALLI INFECTION

IN FOWLS IN AND AROUND PATNA.

POSITIVE BIRDS - 78.6%

AVERAGE WORM BURDEN - 4.2%

Period	No. of birds examined.	No. of birds positive.	Percentage of infection.	Calculated chi/square value.	Total No. of worms recovered	Average worm load per bird
1	2	3	4	5	6	7
November'75	95	65	68.5	125.70**	330	5.1
December'75	102	66	64.7		380	5.7
January'76	92	61	66.3		219	3.5
February'76	121	82	67.8		279	3.4
March'76	125	89	71.2		592	6.6
April'76	154	119	77.3		454	3.8
May'76	98	80	81.6		236	2.9
June'76	58	55	94.8		159	2.8
July'76	85	83	97.6		168	2.0
August'76	93	91	96.8		430	4.7
September'76	82	79	96.3		230	2.9
October'76	109	102	93.6		449	4.4
November'76	97	69	71.1		332	4.8
December'76	104	72	69.2		389	5.4
	1415	1113			4648	

** Significant at 1% level.

PREVALENCE OF A. GALLI IN PIGEONS AND DUCKS.

TABLE - 2

Period	Pigeons			Ducks		
	Total	Post-	Examine-	Total	Post-	Examine-
		live.	live.		live.	live.
		Percent-	Percent-		Percent-	Percent-

November, '75	3	0	0	2	0	0
December, '75	3	0	0	2	0	0
January, '76	3	0	0	3	0	0
February, '76	3	0	0	4	0	0
March, '76	2	0	0	2	0	0
April, '76	3	0	0	2	0	0
May, '76	2	0	0	3	0	0
June, '76	3	0	0	2	0	0
July, '76	3	0	0	1	0	0
August, '76	2	0	0	2	0	0
September, '76	4	0	0	3	0	0
October, '76	5	0	0	2	0	0
November, '76	4	0	0	1	0	0
December, '76	6	0	0	2	0	0
	46	0	0	32	0	0

It was noticed that the incidence of A. galli was nil in pigeons and ducks examined, but in domestic fowls it was 78.6 per cent. Incidence was highest during July (97.6%) and lowest in December-January (64.7 - 69.2%).

DISCUSSION

In India, A. galli is by far the most important and common helminth parasite of fowls, and heavy infections cause considerable mortality in chickens (Mohan, 1954) and the poultry industry suffers a great set back due to this infection. Gupta and Rao (1959) estimated 20 per cent mortality among growing chickens and Rai (1972) opined that 50 per cent loss in poultry industry due to this worm.

The statistical data available in Egypt showed that in the 16 million fowls, A. galli alone consumes 90 tons of usual carbohydrate annually (Reid, 1953). Although no such data is available in India, it is obvious from the ravages perpetrated that this parasite is one of the greatest set backs to the economy of poultry industry in this country (Deo, 1964).

In the present investigation, 78.6 per cent domestic fowls were found to harbour this parasite. Dutt (1950) studied the incidence of worms in fowls dying at the Indian Veterinary Research Institute, Izatnagar during June, 1948 to March, 1949 and reported 56 per cent A. galli infection. Mukhopadhyay (1962) reported A. galli in 70.7 per cent deshi fowls and 47.6 per cent white leg-horns and Rhode Island Red fowls, whereas Kausik (1965) reported 41.4 per cent, Chand (1967) 59.2 per cent and Kumar and Sahai (1975) 80.0 per cent in deshi fowls and 33.3 per cent in WLH and RIR birds.

It has been observed that intensity was lowest (2.0%) in July when incidence was highest (97.6%) and intensity was highest (6.6%) in March when incidence was comparatively low (71.2%). Dutt (1950) in an out-break of helminthic infection in birds, observed intensity of A. galli from 1 to 119 per bird.

SUMMARY

Out of 1,415 domestic fowls examined post-mortem, the prevalence rate of A. galli in the present investigation was noticed to be 78.6 per cent in deshi birds, whereas 46 pigeons and 32 ducks examined were found to be negative for A. galli infection.

PART - II

HOST SPECIFICITY OF ASCARIDIA GALLI

IN FOWLS AND PIGEONS.

Experiments were conducted to infect pigeons and fowls by A. galli recovered from naturally infected fowls to study if cross infection could be established.

REVIEW OF LITERATURE

As no work is available on the host-specificity of A. galli in fowls and pigeons, literatures on cross transmission of certain helminth parasites have been reviewed.

The only reference available on specificity of A. galli for hens, turkeys and ducks, by Klimes and Stejskal (1968). They infected chicks, turkey poults and ducklings by 500 infective larvae directly into the crop of each bird separately from fowl and turkey-strains. On post-mortem examination chickens were found to be more heavily infected and in greater number than turkey poults and ducklings with fowl-strain of A. galli. Similarly, turkey poults had heavy infection and in greater number than other birds with turkey-strain of A. galli. Again, they observed that larvae derived from A. dissimilis isolated from turkeys proved non-infective to chickens.

Srivastava and Dutt (1961) carried out transmission experiments of Schistosoma nasale. They could establish the parasites of buffalo origin in cattle and vice-versa. Again, Dutt and Srivastava (1968) confirmed that there was no strain difference between the blood fluke (S. nasale) in cattle and buffaloes.

Sahai and Deo (1966) made cross transmission experiments of Haemonchus species and observed that sheep and goat strains of the parasite are not host-specific. But cow-calves and buff-calves did not take up the normal infection either from goat or sheep strains.

Sinha and Sahai (1976) experimentally infected pups, separately, with human and canine strains of hookworms. Pups infected with hookworm of human-strains started passing eggs in the faeces 5 weeks post-infection, whereas those infected with canine-strains discharged eggs in the faeces after 3 weeks.

MATERIAL AND METHODS

THE PARASITE.

The strains of A. galli required for experimental infection were collected from intestine of naturally infected fowls,

the post-mortem of which were performed.

CULTURE OF EGGS.

The worms were kept in tap water in clean petridishes and some times in normal saline for oviposition. Uterine ova were also collected from some of the gravid females by teasing out their uterus. For subsequent development their ova were left in clean petridishes containing tap water with few drops of 2 per cent formalin, 2-3 mm deep, to provide the access of sufficient oxygen. The eggs, in the infective stage, were concentrated by sedimentation process and used for subsequent experimental infections.

During the winter season the eggs were kept in the incubator at 86° F for embryonation, because the atmospheric temperature was not found to be conducive for the proper development of eggs.

EXPERIMENTAL BIRDS.

In all 12, two week-old chickens of white leghorn and 12, two week-old pigeons were procured from Central Poultry Farm, Patna and from contractor respectively. These birds were divided into four groups. Groups-I and II had 6 chickens each and Groups III

and IV had 6 pigeons each and were kept in four separate cages, which had been properly sterilised to ensure rearing of disease and worm free chickens and pigeons.

These birds were maintained in laboratory on a mash with following composition:-

Maize	-	40%
Ground nut cake	-	32%
Rice polish	-	10%
Molasses	-	5%
Fish meal	-	10%
Mineral Mixture	-	3%

To the above mixture Rovimix @ 25 gm/quintal was added. In order to protect the chickens against coccidiosis, Neftin 50 @ 100 gm/quintal and 3 Nitro @ 100 gms/quintal were also added.

EXPERIMENTAL INFECTION.

Care was taken to avoid other infections before the chickens and pigeons were infected experimentally with counted numbers of infective eggs. Chickens were infected with 2000-3000 infective eggs whereas pigeons with 1500-3000 infective eggs. The

infected chickens were sacrificed 10 days to 68 days and pigeons 35 to 95 days post-infection to find out the percentage of worms established.

OBSERVATIONS

To determine the host-specificity of fowl strain of A. galli, 6 chicks (Group-I) and 6 pigeons (Group-III) were infected with infective eggs and 6 chicks (Group-II) and 6 pigeons (Group-IV) were maintained as non-infected controls. Detailed results are summarised in Table-3.

As no natural infection of A. galli was found in pigeons, the reverse transmission experiments could not be done.

TABLE - 3

HOST-SPECIFICITY OF ASCARIDIA GALLI IN FOWLS AND PIGEONS
Route of infection - per os.

Group	Experi- mental birds	Dose of infect- ion(No. of infe- ctive eggs)	Strain	Date of infect- tion.	Date of autopsy	Duration from in- fection to auto- psy. (in days)	No. of worms recov- ered.	Per- centage of in- fection
1	2	3	4	5	6	7	8	9
I								
(Infected)	Fowl-1	2000	Fowl	30.4.76	10.5.76	10	87	4.4
	Fowl-2	3000	Fowl	30.4.76	15.5.76	15	255	8.5
	Fowl-3	2800	Fowl	30.4.76	18.5.76	18	31	1.1
	Fowl-4	2000	Fowl	30.4.76	18.6.76	49	55	2.8
	Fowl-5	2500	Fowl	30.4.76	7.7.76	63	100	4.0
	Fowl-6	2500	Fowl	30.4.76	8.7.76	69	115	4.6
II								
(Control)	Fowl-7	-	-	-	10.7.76	-	0	-
	Fowl-8	-	-	-	10.7.76	-	0	-
	Fowl-9	-	-	-	10.7.76	-	0	-
	Fowl-10	-	-	-	10.7.76	-	0	-
	Fowl-11	-	-	-	10.7.76	-	0	-
	Fowl-12	-	-	-	10.7.76	-	0	-
III								
(Infected)	Pigeon-1	1500	Fowl	21.4.76	26.7.76	96	0	0
	Pigeon-2	1800	Fowl	21.4.76	26.7.76	96	0	0
	Pigeon-3	2000	Fowl	24.4.76	29.5.76	35	23	1.2
	Pigeon-4	2500	Fowl	24.4.76	26.7.76	93	0	0
	Pigeon-5	3000	Fowl	18.5.76	26.7.76	69	0	0
	Pigeon-6	3000	Fowl	18.5.76	26.7.76	69	0	0
IV								
(Control)	Pigeon-7	-	-	-	27.7.76	-	0	-
	Pigeon-8	-	-	-	27.7.76	-	0	-
	Pigeon-9	-	-	-	27.7.76	-	0	-
	Pigeon-10	-	-	-	27.7.76	-	0	-
	Pigeon-11	-	-	-	27.7.76	-	0	-
	Pigeon-12	-	-	-	27.7.76	-	0	-

It is evident from the table-3 that 1.1 to 8.5 per cent worms of A. galli developed in fowls but did not develop in pigeons except in one case (1.2%). Control fowls and pigeons remained uninfected throughout the experimental studies.

DISCUSSION

In the present investigation, it was observed that fowl-strains of A. galli developed 1.1 - 8.5 per cent in fowls but did not develop in pigeons except in one case (1.2%). It appears that pigeons picked up the infection but could not retain for a longer period as evident from the table-3. Pigeons-3 was sacrificed 35 days post-infection revealed 1.2 per cent infection of A. galli but other pigeons of group-III were autopsied between 69-96 days were found to be negative. The experiment suggested that pigeons are not natural host of A. galli, which has also been supported by absence of natural infection in 46 pigeons examined. Similar results have been reported by Klimes and Stejskal (1968) on host-specificity of A. galli for hen, turkey and duck.

SUMMARY

Results summarised shows that fowl strains developed in chicks (1.1 to 8.5%) but not in pigeons except in one case (1.2%).

PART - III

**HISTOPATHOLOGICAL STUDIES OF THE INTESTINE
OF FOWLS INFECTED WITH ASCARIDIA GALLI**

Infection by the nematode, A. galli is widespread in poultry and other birds in many parts of the world resulting in a variety of pathological lesions. Information on the pathological alterations due to this important nematode has no unanimity. The present study aimed to find out histopathological changes in the intestine of fowl infected with mature and immature A. galli.

REVIEW OF LITERATURE

Guberlet (1924) observed that the birds infected with A. galli developed inflammation of intestine and in heavy infection died within 12 days due to intestinal irritation. Ackert and Herrick (1928) observed symptoms of sluggishness, loss of appetite, ruffled feathers, drooping wings, loss of blood and body weight, retarded muscular and bone development, formation of urates in the ureters and increased mortality among birds affected with Ascaridia.

Sadun (1950) studied the pathogenicity in chickens of single dose infection with A. galli of variable size and recorded that the infected birds developed atrophy of the thymus, splenomegaly and hepatomegaly and those with heavy infection showed damage to the intestine, kidney, mild anaemia and severe leucocytosis after 10 days.

Tsvetaeva (1954) studied the pathology of early stages of ascaridiasis in chickens and described histological changes occurring after five days of infection. Kadziolka (1956) studied the pathology of experimental infection in chickens with this nematode and reported vascular changes in the region of duodenum and jejunum. Again, in 1960, Kadziolka carried out histopathological studies in experimental ascaridiasis in chicken and described macroscopic and microscopic changes in the wall of the intestine.

Nath and Pande (1963) studied the lesions associated with A. galli, Heterakis gallinae, Subulura minetti and Acuraria hamulosa and some hitherto unknown features of their behaviour as pathogens were discussed. Singh (1964) opined that A. galli undermines the health and body weight of the chicken specially during 9th to 17th day post-infection. The immature larvae penetrate between the intestinal villi at the expense of Brunner's glands. Congestion, haemorrhage and marked infiltration of inflammatory cells were important features and also damage to the spleen, kidney and liver occurred.

Kaushik (1965) reported that chief pathological changes associated with A. galli infection in chicks are catarrhal enteritis,

and he did not observe perforation of the intestinal wall and formation of nodules. Khouri and Pande (1970), described erosion of the duodenal lining, haemorrhage and copious mucoid exudate associated with experimental ascaridiasis.

Ikeme (1971) attributed most severe pathological changes in chickens infected with A. galli when maintained on least nutritious diet. Intestinal obstruction was also noticed due to large number of adult worms, but cellular infiltration was rare due to ascaridiasis. Contrary to this, Pavlicek and Dykova (1975) observed marked changes in the intestinal mucosae and eosinophil infiltration of the intestine and liver parenchyma in chickens infected with A. galli.

MATERIAL AND METHODS

For histopathological studies, portions of small intestine of naturally infected fowls having heavy infection of A. galli were selected. Also portions of the intestine of birds experimentally infected with A. galli were collected to study the pathological changes due to immature/juveniles of the worms. The tissues were fixed and preserved in 10% formalin. Conventional methods of fixation, dehydration, clearing, paraffin embedding, section cutting

and staining with haematoxylin and eosin were used (Sahai and Srivastava, 1971). The mounting medium used was D.P.X.

OBSERVATIONS

HISTOPATHOLOGY OF INTESTINE INFECTED WITH ADULT WORMS:

In the histological sections of the small intestine, the cut sections of the parasites were seen lying in the lumen of the gut. There was severe degree of sloughing of intestinal epithelium and height of the villi was exaggerated at some places (Figs. 1, 2). There was also heavy infiltration of mononuclear cells comprising of macrophages, lymphocytes and a few histiocytes in the lamina propria (Fig.3). The crypt cells were unaffected but submucosa showed proliferation of a few fibroblasts. The muscularis proper and serosa were not involved in the sections.

HISTOPATHOLOGY OF INTESTINE INFECTED WITH JUVENILES:

Histological examination of the small intestine showed a good amount of desquamation and degeneration of epithelial cells in the lumen. The normal architectural pattern of intestine was maintained. However, sloughing off the mucosa was prominent. The

cut section of the larvae of A. galli was seen lying either between the two villi or penetrating an individual villus (Fig.4). The epithelial cell lining the villi showed rounding off and some of them acquired the typical character of macrophage. The substantia propria in general was infiltrated by lymphocytes and macrophages (Fig.5). However, this cellular infiltration was much more pronounced around the larvae of the parasite. In addition the goblet cells appeared to have increased in number. Other parts of the intestine did not reveal any significant tissue alteration.

DISCUSSION

In the present study, sloughing of intestinal epithelium, exaggerated increase in height of villi, infiltration of mononuclear cells (viz. macrophages, lymphocytes and few histiocytes) in lamina propria and also proliferation of fibroblasts in submucosa in naturally infected A. galli infection were the main pathological lesions.

In case of immature worms desquamation and degeneration of the epithelial cells of the intestinal lumen with sloughing of the mucosa was seen. The larvae were found between the villi or penetrating the villus and infiltration of substantia propria by

lymphocytes and macrophages was also observed.

Roberts (1937) described patches of inflammatory reaction on the surface of mucus membranes, with accumulation of histiocytes and some polymorph neutrophils. Kadziolka (1960) also stated that hyperplasia of lymph nodules and extensive eosinophilia were constant phenomenon, indicating cellular reaction against infection. It is rather hard to reconcile the findings of Roberts (1937) and Kadziolka (1960) with the results of the present study and that of Sadun (1950). Ikeme (1971) also did not observe eosinophilic infiltration. Pavlicek and Dykova (1975) observed eosinophilic infiltration in the intestine though not extensive.

During the present study, the only signs of infiltration observed in respect of adult worms were macrophages, lymphocytes and a few histiocytes and proliferation of a few fibroblasts in submucosa and in juveniles lymphocytes and macrophages mostly around the larvae. This is quite in agreement with those of Ikeme (1971) who also observed infiltration in respect of dead worms which degenerate and became surrounded by fibroblasts and Roberts (1937) also noticed histiocytes. Contrary to the present finding, Singh (1964) showed marked infiltration of cells.

Nath and Pande (1963) remarked that larval forms of A. galli penetrate deep into the gut wall right upto the serosal coat and adult worms could penetrate deep enough to cause peritonitis. During the present investigation no such pathological alterations were noticed and so it agrees with those of Kaushik (1965).

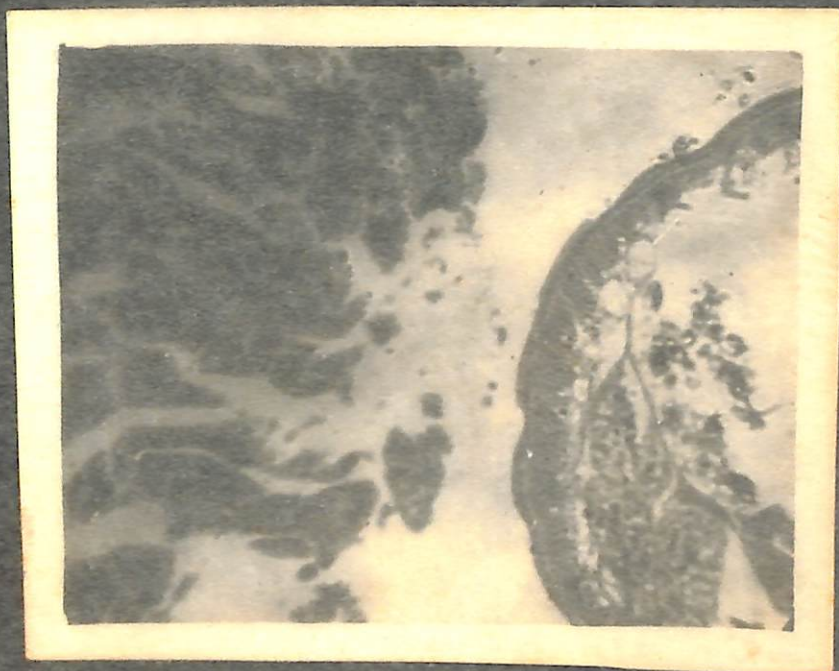

Khourl and Pande (1970) reported that main histopathological changes associated with the infection comprise erosion of the epithelial lining, haemorrhage and copious discharge of mucus exudate. Singh (1964) also observed congestion and haemorrhage. Although the present study did not show sign of any haemorrhage, but showed sloughing of the epithelial cells as also observed by Khourl and Pande (1970).

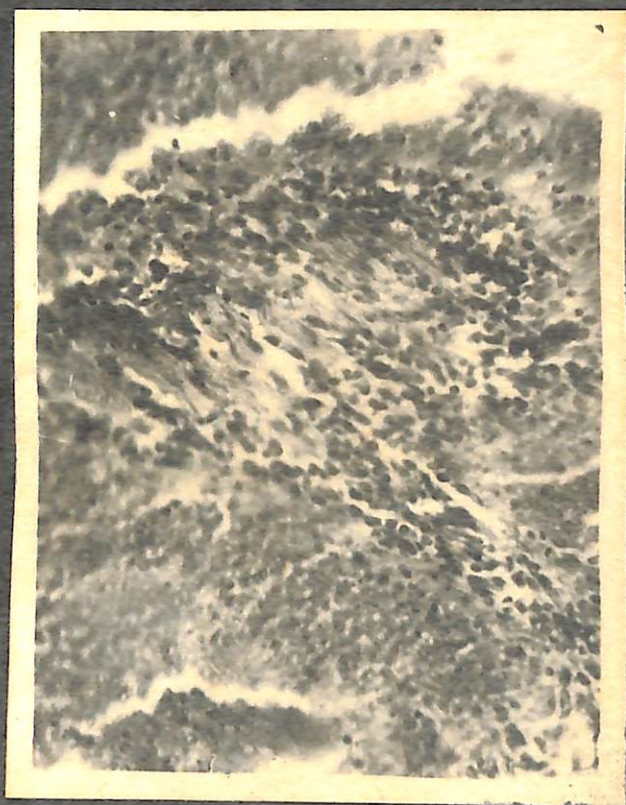The enteritis in the present infection was also in agreement with Singh (1964) and Khourl and Pande (1970).

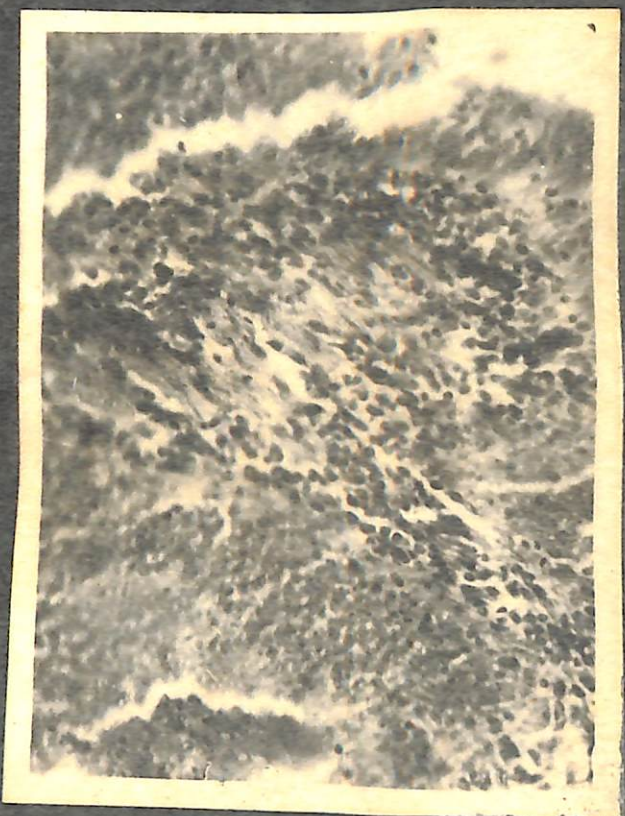SUMMARY

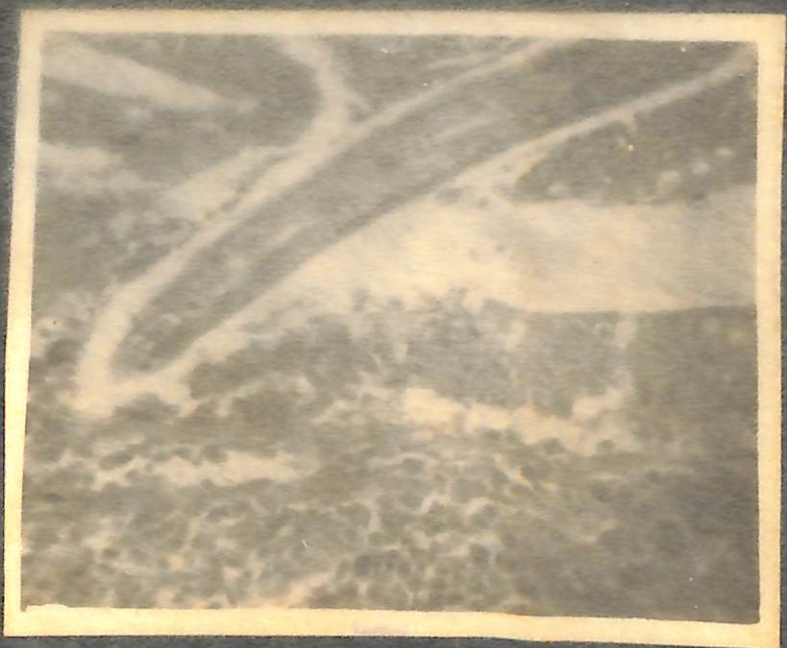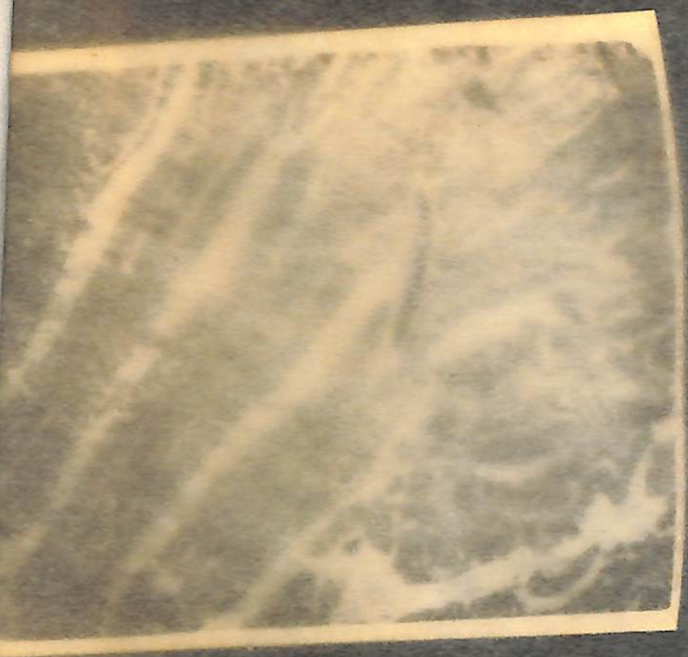The histopathological studies of intestine of fowls infected with adult and juveniles of A. galli, revealed proliferation of ductal epithelium and other inflammatory changes - suggestive of enteritis.

EXPLANATION OF FIGURES









Lowry (1958) published a comprehensive survey on the
mechanism of penetration of helminth larvae through host tissues.
It is a primary parasite in the life cycle of the helminth
parasite. In the host, the penetration is mainly aided by
an enzyme in the secretory vesicle which forms the intestine
after entry, the secretory vesicle contains the proteolytic
enzymes of the host. The literature on the mechanism of tissue
penetration and histological changes in the tissue on account
of penetration is rather scanty. The present investigation,

PART - IV

HISTOCHEMICAL STUDIES OF THE INTESTINE OF FOWLS INFECTED WITH ASCARIDIA GALLI

REVIEW OF LITERATURE

As far as work is available on histochemical studies
in ascaridiosis, the literature on histochemical studies of other
helminth parasites also have been reviewed.

Lowry and Lee (1954) observed alterations in glycogen,
lipids and phospholipids in rat's liver infected
with *Ascaris lumbricoides*. Lowry and Lee (1955) studied the

RAJENDRA AGRICULTURAL UNIVERSITY, RAIPUR, JHARKHAND

Lewert (1958) published a comprehensive review on the mechanism of penetration of helminth larvae through host tissue, which is a primary requisite in the life cycle of the helminth parasites. As per his views, the penetration is mainly based on an alteration in the glycoprotein barrier which forms the intercellular cement, the subepithelial basement membrane and the ground substance of the host. The literature on the mechanism of tissue penetration and histochemical alterations in the tissue on account of ascariidiasis is rather meagre. The present investigation, therefore, have been designed to study the histochemical alterations in small intestine of fowls, naturally and also experimentally infected with A. galli.

REVIEW OF LITERATURE

As not much work is available on histochemical studies in ascariidiasis, the literature on histochemical studies of other helminth parasites also have been reviewed.

Lewert and Lee (1954) observed alterations in glycogen, glycoprotein and phosphatase distribution in rat's liver infected with Taenia taeniaformis. Again, Lewert and Lee (1955) studied the

histochemistry of liver of rat infected with T. taeniaformis and observed depletion of glycogen around the larvae.

Hara (1956) observed the reduction of nucleic acids and glycogen in the liver infected with A. caninum in experimental ancylostomiasis. Lewert and Lee (1956) observed an extensive alteration of the protein carbohydrate complex of a cellular elements of the dermal connective tissue and possessed a collagenase like enzyme or enzyme complex with proteolytic properties, during the penetration of cercaria of Schistosoma mansoni and filariform larvae of Strongyloides ratti. Swada, Hara, Takagi, Nagazawa and Oka (1956) observed an increase in glycogen and lipid contents, a decrease in ribonucleic acid in the cytoplasm of the hepatic cells and excessive accumulation of acid mucopolysaccharide in the schistosomal granulomata in the liver of mouse infected with S. japonicum.

Munnich (1960) studied detailed histochemical changes of the liver, lungs and intestine of albino mice infected with Ascaris lumbricoides and reported a marked decrease in glycogen, fat, ribonucleic acid and amino acids of liver and an increase in glycoprotein in the area of inflammation.

histochemistry of liver of rat infected with T. taeniaformis and observed depletion of glycogen around the larvae.

Hara (1956) observed the reduction of nucleic acids and glycogen in the liver infected with A. caninum in experimental ancylostomiasis. Lewert and Lee (1956) observed an extensive alteration of the protein carbohydrate complex of a cellular elements of the dermal connective tissue and possessed a collagenase like enzyme or enzyme complex with proteolytic properties, during the penetration of cercaria of Schistosoma mansoni and filariform larvae of Strongyloides ratti. Svada, Hara, Takagi, Nagazawa and Oka (1956) observed an increase in glycogen and lipid contents, a decrease in ribonucleic acid in the cytoplasm of the hepatic cells and excessive accumulation of acid mucopolysaccharide in the schistosomal granulomata in the liver of mouse infected with S. japonicum.

Munnich (1960) studied detailed histochemical changes of the liver, lungs and intestine of albino mice infected with Ascaris lumbricoides and reported a marked decrease in glycogen, fat, ribonucleic acid and amino acids of liver and an increase in glycoprotein in the area of inflammation.

Dhar and Singh (1963) reported complete depletion of glycogen, increased lipid contents and increased deposition of lipofuscin and haemosiderin pigments in the hepatic cells in microcoeliasis in cattle and sheep. Roneus (1963) demonstrated absence of glycogen in the hepatic cells on the liver of pigs following the Toxocara cati infection.

Srivastava and Singh (1964) have studied the changes in carbohydrate, protein, lipids, amyloid and calcium associated with infection of Oesophagostomum. Frandsen (1966) observed some histochemical changes in the connective tissue of the ileum of bovine, the site was surrounded by larval O. radiatum. The histochemical study revealed a real or apparent increase in the concentration of glycoproteins.

Chatterjee and Singh (1968) were first to study the histochemical alterations of the small intestine in ascaridiasis, which revealed an increase in mucopolysaccharides in the goblet cells. The parasitic tract also contained substances giving reactions for mucopolysaccharides. A decrease in the protein content of the infected tissue was described in both the early and advanced stages of the disease. The lipid content also increased to certain

extent in the infected tissue. Excessive alkaline phosphatase was observed in the damaged epithelium and also on the brush border of the villi. Pigmentation or deposition of calcium and occurrence of amyloidosis were not found in ascariasis.

Banerjee and Singh (1969) observed marked depletion of glycogen in the hepatic cells of rat in cysticercosis. Rubaj and Furnaga (1969) studied the histochemical changes in liver of sheep infected experimentally with Fasciola hepatica and observed a marked decrease in liver glycogen and an increase in cholesterol, 165 days post-infection, and returned to normal after 347 days post-infection.

Katara and Rai (1972) made observations on alkaline and acid phosphatase activity at different stages of development of A. galli in chicks and reported an increase in the activity of alkaline phosphatase. It was quite prominent along the tracts left by the parasite. The activity starts declining after maturity of the worm. The acid phosphatase activity remains unaltered.

Kumar, Sahai and Jha (1973; 1975) studied histochemistry of liver and pancreas in opisthorchiasis *novae* in dogs and reported marked depletion of glycogen and protein contents of the hepatic cells around the infected bile ducts. They also observed

increased mucin secretion by the lumina borders of the tubular glands and the lining epithelial cells. Ansari and Singh (1973), during their histochemical studies of liver in opisthorchiasis in dogs, reported similar alterations and also increase in lipid content, protein content, alkaline phosphatase and acid phosphatase but cytoplasmic ribonucleic acid content was reduced.

Parasd, Sahai and Jha (1974) did not observe any significant histochemical alterations in protein and glycogen contents of the duodenum of kids infected with Cotylphoron cotylphoron. Sahay, Sahai and Prasad (1977) also did not notice any significant histochemical changes in the lungs and hearts of guinea-pigs, mice, rabbits, kids and lambs experimentally infected with S. nasale, but their studies revealed marked depletion of PAS positive substance and protein and moderate increase of mucin in the sections of infected liver, Von kuppfers cells were distinctly positive for calcium deposits.

Sinha, Sahai and Prasad (1978) studied the histochemistry for PAS positivity, mucin, protein and calcium deposits of the liver, lungs and intestine of pups experimentally infected with hookworms.

MATERIAL AND METHODS

On autopsy pieces of small intestines of chickens naturally and experimentally infected with A. galli were collected alongwith their healthy counterparts. The tissues were fixed in 10% neutral buffered formalin and absolute alcohol. Standard techniques of dehydration, clearing, paraffin embedding, section cutting and staining were adopted as prescribed by Culling (1963) and Pearse (1968). The following staining procedures were employed:

- | | | |
|--------------|---|---|
| For Regular | - | Periodic Acid Schiff technique. |
| For Glycogen | - | Best carmine staining technique. |
| For Mucin | - | Muci-haematin staining technique. |
| For Calcium | - | Von-kossa's staining technique. |
| For Protein | - | Mercury Bromphenol blue staining technique. |

OBSERVATIONS

The results of histochemical changes of the intestine infected with mature and immature A. galli alongwith their normal counterparts are presented in table- 4.



A. Periodic Acid Schiff reaction for polysaccharide complex substances.

INFECTED TISSUE: The intestine of the fowl infected with adult A. galli, histologically revealed section of the worm in the lumen of the gut which gave strong PAS positivity (Fig.6). The goblet cells lining the villi of the tract gave an intense PAS positivity thereby indicating the presence of an increased polysaccharide complex substances. The other popular variety of the epithelium i.e. the columnar epithelial cells alongwith the brush border gave a varying degree of weak to moderate PAS positivity (Fig.7). The glands of Lieberkuhn also gave similar staining reactions (Fig.8). The connective tissue components as well as tunica media consisting of inner circular and outer longitudinal smooth muscle fibres also gave a moderate PAS positive reaction. A moderate to strong PAS positive reaction was noticeable in the tunica adventitia.

In the sections infected with juveniles, the goblet cells exhibited increase PAS positive substances. Increase of goblet cells were more marked at the site of parasitic infection (Fig.9). The simple columnar epithelium did not reveal any appreciable distinction between the infected and control sections (Fig.10). The brush border

of the columnar epithelial cells showed a moderate PAS positivity. In the centre of the lumen, the goblet cells of the distorted and de-attached portion of villi gave a strong PAS positive reaction, whereas the central contents of the lumen gave a varying degree of weak to moderate PAS positivity. The connective tissue fibres revealed a moderate PAS positivity whereas a weak PAS positive reaction was noticed in the submucosa. Similar staining reaction i.e. moderate to strong PAS positivity in the goblet cells of the glands of Lieberkuhn and weak to moderate PAS positivity in the columnar epithelial cells were discernible. The tunica media consisting of inner circular and outer longitudinal smooth muscles as well as tunica adventitia gave a weak PAS positive reaction.

CONTROL TISSUE: In control sections no appreciable histochemical staining difference was noticed (Figs. 11, 12).

B. Best carmine stain for Glycogen

INFECTED TISSUE: The sections of intestine infected with adult parasites revealed a negative reaction for Glycogen in the different tunics of the gut. But, the central portion of the section of the worm showed an intense positivity for the glycogen (Fig.13).

There was an increase in the glycogen contents of the goblet cells of sections infected with immature nematode, A. galli. The columnar epithelial cells alongwith brush border gave a weak to moderate reaction for the glycogen (Fig.14). In the connective tissue components, and the tunica media consisting of inner circular and an outer longitudinal smooth muscle layers gave a very weak positive reaction for glycogen (Figs. 15, 16). A negative reaction for the glycogen was observed in the tunica adventitia. The central portion of the intestinal lumen exhibited distorted and deattached portion of villi along with increased glycogen content of the goblet cells.

NORMAL TISSUE: In the control section the goblet cells lining the intestinal tracts were found studded with glycogen, whereas weak to moderate positivity for the glycogen were seen in the columnar epithelial cells and brush border. Similarly, a moderate positivity was discernible in the fibro-architecture and a weak to moderate positivity were observed in the smooth musculature (Fig.17).

C. Mucicarmum stain for mucin.

INFECTED TISSUE: In the small intestine section an intense positive reaction for the mucin was noticed in the goblet cells in mature worm

infestation. The columnar epithelial cells, brush border and the cells of the glands of the Lieberkuhn gave a weak positivity for the mucin, whereas other histological constituents of the gut wall gave negative reaction (Figs. 18, 19).

In immature infection the section of the small intestine revealed a moderate positivity for the mucin in the goblet cells. A very weak reaction was noticed in the columnar epithelial cells, brush border and the cells lining Lieberkuhn glands (Fig.20). Other histologic constituents of the tract, viz., lamina propria, muscularis mucosae, submucosa, tunica muscularis and adventitia, revealed negativ reaction.

CONTROL TISSUE: The goblet cells exhibited a moderate positivity whereas the columnar epithelial cells along with the apical brush border and cells of the glands of Lieberkuhn gave a weak positive reaction for the mucin. Other histologic tunics of the gut wall revealed a negative reaction.

D. Von-Kossa's stain for calcium deposits.

The sections of small intestine of fowls infected either with mature or immature *A. galli* as well as in control did not reveal any calcium deposits.

E. Mercury-Bromphenol Blue stain for protein.

INFECTED TISSUE: The section of the small intestine infected with mature parasite, the goblet cells lining the villi revealed a strong positive reaction for the protein (Fig.21). The columnar epithelial cells gave a moderate protein reaction whereas the brush border stained intensely thereby showing strong positive reaction. The basal cells lining the Lieberkuhn glands also exhibited a marked increase in the protein contents (Fig.22). A strong positive reaction was also noted in the muscularis mucosae. A moderate positivity in the tunica media consisting of inner circular and outer longitudinal smooth muscular layers, whereas strong positive reaction in the tunica adventitia were recognisable.

The section containing immature worms revealed a marked depletion of the protein content of the goblet cells (Fig.23). The columnar epithelial cells along with the brush border gave a weak positive reaction. The lamina propria and the submucosa revealed a moderate to strong positivity, whereas tunica muscularis consisting of inner circular and outer longitudinal smooth muscle layers along with fibro-architecture revealed a moderate positivity for proteins.

CONTROL TISSUE: In control section a strong positive reaction for the protein content in the goblet cells whereas a moderate positivity in the columnar epithelial cells and brush border were recorded. A strong positive reaction was also recorded in the tunica muscularis consisting of inner circular and outer longitudinal smooth muscle tunics. Other histologic constituents of the gut wall gave a variable staining reaction weak to moderate positivity.

TABLE - 4

TABLE SHOWING HISTOCHEMICAL CHANGES OBSERVED IN THE DIFFERENT HISTOLOGIC LAYERS OF THE SMALL INTESTINE OF THE FOWL INFECTED WITH A. GALLI.

	Mature parasitic infection					Immature parasitic infection				
	PAS positive polysaccharide complexes.	Glycogen	Mucin	Cal-cium	Protein	PAS positive polysaccharide complexes	Glycogen	Mucin	Cal-cium	Protein
1	2	3	4	5	6	7	8	9	10	11
1. Tunica intima										
a) Goblet cells	+++ (+++)	(++)	+++ (++)	(-)	+++ (+++)	+++	+++	++	-	-
b) Columnar epithelial cells along with apical brush border.	+ to ++ (+ to ++)	(+ to ++)	(+)	(-)	++ to +++ (++)	+ to ++	+ to ++	+	-	+
c) Glands of Lieberkühn.	++ to +++ (++ to +++)	(++ to +++)	(+)	(-)	+++ (+++)	++ to +++	+	++	-	+
d) Lamina Propria.	++ (++)	(++)	(-)	(-)	++ (+)	++	+	-	-	++
e) Muscularis mucosae.	++ (++)	(++)	(-)	(-)	+++ (++)	++	+	-	-	++

contd...

TABLE - 4 (CONTINUED)

1	Mature parasitic infection				Immature parasitic infection			
	PAS positive polysaccharide complexes.	Glycogen	Mucin	Cal-cium	Protein	PAS positive polysaccharide complexes.	Glycogen	Mucin Cal-cium
2	3	4	5	6	7	8	9	10
2. <u>Tunica submucosa</u>	++ (++)	- (++)	- (-)	- (-)	++ (+)	+	-	-
3. <u>Tunica muscularis</u>								
a) Inner Circular layer.	++ (++)	- (+ to ++)	- (-)	- (-)	++ (+++)	+	-	-
b) Outer longitudinal layer.	++ (++)	- (+ to ++)	- (-)	- (-)	++ (+++)	+	-	-
4. <u>Tunica adventitia</u>	++ to +++ (++ to +++)	- (-)	- (-)	- (-)	+++ (++)	+	-	-

(Symbols in the parenthesis indicate reactions in the control groups)

- = Negative reaction.
 + = Very weak positive reaction.
 ++ = Weak positive reaction.
 +++ = Moderate positive reaction.
 +++ = Strong positive reaction.

DISCUSSION

Polysaccharide complex: In the present study the intestinal sections either infected with mature or immature A. galli as well as uninfected control when stained with PAS for demonstration of carbohydrate and carbohydrate containing tissue elements did not reveal any significant alterations. Similar observations were also recorded by Chatterjee and Singh (1968) in the experimental ascaridiasis in chicks. The presence of PAS positive substances in the parasitic tract in the duodenal region was reported by Chatterjee and Singh (1968) are also in conformation with the present observations. Sinha, Sahai and Prasad (1978) also did not observe any distinction in the PAS positivity of the goblet cells of the small intestine of pups between infected and control in hookworm infestations.

Glycogen: A complete depletion of glycogen reserve in the section of the small intestine of fowls infected with mature A. galli was noticed, whereas a strong positivity for the presence of glycogen in the goblet cells, weak to moderate in columnar epithelial cells along with apical brush border in immature ascaridiasis and control sections were discernible. Prasad, Sahai and Jha (1974)

did not observe any significant changes in glycogen contents of the duodenum of goats infected with Cotylophoron cotylophorum.

A marked depletion of glycogen was noticed in hepatic cells of infected liver by Lewert and Lee (1955) and Banerjee and Singh (1969) in T. taeniaeformis infection in rats, by Kuwamura (1958) in early stages of experimental clonorchiasis in rabbit, by Mannich (1960) in ascariasis lumbricoides in mouse, by Dhar and Singh (1963) in microcoeliasis in cattle and goat, by Roneus (1963) in Toxocara cati infection in pig, by Rubaj and Fumaga (1969) in fascioliasis in sheep, by Kumar, Sahai and Jha (1973 & 1975) and Ansari and Singh (1973) in opisthorchiasis in dogs.

Numerous causes have been ascribed for this depletion in various parasitic infestations, but in the present investigation a large amount of glycogen was found to be present in the parenchyma of the adult parasite, which might have been derived from the host. The presence of glycogen in the section of small intestine infected with immature worms but completely depleted in case of mature worm is suggestive that during the development of the parasites require glycogen, which supports the contention that parasites feed on the sugars derived from the blood of the host. The actual

mechanism, however, by which the adult parasites obtain blood is not very clear.

Mucin: Increased production of mucin in mature worm infestation and very weak to moderate in immature parasitic infestation in the present study are in accordance with those of Chatterjee and Singh (1968) in ascariasis in chicks, of Srivastava and Singh (1964) in oesophagostomiasis in sheep, of Sinha, Sahai and Prasad (1978) in hookworm infection in pups. Similar observations have also been recorded in various other visceral organs in experimental clonorchiasis (Kuwamura, 1958), in microcoeliasis (Dhar and Singh, 1963), in opisthorchiasis (Kumar, Sahai and Jha, 1973 and 1975; Ansari and Singh, 1973), in nasal schistosomiasis (Sahay, Sahai and Prasad, 1977).

The mechanical irritation of the intestinal mucosa due to the habit of the parasite to penetrate the mucosa and chemical irritation due to metabolic and waste products of the worms may be responsible for excess mucin secretion. It is also in agreement with Florey (1954), who described the main function of mucus to dilute the irritant and evacuate it.

Calcium: Absence of calcium deposits in both juveniles and mature parasitic infection in the gut wall of the chickens reinforces the findings of Chatterjee and Singh (1968) in chick ascaridiasis. Contrary to this, Sinha, Sahai and Prasad (1978) observed depletion of calcium deposits in the small intestine of pups in hookworm infection. Similarly Dhar and Singh (1963) described depletion of calcium deposits in the liver of cattle and sheep in microcoeliasis, Kumar, Sahai and Jha (1975) in the liver of dogs in opisthorchiasis and Sahay, Sahai and Prasad (1977) in liver of mice, rabbit, guinea-pig, kid and lamb in nasal Schistosomiasis.

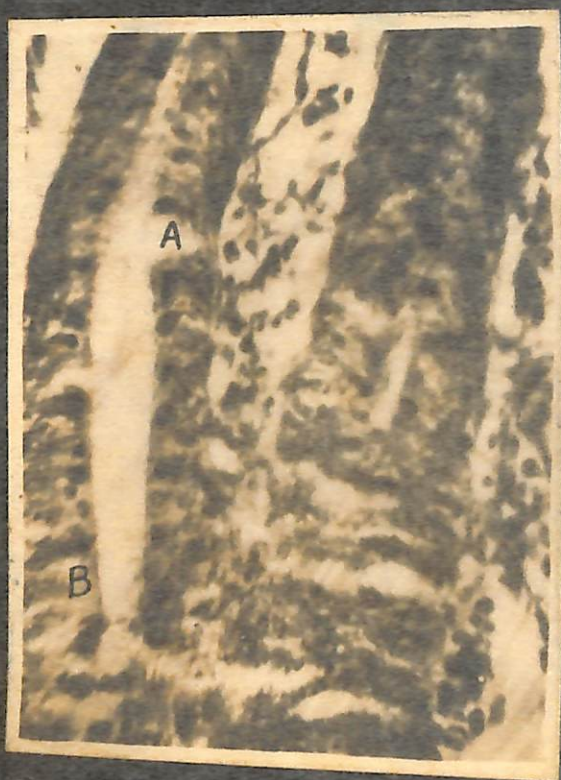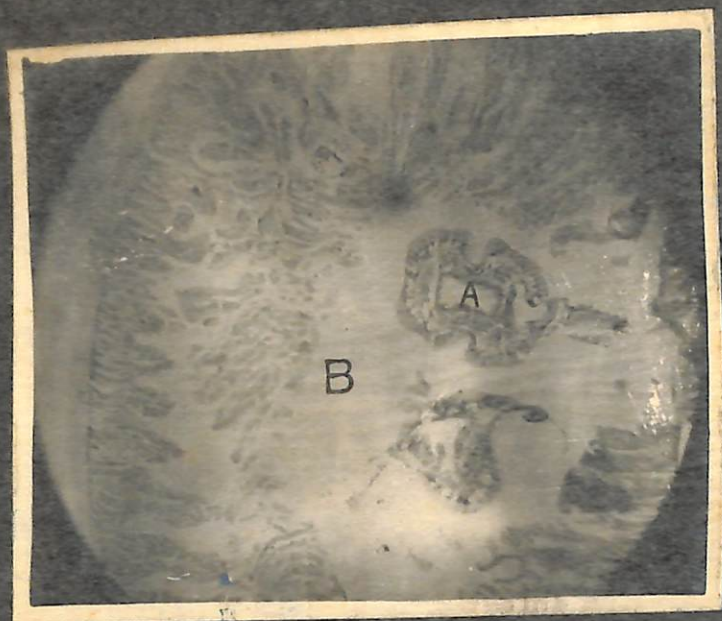Protein: A marked depletion of the protein contents in the goblet cells, columnar epithelial cells along with apical brush border and Lieberkühn glands in immature ascaridiasis is in accordance with findings of Chatterjee and Singh (1968). Contrary to this no marked decrease in protein contents of these layers of intestine of fowls infected with adult A. galli were discernible. Rather, there were slight increase in protein contents in certain layers viz. Lamina propria, muscularis mucosae, submucosa and adventitia.

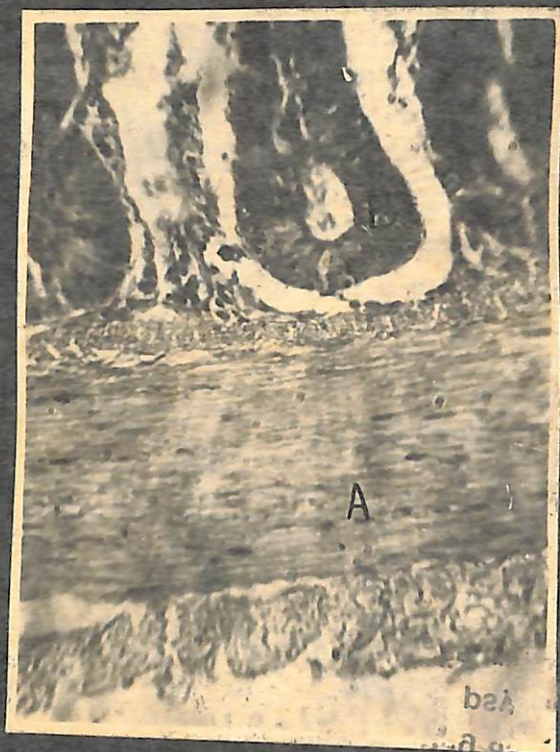
However, the exact process of decreased protein synthesis in immature infection and increased in mature infection like A. galli

is not clear. It is opined that immature worm feeds in body protein voraciously for their body growth which is rather reduced or completely stopped after the worms attain the maturity. This hypothesis could be corroborated by the findings of Todd and Hansen (1951), who reported maximum weight loss of the bird during the time when the immature larvae of A. galli established within the host.

SUMMARY

The histochemical changes in the different tunics of the intestinal wall for polysaccharide complex substances, glycogen, mucin, calcium and protein were studied following A. galli infection of the gut with adult parasites and juveniles. Sections revealed no appreciable changes in polysaccharide substances, but revealed marked depletion in the glycogen contents in the infection with mature parasites. Significant increase in mucin production in mature worm infestation and very weak to moderate increase in immature parasites have been observed. Absence of calcium deposits in both adult and immature infection was noticed. A marked depletion of the protein content in the different tunics of the small intestine of chicken infected with immature worm was noticed, which was not discernible in adult infection.





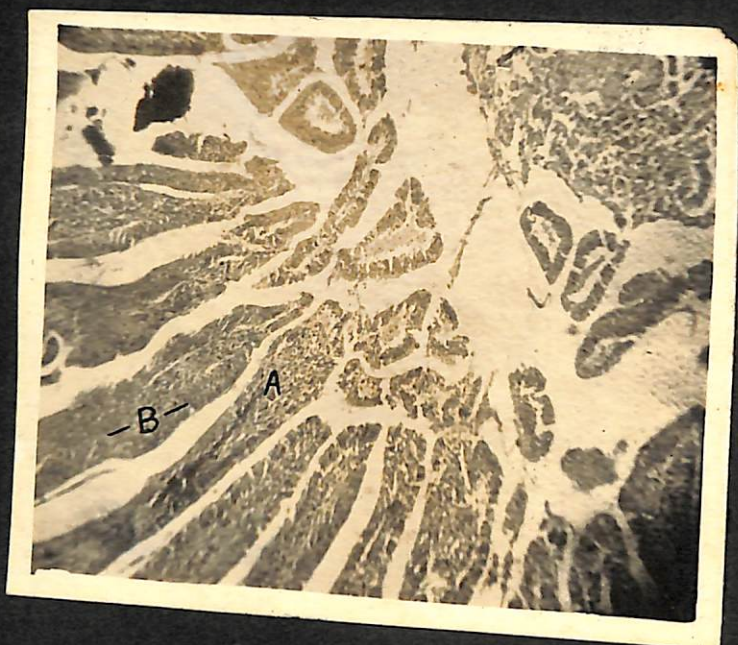
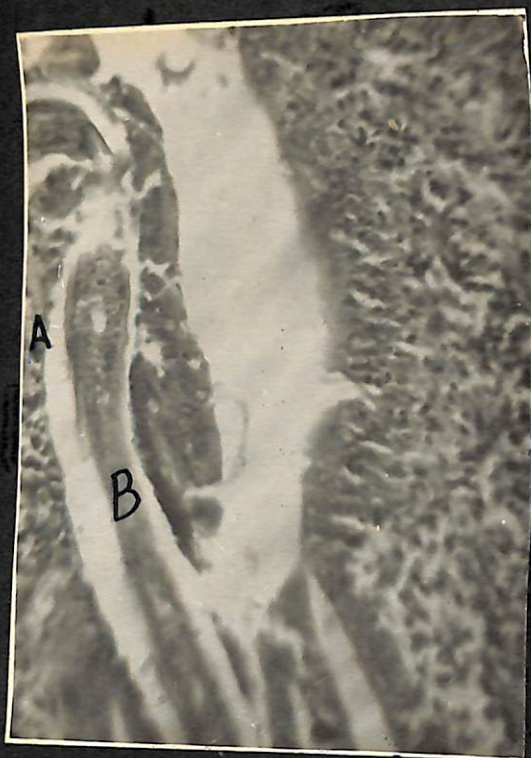
Micrograph of the section of the tissue
showing infection with bacteria (H. pylori)

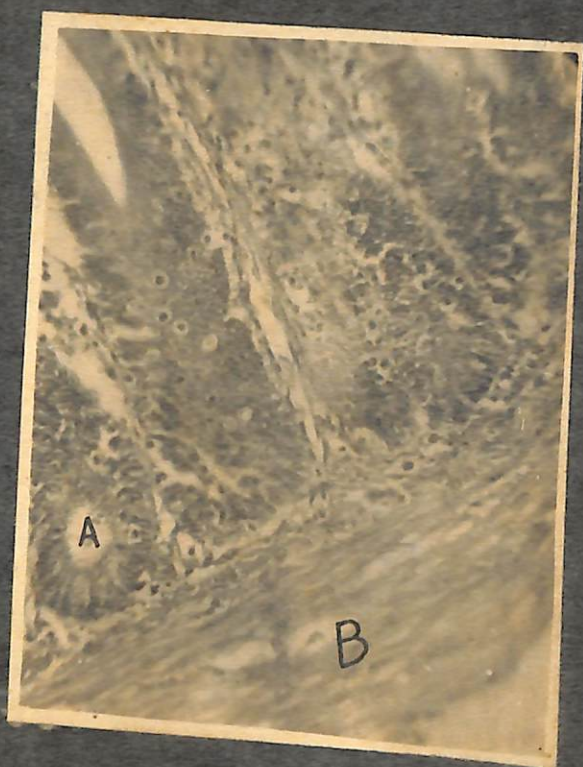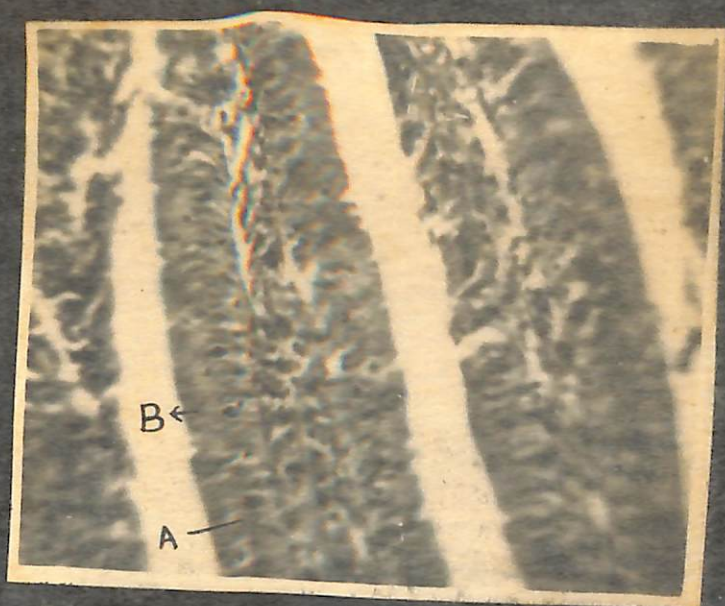
Fig. 2. Section of the tissue showing
infection with bacteria (H. pylori).

Fig. 2 x 200

Fig. 3. Section of the tissue showing
infection with bacteria (H. pylori).

Fig. 3 x 200





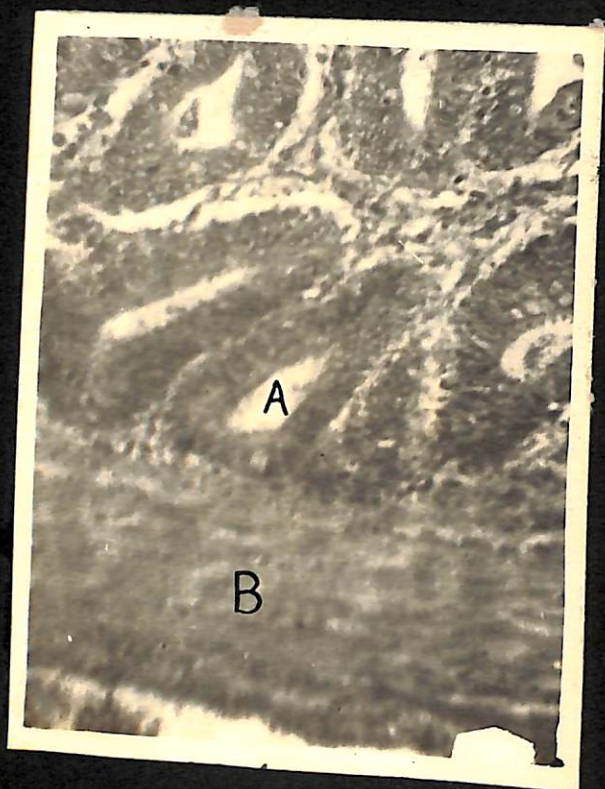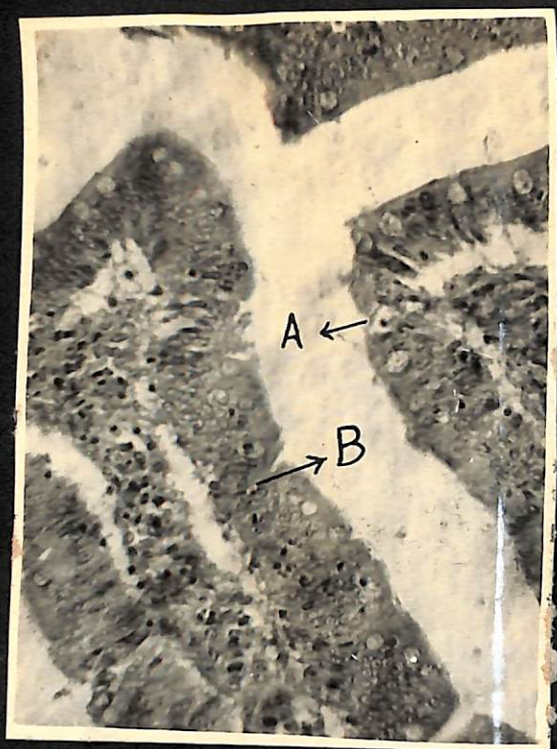1. The first part of the paper is devoted to a general survey of the literature on the subject of the influence of the environment on the development of the individual.

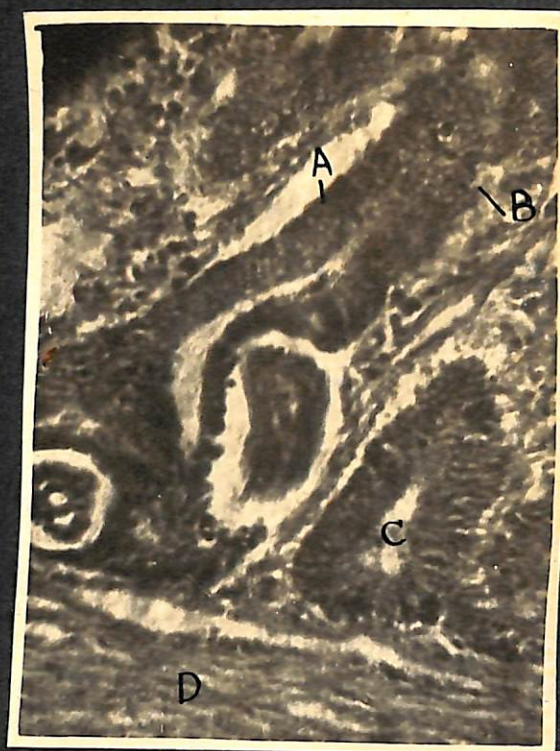
2. The second part of the paper is devoted to a detailed study of the influence of the environment on the development of the individual, with special reference to the influence of the social environment.


3. The third part of the paper is devoted to a study of the influence of the environment on the development of the individual, with special reference to the influence of the physical environment.

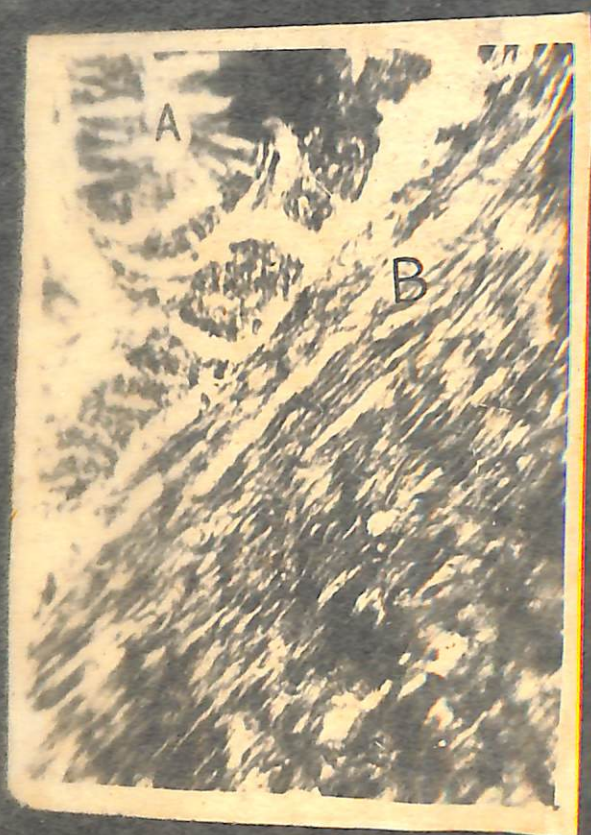4. The fourth part of the paper is devoted to a study of the influence of the environment on the development of the individual, with special reference to the influence of the cultural environment.

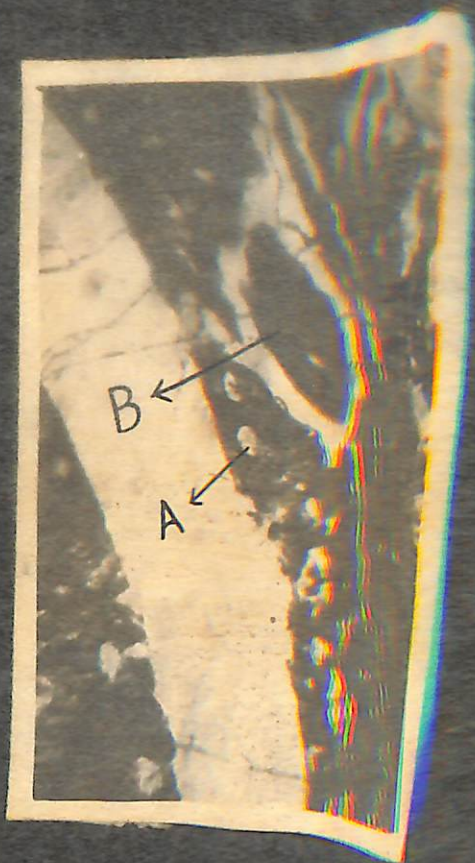5. The fifth part of the paper is devoted to a study of the influence of the environment on the development of the individual, with special reference to the influence of the economic environment.











PART - V

**ANTHELMINTIC EFFICACY OF HELATAC, BANMINTH AND WOP^{ELL}
AGAINST IMMATURE ASCARIDIA GALLI IN FOWLS**