

# **SALMONELLA**

Dr. Pankaj Kumar

**Department of Veterinary Microbiology**

# Salient feature:

- Salmonellae are usually motile
- Do not ferment lactose
- Serotyping is based on the **Kaufmann and White schema** in which somatic (O) and flagellar (H) antigens are identified
- The genus **Salmonella** contains more than 2,500 serotypes
- Occasionally, **capsular (Vi)** antigens may be detected.

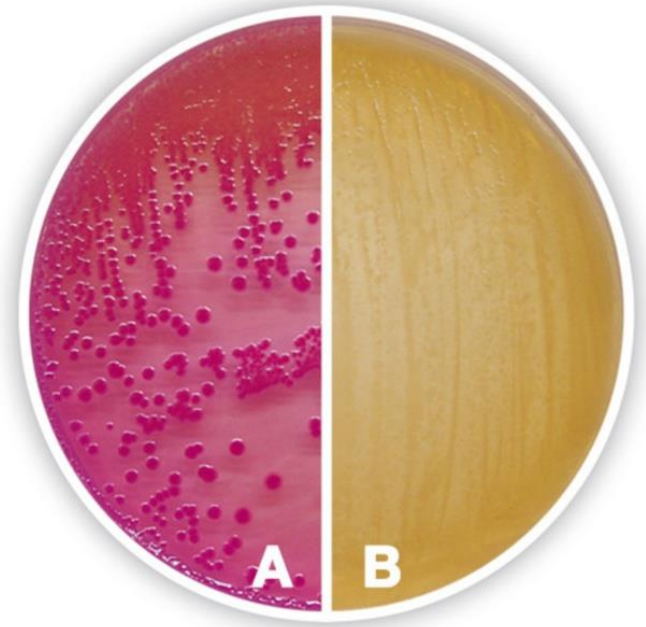
# MacConkey agar:

- A selective, differential medium
  - Peptone
  - Sodium chloride
  - Agar
  - **Bile salts** (*Inhibits other contaminants*)
  - **Lactose** (*Differentiation of LF/NLF*)
  - Neutral red

(*appears Pink in acidic whereas Pale in alkaline*)

# MacConkey agar:

- The colonies of lactose fermenters (LF) are pink  
*(due to acid production from lactose)*
- The colonies of non-lactose fermenters (NLF) have a pale appearance



Xylose-lysine-deoxycholate (XLD) agar

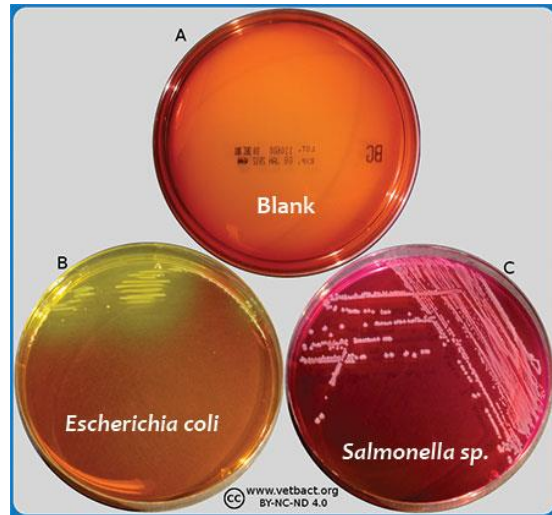
**Salmonella - Red colonies with black centres**

Brilliant Green Agar (BGA)

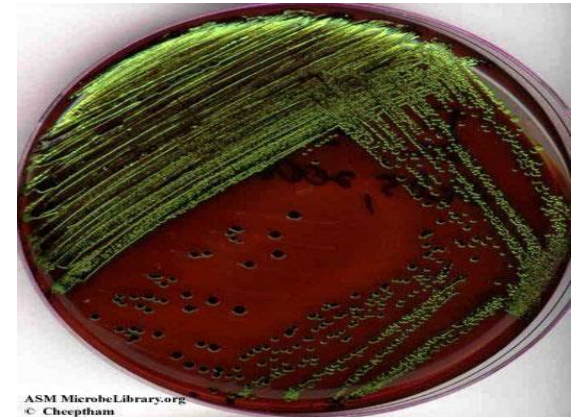
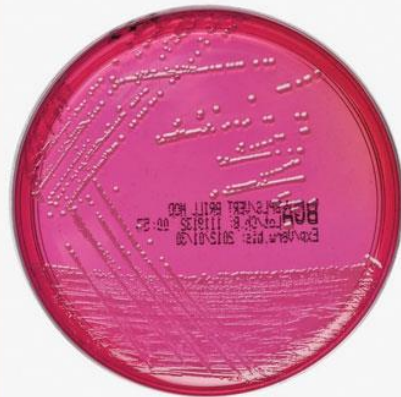Salmonella- Red Colonies

***Eosin-methylene blue (EMB) agar***

Metallic Sheen



**Brilliant Green Agar**



# IMViC

Genus	Indol	Methyl Red	VP	Citrate
E. coli	+	+	-	-
Klebsiella	-	-	+	+
<b>Salmonella</b>	-	+	-	+
Enterobacter	-	-	+	+

# Reactions in triple sugar iron (TSI) :

- Triple sugar iron agar contains **0.1% glucose, 1% lactose and 1% sucrose** and ferrous sulphate-sodium thiosulphate
- Phenol red is used as an indicator for pH change (**red** at pH 8.2, **yellow** at pH 6.4).
- A black precipitate of ferrous sulphide is indicative of  $H_2S$  production.
- The loosely capped tube is incubated for 18 hours at **37°C**.
- **E. coli- Yellow butt/Yellow slant**
- **Salmonella- Yellow butt/ Red slant**
- **Proteus- Yellow butt/ Red slant**



## Enrichment medium:

- Enrichment media are used for increasing the number of salmonella species selectively from heavily contaminated specimen : faeces

**- Selenite F broth**

**- Rappaport broth**

**-Tetrathionate broth**



# Species:

- Two species are proposed, *S. enterica* and *S. bongori*
- *Salmonella enterica* has been divided into six subspecies
- The majority of salmonellae of veterinary importance belong to *S. enterica subspecies enterica*
- The subspecies are further characterised to serotypes to give a final designation such :

*S. enterica subspecies enterica serotype Typhimurium*

# Host adapted species:

- *Salmonella* pullorum - poultry
- *Salmonella* Gallinarum - poultry
- *Salmonella* Choleraesuis - pigs and
- *Salmonella* Dublin – cattle
  
- Paratyphoid -infections of poultry by non-host-adapted salmonellae  
Eg: *Salmonella* Enteritidis ; *Salmonella* Typhimurium.

These infections are often subclinical in laying birds.

# Biotypes:

- *Salmonella* Pullorum and *Salmonella* Gallinarum are non-motile
- Possess similar somatic antigens

	<i>Salmonella</i> Pullorum	<i>Salmonella</i> Gallinarum
Glucose (gas)	+	-
Dulcitol	-	+
Maltose	-	+
Ornithine decarboxylase	+	-
Rhamnose	+	-

## General feature:

- *Salmonella* serotypes occur worldwide
- Infect many mammals, birds and reptiles
- Mainly excreted in faeces
- Ingestion is the main route of infection

## General feature:

- Organisms may be present in:
  - water,
  - soil,
  - animal feeds,
  - raw meat and
  - offal
  - vegetable
- Faecal material is source of environmental contamination
- *Salmonella* Enteritidis infect poultry – organism found in ovaries
- Organisms can be isolated from eggs

# Pathogenesis:

- Attaches through fimbria
- Invade host cells
- Replicate in them
- Resist both digestion by phagocytes
- Destruction by the complement components

## **Clinical Condition:**

- **Enteric salmonellosis**
- **Septicaemic salmonellosis**
- **Salmonellosis in poultry**

# Enteric salmonellosis

- Enterocolitis -can affect most species of farm animals
- Acute condn ch/by:
  - **Fever, depression, anorexia** and
  - **Profuse foul-smelling diarrhoea**  
(often containing blood and mucus)
- Dehydration and weight loss seen
- Pregnant animals may abort



# Enteric salmonellosis

- Recumbency and death noted in Young animals
- Endemic areas- Milder disease is observed
- Acute salmonellosis cases are converted into chronic cases

Chronic cases:

- Intermittent fever
- soft faeces and
- gradual weight loss

# Septicaemic salmonellosis

- The septicaemic form seen in animals of all ages
- Most common in young ones - calves, neonatal foals and in pigs less than four months of age
- Sudden onset with high fever, depression and recumbency
- Surviving animals can develop: - persistent diarrhoea, arthritis, meningitis or pneumonia

# Septicaemic salmonellosis

- In pigs - *Salmonella Choleraesuis* (hog cholera bacilli) infection
- Characteristic bluish discolouration of the ears and snout
- Intercurrent viral infections - predispose to severe forms
- The close clinical and pathological relationships with classical swine fever virus

# Salmonellosis in poultry:

## *Agents:*

- *Salmonella* Pullorum
- *Salmonella* Gallinarum
- Salmonella* Enteritidis

- Can infect the ovaries of hens and be transmitted through eggs
- *Salmonella* Pullorum – **Pullorum disease** –  
(Bacillary White Diarrhoea, BWD)
- *Salmonella* Gallinarum - **Fowl typhoid**
- *Salmonella* Enteritidis –Sub clinical infection-  
-In undercooked egg dishes (human food poisoning)

# Pullorum disease- BWD

- *Salmonella* Pullorum- infects young chicks and turkey
- Poults up to 2 to 3 weeks of age are primarily infected
- The mortality rate is high
- Affected birds Anorexic, Depressed and huddle under a heat source
- Have whitish faecal pasting around their vents
- Characteristic lesions:
  - Whitish nodes throughout the lungs
  - Focal necrosis of liver and spleen

## Salmonellosis in poultry:

- Can affect chicks
- Primarily a septicaemic disease of adult birds
- Often resulting in sudden deaths
- Characteristic findings:
  - Enlarged, friable, bile-stained liver
  - Enlarged spleen

# Diagnosis:

History and clinical sign and symptoms

At PM examination:

- enterocolitis with blood-stained luminal contents
- enlarged mesenteric lymph nodes

Specimens of choice:

- Faeces and blood from live animals
- Intestinal contents and tissues from dead animals
- Abomasal contents from aborted foetuses

# Diagnosis:

- Isolation from blood or parenchymatous organs is confirmatory
- A heavy growth of salmonellae on plates:
  - directly inoculated with faeces,
  - intestinal contents or
  - foetal abomasal contentssuggestive of salmonella infection
- Serological test
- DNA probes



**Thanks**